



PATIENT

Nadia Morgan PHVA

SPECIES

Feline

BREED

DSH

SEX

Female Intact

AGE

18 months

WEIGHT

6.7 lbs

INTERPRETED BY

R. McKenzie Daniel,
DVM, DABVP
(Canine and Feline)

IMAGING PERFORMED BY

Dr. Ryan Leal

HOSPITAL NAME

Wellesley AH

REFERRING VET

Dr. Ryan Leal

INVOICE

12861

DATE

11/25/25

PRESENTING CLINICAL SIGNS

History: Pt presents for pre-anesthetic screening echo. Pt is scheduled for spay with Rescue organization. Rescue DVM auscultated murmur, found an abnormal ProBNP (qualitative), and recommended echo.

Abnormal PE/Chem/CBC/UA Results: PE: 3/6 parasternal systolic murmur noted, BSC 5/9, remainder of PE WNL

LIMITED ULTRASONOGRAPHIC EXAMINATION OF THE HEART

Cardiac Presentation

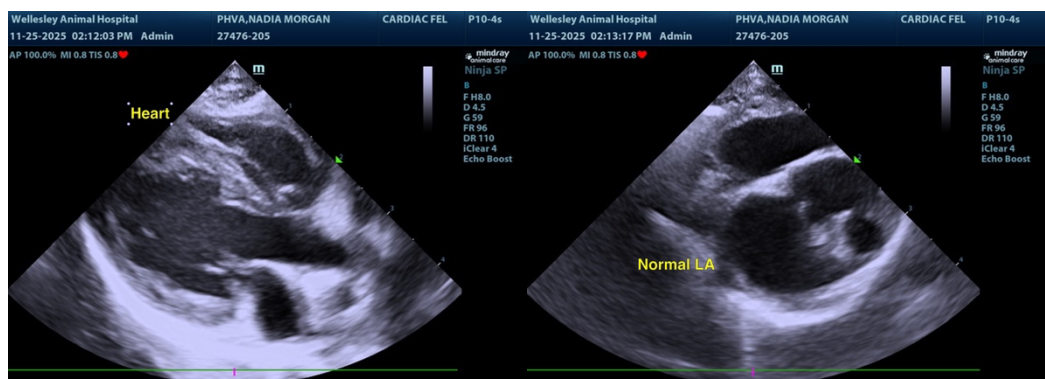
Normal LA size and structure without evidence of volume overload. Normal LV dimension and wall thickness and adequate LV systolic function. Normal right atrium size and dimension. Normal right ventricle and dimension. No evidence of pericardial effusion, pathology or tumors present.

ULTRASONOGRAPHIC FINDINGS

- Subjective normal cardiac structure and function

INTERPRETATION OF THE FINDINGS & FURTHER RECOMMENDATIONS

A definitive cause of the heart murmur was not obvious on brief subjective/pre-anesthetic evaluation. Given lack of left or right heart chamber enlargement. The current hemodynamic effects of the murmur appear low. Full echocardiogram would be ideal for further clarification. Anesthetic risk is considered normal to mild. No gross abnormalities noted on SDEPR Screening Echo to contraindicate anesthesia. Minimal to no left atrial enlargement noted on images presented. However, judicious fluid administration is advised with careful RR/RE monitoring to screen for fluid overload. Monitoring of blood pressure, SpO2, CO2, and auscultation of heart and lungs during anesthesia should be done during every procedure.



The information and recommendations provided are based on the images presented by the referring veterinarian/sonographer. No evaluation can be communicated regarding pathology that was not



PATIENT

Nadia Morgan PHVA

SPECIES

Feline

BREED

DSH

SEX

Female Intact

AGE

18 months

WEIGHT

6.7 lbs

INTERPRETED BY

R. McKenzie Daniel,
DVM, DABVP
(Canine and Feline)

IMAGING PERFORMED BY

Dr. Ryan Leal

HOSPITAL NAME

Wellesley AH

REFERRING VET

Dr. Ryan Leal

INVOICE

12861

DATE

11/25/25

visible in the image/video clips provided.

Thank you for this referral. If the clinical or image interpretation does not parallel your findings or if I can be of any further assistance, please contact me.

R. McKenzie Daniel, DVM, DABVP (Canine / Feline Practice)

info@sonopath.com