



PATIENT

Kaiser Yeager

SPECIES

Canine

BREED

Shepherd X

SEX

MN

AGE

5 years

WEIGHT

32.1 kg

INTERPRETED BY

R. McKenzie Daniel,
DVM, DABVP
(Canine and Feline)

IMAGING PERFORMED BY

Dr. Sarah Barthelemy

HOSPITAL NAME

Signal Hill AC

REFERRING VET

Dr. Cumyn

INVOICE

15573

DATE

11/25/22

PRESENTING CLINICAL SIGNS

Subcutaneous hemangiosarcoma removed 1 year ago. Doing well.

ULTRASONOGRAPHIC EXAMINATION OF THE ABDOMEN

Urinary System

The urinary bladder, trigone, cystourethral junction, and visible pelvic urethra to a depth of 3.0 cm exhibited normal thickness and tone. Anechoic urine was present in the lumen with no uroliths or sediment. The ureteral papillae were normal. The ureters were not visible which is normal. No evidence of inflammatory or neoplastic changes was noted.

The area of the residual prostate was free of pathology.

No evidence of medial Iliac or sublumbar lymphadenopathy/masses.

Normal size and margination were present in the kidneys. A normal 1:3 cortex / medulla ratio and normal corticomedullary definition were maintained. The echogenicity of the cortex was similar to or slightly less than normal liver parenchyma while the medulla echogenicity was hypoechoic to the cortex with no evidence of pelvic dilation. The left kidney measured 6.7 cm in length. The right kidney measured 7.2 cm in length.

Adrenal Glands

No overt pathology was noted in the area of the left or right adrenal glands.

Spleen

The spleen exhibited a finely textured and homogenous parenchyma which was hyperechoic to the liver and renal cortical parenchyma. The capsule was smooth and regular without apparent expansion. The splenic vasculature at the hilus was normal in volume with no evidence of congestion or thrombosis. Acute to chronic inflammatory, neoplastic, or benign parenchyma changes were not noted.

Liver/ Gallbladder

The liver was subjectively normal in size, structure, and contour. The liver parenchyma was uniform and hypoechoic to the spleen with a mild coarse echotexture. The hepatic and portal vasculature were normal in appearance without signs of congestion. The gallbladder was non-distended in size containing moderate, mildly congealed, yet nonorganized gallbladder debris primarily in the caudal lumen and area of the gallbladder neck. The cystic and common bile ducts were normal.

Gastrointestinal

The stomach presented intact wall layering with a normal wall layer ratio. The lumen of the stomach contained mild, nonshadowing ingesta without signs of obstruction or foreign material.

The small intestine presented intact wall layering with 1:3 muscularis/mucosa ratio. The lumen of the small intestine was empty with no signs of ileus, obstruction, or foreign material.

Normal visible colon wall layers were present with apparent formed feces in lumen.



PATIENT

Kaiser Yeager

SPECIES

Canine

BREED

Shepherd X

SEX

MN

AGE

5 years

WEIGHT

32.1 kg

INTERPRETED BY

R. McKenzie Daniel,
DVM, DABVP
(Canine and Feline)

IMAGING PERFORMED BY

Dr. Sarah Barthelemy

HOSPITAL NAME

Signal Hill AC

REFERRING VET

Dr. Cumyn

INVOICE

15573

DATE

11/25/22

Pancreas

The parenchyma of the left limb, body, and right limb of the pancreas presented isoechoic to the adjacent omental fat. A normal curvilinear capsule contour of the pancreas was present. The visible pancreatic duct was normal. No signs of active inflammation or neoplastic disease were evident.

Free Abdomen

No omental masses, lymphadenopathy, or evidence of peritoneal free fluid were noted.

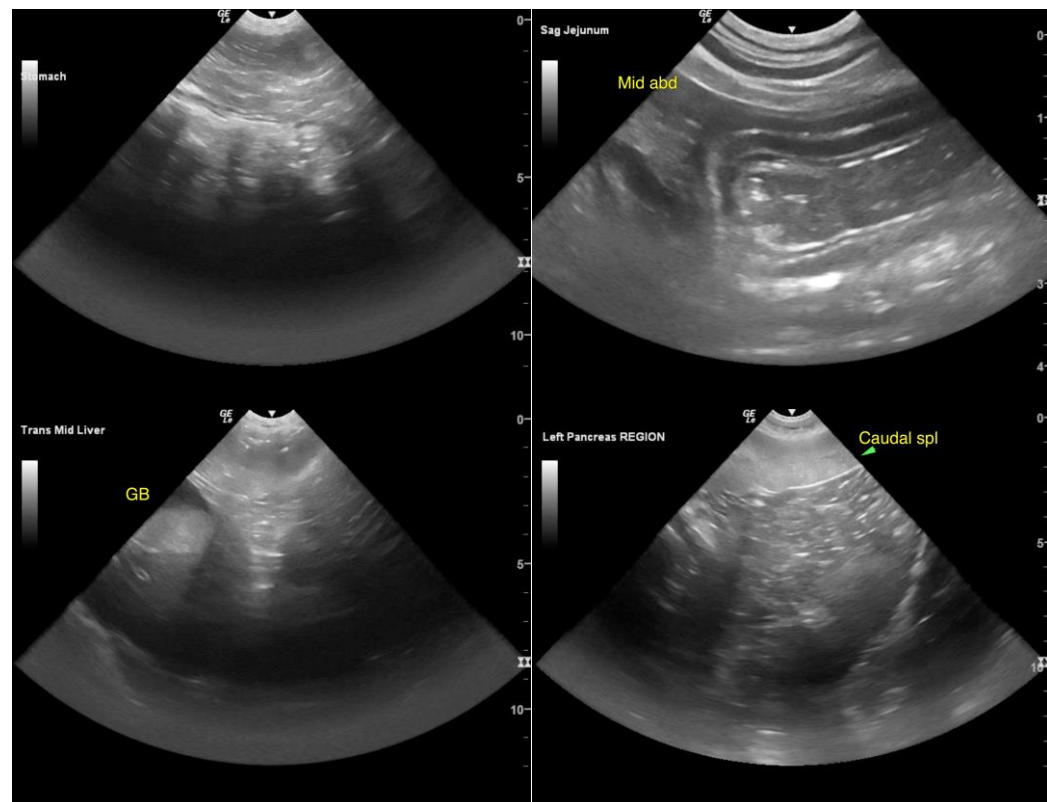
Rapid view of the heart (SDEP 3 position) revealed subjectively normal function without pathology in the right auricle or pericardium.

ULTRASONOGRAPHIC FINDINGS

- Sonographically unremarkable abdomen
- Overtly normal cardiac structure and function

INTERPRETATION OF THE FINDINGS & FURTHER RECOMMENDATIONS

No evidence of abdominal visceral or structural / functional cardiomyopathy. No evidence of intraabdominal or cardiac metastasis secondary to previous subcutaneous hemangiosarcoma. Continued abdominal and cardiac sonographic monitoring, ideally based on oncology recommendations, is suggested.





PATIENT

Kaiser Yeager

SPECIES

Canine

BREED

Shepherd X

SEX

MN

AGE

5 years

WEIGHT

32.1 kg

INTERPRETED BY

R. McKenzie Daniel,
DVM, DABVP
(Canine and Feline)

IMAGING PERFORMED BY

Dr. Sarah Barthelemy

HOSPITAL NAME

Signal Hill AC

REFERRING VET

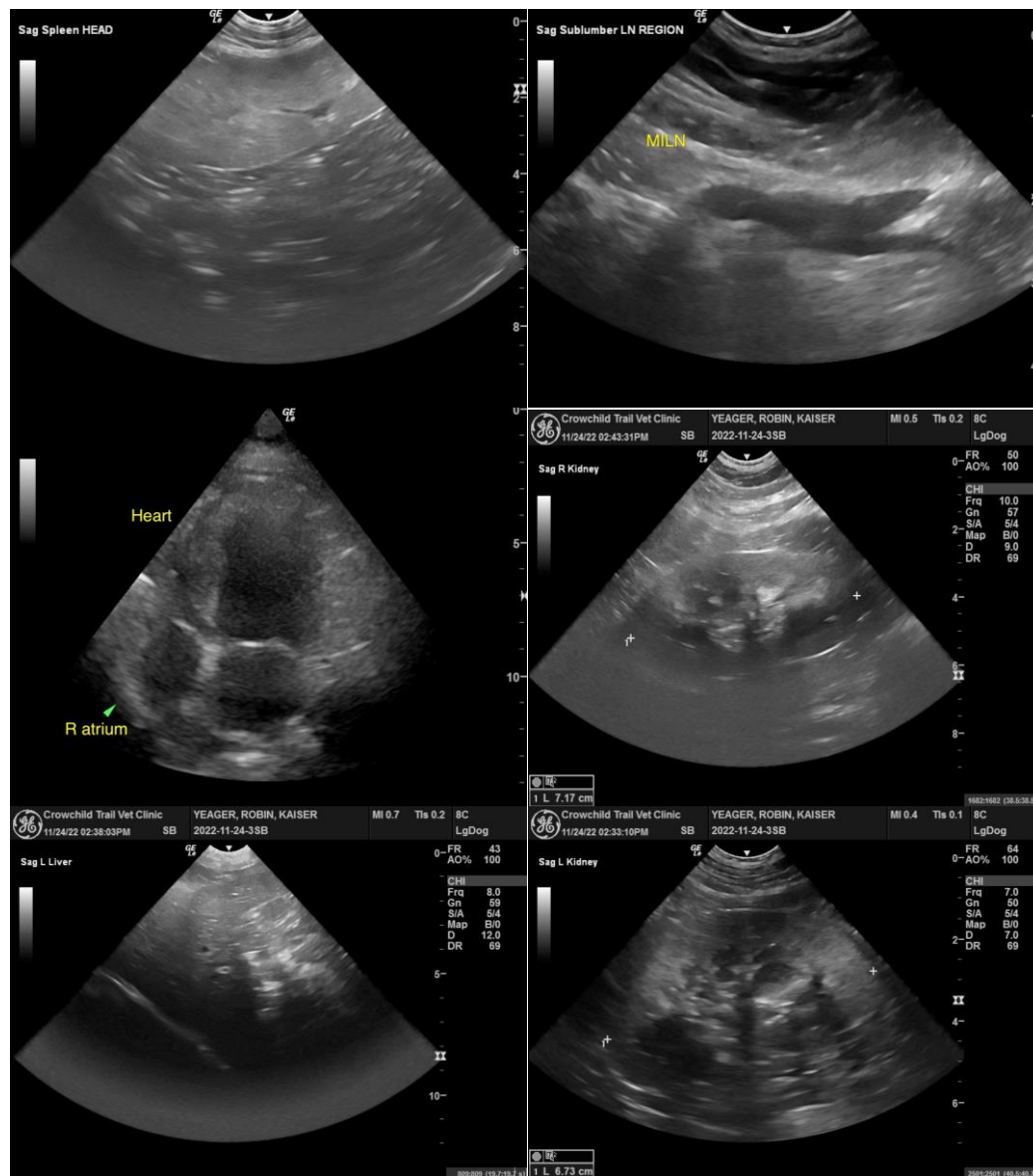
Dr. Cumyn

INVOICE

15573

DATE

11/25/22



The information and recommendations provided are based on the images presented by the referring veterinarian/sonographer. No evaluation can be communicated regarding pathology that was not visible in the image/video clips provided.

Thank you for this referral. If the clinical or image interpretation does not parallel your findings or if I can be of any further assistance please contact me.

R. McKenzie Daniel, DVM, DABVP (Canine / Feline Practice)
info@SonoPath.com