



PATIENT

Emma Crawford

SPECIES

Canine

BREED

Yorkie X

SEX

Female

AGE

10 Years

WEIGHT

1.9 kg

INTERPRETED BY

R. McKenzie Daniel,
DVM, DABVP

IMAGING PERFORMED BY

Dave Stasiuk RDMS,
RDCS, RTR

HOSPITAL NAME

Petzoic Veterinary
Hospital

REFERRING VET

Petzoic Veterinary
Hospital

INVOICE

12477

DATE

11/24/25

PRESENTING CLINICAL SIGNS

Emma presented for recheck exam after 1 week of medical management for pyometra. History or grade 4 heart murmur. Severe dental dz, osteoarthritis. Vitals wnl, no active discharge from vulva, BW: ongoing regenerative anemia 0.26. Pre GA exam. WBC at 56.9. GGT 21, Neutrophils 39.24

ULTRASONOGRAPHIC EXAMINATION OF THE HEART & ABDOMEN

CANINE CARDIAC PARAMETERS	MR VMAX (m/s)	TR VMAX (m/s)	LA/AO (M-Mode)	LA/AO (Heart Base; Swe)	FS (%)	EF (%)	EPSS (cm)
NORMAL PARAMETER	4.5-5.5	<2.7	1.3	Up to 1.6	28-40	40-100	<0.6
PATIENT	6.0	--	NM	1.66	54	88	0.2
CANINE CARDIAC PARAMETERS	HR (BPM)	AV VMAX (m/s)	PV MAX (m/s)	BODY WEIGHT (kg)	LAD LA MAX 4 Chamber	LVIDd Avg; 2D and m-mode short axis (cm)	LVIDs Avg; 2D and m-mode short axis (cm)
NORMAL PARAMETER	50-100	0.7-1.7	0.7-1.6				
PATIENT	NM	1.2	1.0	--	2.0	2.1	--

Cardiac Presentation

The echocardiogram in this patient demonstrated mild increased **left atrial** dimension based on 2 different LA measurement methods. The cranial and caudal **mitral** valve leaflets presented thickening consistent with endocardiosis (anterior greater than posterior) with anterior leaflet prolapse. No evidence of cordate tendon rupture. Doppler indicated measurable severe eccentric insufficiency. The **left ventricle** presented mild increased dimension. The **myocardium** presented normal echogenicity without subjective evidence of significant fibrotic or ischemic disease. **Contractility** of the ventricular walls was adequate and in normal range for this patient evidenced by the fractional shortening measurement and subjective evaluation of the different regions of the myocardium. The **left ventricular outflow** tract demonstrated normal laminar flow and subjective structural integrity. The **right atrium** and auricle revealed normal size, structure and content. No evidence of masses was noted or chamber overload. **Tricuspid** valvular assessment demonstrated adequate linear morphology. The **right ventricle** was of normal size (1/3 diameter of LV), chordae structure, myocardial echogenicity and thickness. **Pulmonic** tract assessment revealed normal valve structure, laminar flow, and diameter (approx.1:1 pa/ao ratio). No visible **pericardial** or free pleura fluid was noted. No echographically detectable evidence of cardiac / pericardial tumors was visible.

Urinary System

The urinary bladder, trigone, cystourethral junction, and visible pelvic urethra to a depth of 2.0 cm exhibited normal thickness and tone. Anechoic urine was present in the lumen with no uroliths or



PATIENT

Emma Crawford

SPECIES

Canine

BREED

Yorkie X

SEX

Female

AGE

10 Years

WEIGHT

1.9 kg

INTERPRETED BY

R. McKenzie Daniel,
DVM, DABVP

IMAGING PERFORMED BY

Dave Stasiuk RDMS,
RDCS, RTR

HOSPITAL NAME

Petzoic Veterinary
Hospital

REFERRING VET

Petzoic Veterinary
Hospital

INVOICE

12477

DATE

11/24/25

sediment. The ureteral papillae were normal. The ureters were not visible which is normal. No evidence of inflammatory or neoplastic change were noted.

Generalized prominent to mildly enlarged uterus exhibiting subjective thickened uterine wall with intermittent to indistinct suspect anechoic cyst imbedded within the uterine wall. Example of uterine horn measured 1.2 cm in diameter. No evidence of current uterine lumen fluid. The left and right ovaries exhibited subjective mild cystic changes.

The area of the aortic trifurcation was free of pathology.

Normal size and margination was present in the kidneys. A normal 1:3 cortex / medulla ratio was maintained. The medulla and cortices were uniform in texture with some increased echogenicity and mild loss of corticomedullary symmetry and definition expected for the age of the patient. Mild medullary mineral was present bilaterally. The left kidney measured 3.3 cm in length. The right kidney measured 3.5 cm in length.

Adrenal Glands

The bilateral adrenal glands were normal in size. Mild parenchyma heterogeneity and mild capsule asymmetry was present without suspicion for overt neoplasia. The left adrenal gland measured 0.37 cm width in the caudal pole. The right adrenal gland measured 0.30 cm width in the caudal pole.

Spleen

The spleen exhibited a finely textured and homogenous parenchyma which was hyperechoic to the liver and renal cortical parenchyma. The capsule was smooth and regular without apparent expansion. The splenic vasculature at the hilus was normal in volume with no evidence of congestion or thrombosis. Acute to chronic inflammatory, neoplastic, or benign parenchyma changes were not noted.

Liver

The liver was subjectively normal in size, structure, and contour. The liver parenchyma was uniform and hypoechoic to the spleen with a mild coarse echotexture. The hepatic and portal vasculature were normal in appearance without signs of congestion.

The gallbladder was non distended in size with mild nonorganized biliary sludge. The cystic duct and common bile ducts were normal without evidence of dilation.

Gastrointestinal

The stomach presented intact wall layering with a normal wall layer ratio. The lumen of the stomach contained echogenic, mild nonshadowing ingesta (consistent with food echogenicity) without signs of obstruction or foreign material.

The small intestine presented intact wall layering with 1:3 muscularis/mucosa ratio. The lumen of the small intestine was empty with no signs of ileus, obstruction or foreign material.

Normal visible colon wall layers were present with apparent formed feces in lumen.

Pancreas



PATIENT

Emma Crawford

The parenchyma of the left limb, body and right limb of the pancreas presented isoechoic to the adjacent omental fat. A normal curvilinear capsule contour of the pancreas was present. The visible pancreatic duct was normal. No signs of active inflammation or neoplastic disease was evident.

SPECIES

Canine

Free Abdomen

No overt lymphadenopathy or peritoneal effusion was present.

BREED

Yorkie X

ULTRASONOGRAPHIC FINDINGS

SEX

Female

- Chronic mitral valve disease with mitral valve prolapse (ACVIM mild B2).
- Mild increased measured MR velocity.
- Mildly thickened nonfluid dilated uterus with subjective intermittent mural cysts- suggestive of cystic endometrial hyperplasia.
- Minor cystic ovaries- subjective benign.
- Age-related renal changes.

AGE

10 Years

INTERPRETATION OF THE FINDINGS & FURTHER RECOMMENDATIONS

WEIGHT

1.9 kg

The cause of the murmur is chronic degenerative valvular changes with secondary eccentric mitral valve insufficiency. The left atrial enlargement implies that the risk of complication secondary to mitral valve insufficiency is elevated, yet overall the heart appears stable. No other clinical issues such as LV systolic dysfunction or clinical pulmonary hypertension. Pimobendan 0.3 mg/kg BID is recommended. No overt indication for additional medication. Prognosis is considered variable and sonographic monitoring is recommended. Recheck echo cardiogram is suggested in 6 months, sooner if clinical signs arise. Assessment of systemic BP for evidence of hypertension given mild elevated measured MR velocity is recommended. Cardiac anesthetic risk is mild yet likely mildly reduced once on Pimobendan for 3-5 days prior to anesthesia. If anesthesia is elected, the following protocol is recommended with appropriate to judicious IV fluid use. Suggested anesthetic protocol may include opioid or Benzodiazepine pre-med, induction with Propofol or Alfaxalone, and appropriate gas anesthesia with avoidance of alpha 2 agonists.

INTERPRETED BY

R. McKenzie Daniel, DVM, DABVP

No current evidence of pyometra or overt ovario-uterine neoplastic criteria. Continued monitoring for recurrent pyometra signs versus ovariohysterectomy is recommended. Hepatosupportive medications are indicated if evidence of cholestasis.

IMAGING PERFORMED BY

Dave Stasiuk RDMS, RDCS, RTR

HOSPITAL NAME

Petzoic Veterinary Hospital

REFERRING VET

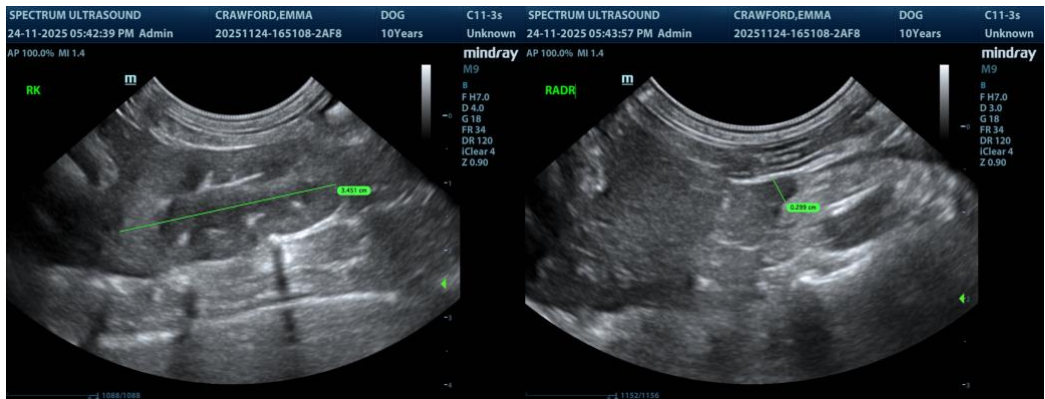
Petzoic Veterinary Hospital

INVOICE

12477

DATE

11/24/25





PATIENT

Emma Crawford

SPECIES

Canine

BREED

Yorkie X

SEX

Female

AGE

10 Years

WEIGHT

1.9 kg

INTERPRETED BY

R. McKenzie Daniel,
DVM, DABVP

IMAGING PERFORMED BY

Dave Stasiuk RDMS,
RDCS, RTR

HOSPITAL NAME

Petzoic Veterinary
Hospital

REFERRING VET

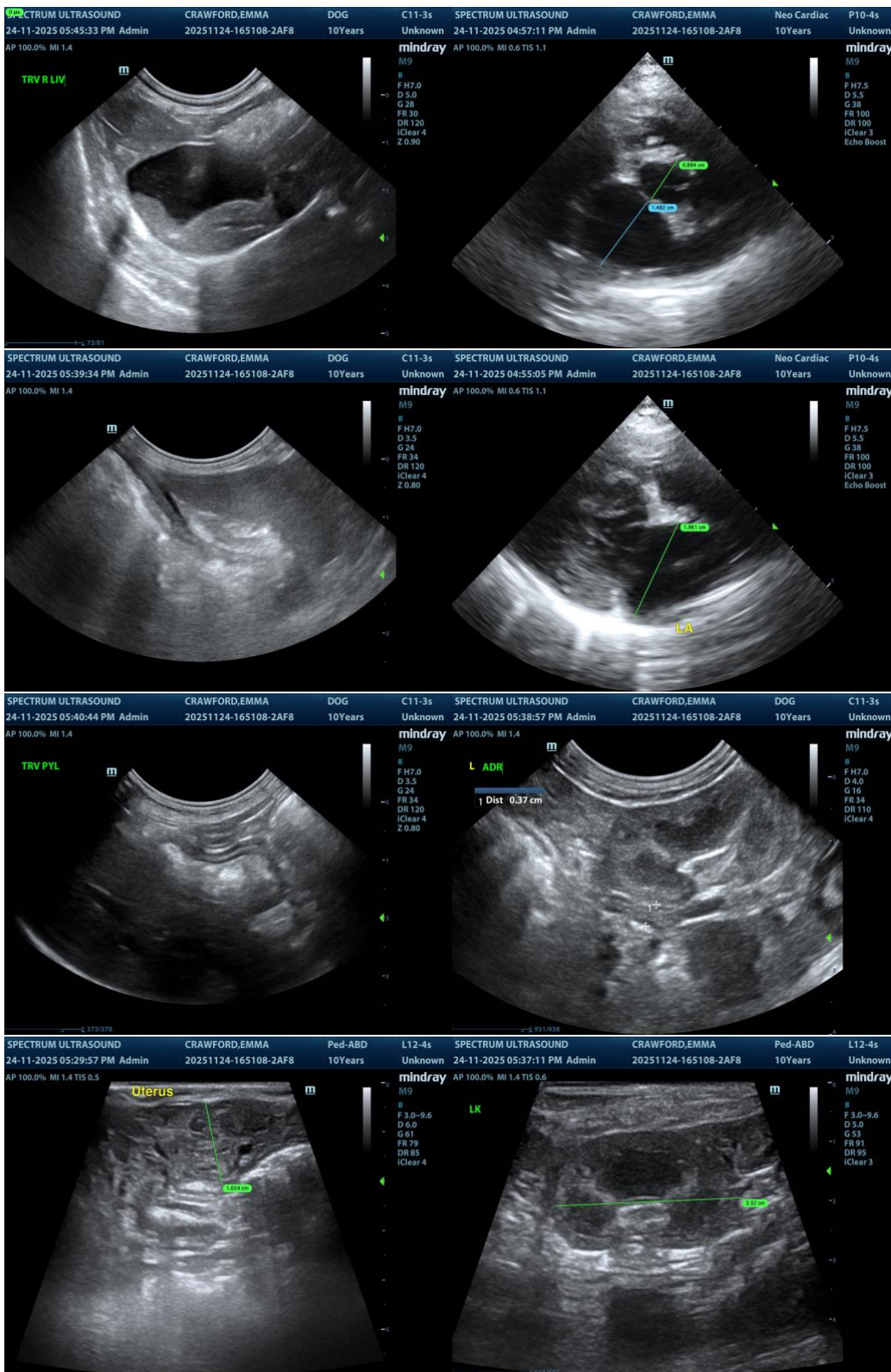
Petzoic Veterinary
Hospital

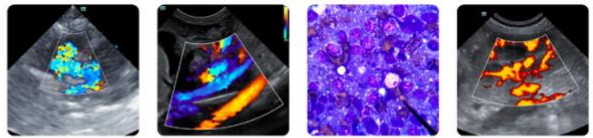
INVOICE

12477

DATE

11/24/25





PATIENT

Emma Crawford

SPECIES

Canine

BREED

Yorkie X

SEX

Female

AGE

10 Years

WEIGHT

1.9 kg

INTERPRETED BY

R. McKenzie Daniel,
DVM, DABVP

IMAGING PERFORMED BY

Dave Stasiuk RDMS,
RDCS, RTR

HOSPITAL NAME

Petzoic Veterinary
Hospital

REFERRING VET

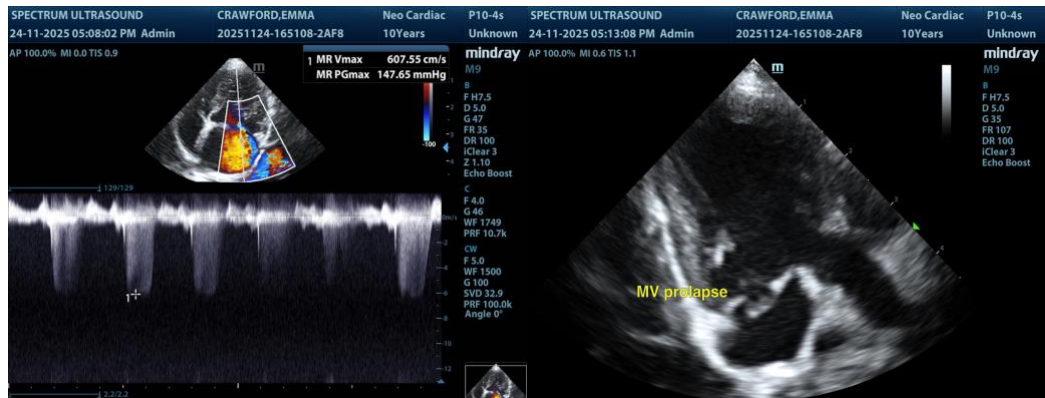
Petzoic Veterinary
Hospital

INVOICE

12477

DATE

11/24/25



The information and recommendations provided are based on the images presented by the referring veterinarian/sonographer. No evaluation can be communicated regarding pathology that was not visible in the image/video clips provided.

Thank you for this referral. If the clinical or image interpretation does not parallel your findings or if I can be of any further assistance, please contact me.

R. McKenzie Daniel, DVM, DABVP (Canine / Feline Practice)

info@SonoPath.com