



**PATIENT PRESENTING CLINICAL SIGNS**

Lexie Putthoff Recheck ultrasound of bladder mass from 7/7/21.

**SPECIES LIMITED ULTRASONOGRAPHIC EXAMINATION**

Canine

The urinary bladder was overall non-distended in size. Previously noted non-homogeneous to mineralized mass occupying the area of the trigone, cystourethral junction and proximal urethra was present. The mass appeared to be mildly increased in size compared to the previous ultrasound, now measuring approximately 2.2 cm in diameter. However, the overall mass size was difficult to evaluate owing to the presence of mineralization and associated distal acoustic shadowing. No overt evidence of regional metastasis.

BREED

Yorkie

SEX

Spayed Female

Normal size and margination were present in the kidneys. A normal 1:3 cortex / medulla ratio was maintained. The medulla and cortices were uniform in texture with some increased echogenicity and loss of corticomedullary symmetry and definition expected for the age of the patient. No evidence of pelvic dilation was present. The left kidney measured 3.7 cm. The right kidney measured 4.0 cm. No evidence of hydronephrosis in either kidney.

AGE

13 Years

**ULTRASONOGRAPHIC FINDINGS**

- Mildly progressive urinary bladder and proximal urethral mass
- Non-distended urinary bladder
- Static chronic renal changes, no evidence of pyelectasia or hydronephrosis

WEIGHT

8 Pounds

**INTERPRETATION OF THE FINDINGS & FURTHER RECOMMENDATIONS**

The previously noted urinary bladder mass appears to be mildly progressive, yet not overtly obstructive to urine outflow given the normal urinary bladder size. Additionally, no evidence of ureteral obstruction was present. Continued sonographic monitoring as well as monitoring for evidence of stranguria and empirical therapy for transitional cell carcinoma is recommended.

**INTERPRETED BY**

R. McKenzie Daniel, DVM, DABVP (Canine and Feline)

**IMAGING PERFORMED BY**

Rachel Runnels, RVT

**HOSPITAL NAME**

SVS Imaging Kansas City

**REFERRING VET**

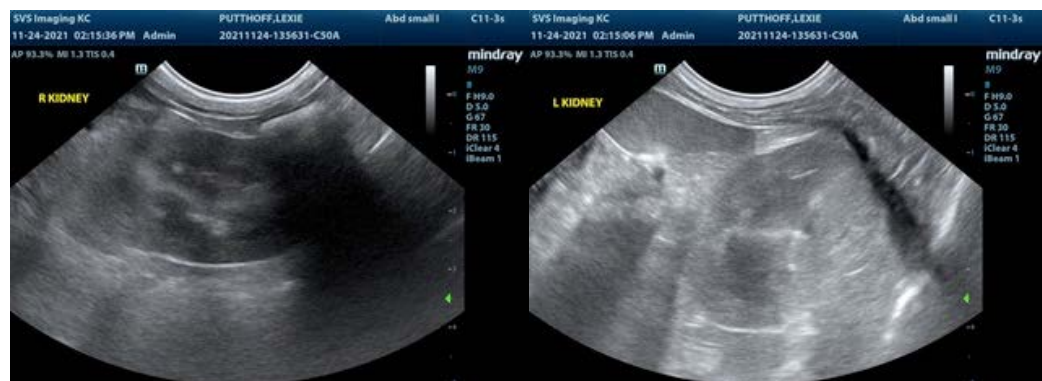
Dr. Jennifer Simon

**INVOICE**

30057

**DATE**

11/24/21





**PATIENT**

Lexie Putthoff

**SPECIES**

Canine

**BREED**

Yorkie

**SEX**

Spayed Female

**AGE**

13 Years

**WEIGHT**

8 Pounds

**INTERPRETED BY**

R. McKenzie Daniel,  
DVM, DABVP  
(Canine and Feline)

**IMAGING PERFORMED BY**

Rachel Runnels, RVT

**HOSPITAL NAME**

SVS Imaging Kansas  
City

**REFERRING VET**

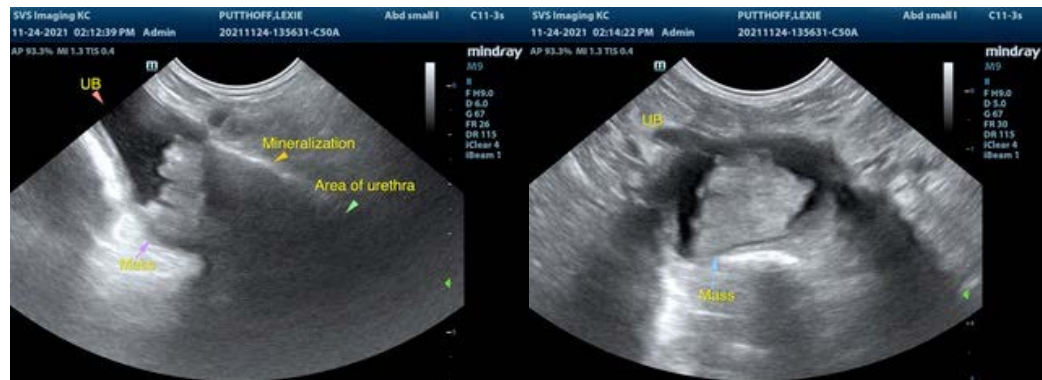Dr. Jennifer Simon

**INVOICE**

30057

**DATE**

11/24/21



The information and recommendations provided are based on the images presented by the referring veterinarian. No evaluation can be communicated regarding pathology that was not visible in the image/video clips provided.

Thank you for this referral. If the clinical or image interpretation does not parallel your findings or if I can be of any further assistance please contact me.

R. McKenzie Daniel, DVM, DABVP (Canine / Feline Practice)  
info@SonoPath.com