


PATIENT

Sig Bruner

SPECIES

Canine

BREED

Heeler

SEX

MN

AGE

13yr

WEIGHT

44

INTERPRETED BY

 R. McKenzie Daniel,
 DVM, DABVP
 (Canine and Feline)

IMAGING PERFORMED BY

Nicole Gotfredson

HOSPITAL NAME

 Buffalo Veterinary
 Clinic

REFERRING VET

Dr, Garry Gotfredson

INVOICE

12236ag

DATE

11/22/2022

PRESENTING CLINICAL SIGNS

Came in on 11/1/22 for a dental. Did not proceed due to ECG reading. Blood work WBC low at 4.88. EKG showed ventricular arrhythmia could be cardiac or non cardiac. Recommend U/S, did quick ultrasound and left kidney is abnormal looking, possible mass. Schedule for full abdominal and chest ultrasound with Nicole to send off. Has lost another 4 pounds since July but eats good. Today owner reports no coughing, continued weight loss, hard time getting around. Currently on no medications.

Abnormal PE/Chem/CBC/UA Results:

ULTRASONOGRAPHIC EXAMINATION OF THE ABDOMEN AND HEART

| CANINE CARDIAC PARAMETERS | MR VMAX (m/s) | TR VMAX (m/s) | LA/AO (Boon method) | LA/AO (Heart Base; Swe) | FS (%) | EF (%) | EPSS (cm) |
|---------------------------|---------------|---------------|---------------------|-------------------------|---------------------------------|--|--|
| NORMAL PARAMETER | 4.5-5.5 | <2.7 | 1.3 | <1.3 | 28-40 | 40-100 | <0.6 |
| PATIENT | | | | 1.4 | 45.5 | 80 | 0.2 |
| CANINE CARDIAC PARAMETERS | HR (BPM) | AV VMAX (m/s) | PV MAX (m/s) | BODY WEIGHT (kg) | LA 2D short axis Base view (cm) | LVIDd Avg; 2D and m-mode short axis (cm) | LVIDs Avg; 2D and m-mode short axis (cm) |
| NORMAL PARAMETER | 50-100 | 0.7-1.7 | 0.7-1.6 | | | | |
| PATIENT | NM | NM | NM | | 3.8 | 3.3 | |

Cardiac Presentation

The echocardiogram in this patient demonstrated normal left atrial size based on 3 separate methods of LA evaluation. The cranial and caudal mitral valve leaflets presented normal linear structure, extension in systole, and union in diastole with normal kinesis. The left ventricle presented thicknesses with linear contour and was not dilated nor restricted. The myocardium presented normal echogenicity without subjective evidence of significant fibrotic or ischemic disease. Contractility of the ventricular walls was adequate and in normal range for this patient evidenced by the fractional shortening measurement and subjective evaluation of the different regions of the myocardium. The left ventricular outflow tract demonstrated normal laminar flow and subjective structural integrity. The right atrium and auricle revealed normal size, structure and content. No evidence of masses was noted. Tricuspid valvular assessment demonstrated adequate linear morphology and kinesis. The right ventricle was of normal size (1/3 diameter of LV), chordae structure, myocardial echogenicity and thickness. Pulmonary outflow tract assessment revealed normal valve structure, laminar flow, and diameter (approx.1:1 pa/ao ratio). No visible pericardial or free pleura fluid was noted. The cranial mediastinum and pericardial and extra-cardiac regions were free of masses in the visible window.

No overt arrhythmia was present.

Urinary System

The urinary bladder, trigone, cystourethral junction, and visible pelvic urethra exhibited normal thickness and tone. Anechoic urine was present in the lumen with no uroliths or sediment. The ureteral



| | |
|--|---|
| PATIENT | papillae were normal. The ureters were not visible which is normal. No evidence of inflammatory or neoplastic changes were noted. |
| Sig Bruner | |
| SPECIES | Normal size and margination were present in the kidneys. A normal 1:3 cortex / medulla ratio was maintained. The medulla and cortices were uniform in texture with some increased echogenicity and mild to moderate loss of corticomedullary symmetry and definition expected for the age of the patient. No evidence of pelvic dilation was present. The left kidney measured 5.6 cm in length. The right kidney measured 5.2 cm in length |
| Canine | |
| BREED | The area of the aortic trifurcation was free of pathology. |
| Heeler | |
| | The area of the residual prostate appeared normal and free of pathology. |
| | The area of the iliac trifurcation was free of pathology including no evidence of medial, iliac or sublumbar lymphadenopathy. |
| SEX | |
| MN | |
| AGE | Adrenal Glands |
| 13yr | The left adrenal gland was uniform in size and contour with a uniformly hypoechoic parenchyma. The left adrenal gland measured 0.61 cm width at the caudal pole and 0.6 cm width at the cranial pole. The right adrenal gland was not definitively visualized. |
| | Spleen |
| WEIGHT | The spleen exhibited a finely textured and homogenous parenchyma which was hyperechoic to the liver and renal cortical parenchyma. The capsule was smooth and regular without apparent expansion. The splenic vasculature at the hilus was normal in volume with no evidence of congestion or thrombosis. Acute to chronic inflammatory, neoplastic, or benign parenchyma changes were not noted. |
| 44 | |
| INTERPRETED BY | Liver |
| R. McKenzie Daniel, DVM, DABVP (Canine and Feline) | The liver presented enlarged in size. The parenchyma of the liver exhibited mild parenchymal remodeling. The capsule of the liver was symmetrically rounded to mildly swollen in margination. The hepatic and portal vasculature were normal in appearance without signs of congestion. |
| IMAGING PERFORMED BY | The gallbladder was non-distended in size with primarily anechoic luminal content. The cystic and common bile ducts were normal. |
| Nicole Gotfredson | |
| HOSPITAL NAME | Gastrointestinal |
| Buffalo Veterinary Clinic | The stomach presented intact wall layering with a normal wall layer ratio. The lumen of the stomach was empty with no signs of ileus, obstruction or foreign material. |
| REFERRING VET | The small intestine presented intact wall layering with 1:3 muscularis/mucosa ratio. The lumen of the small intestine was empty with no signs of ileus, obstruction or foreign material. |
| Dr, Garry Gotfredson | Normal visible colon wall layers were present with apparent formed feces in lumen. |
| | Pancreas |
| INVOICE | The parenchyma of the left limb, body and right limb of the pancreas presented isoechoic to the adjacent omental fat. A normal curvilinear capsule contour of the pancreas was present. The visible pancreatic duct was normal. No signs of active inflammation or neoplastic disease was evident. |
| 12236ag | |
| DATE | Free Abdomen |
| 11/22/2022 | No omental masses, overt lymphadenopathy or peritoneal effusion was present. |



PATIENT

Sig Bruner

SPECIES

Canine

BREED

Heeler

SEX

MN

AGE

13yr

WEIGHT

44

INTERPRETED BY

R. McKenzie Daniel,
DVM, DABVP
(Canine and Feline)

IMAGING PERFORMED BY

Nicole Gotfredson

HOSPITAL NAME

Buffalo Veterinary
Clinic

REFERRING VET

Dr, Garry Gotfredson

INVOICE

12236ag

DATE

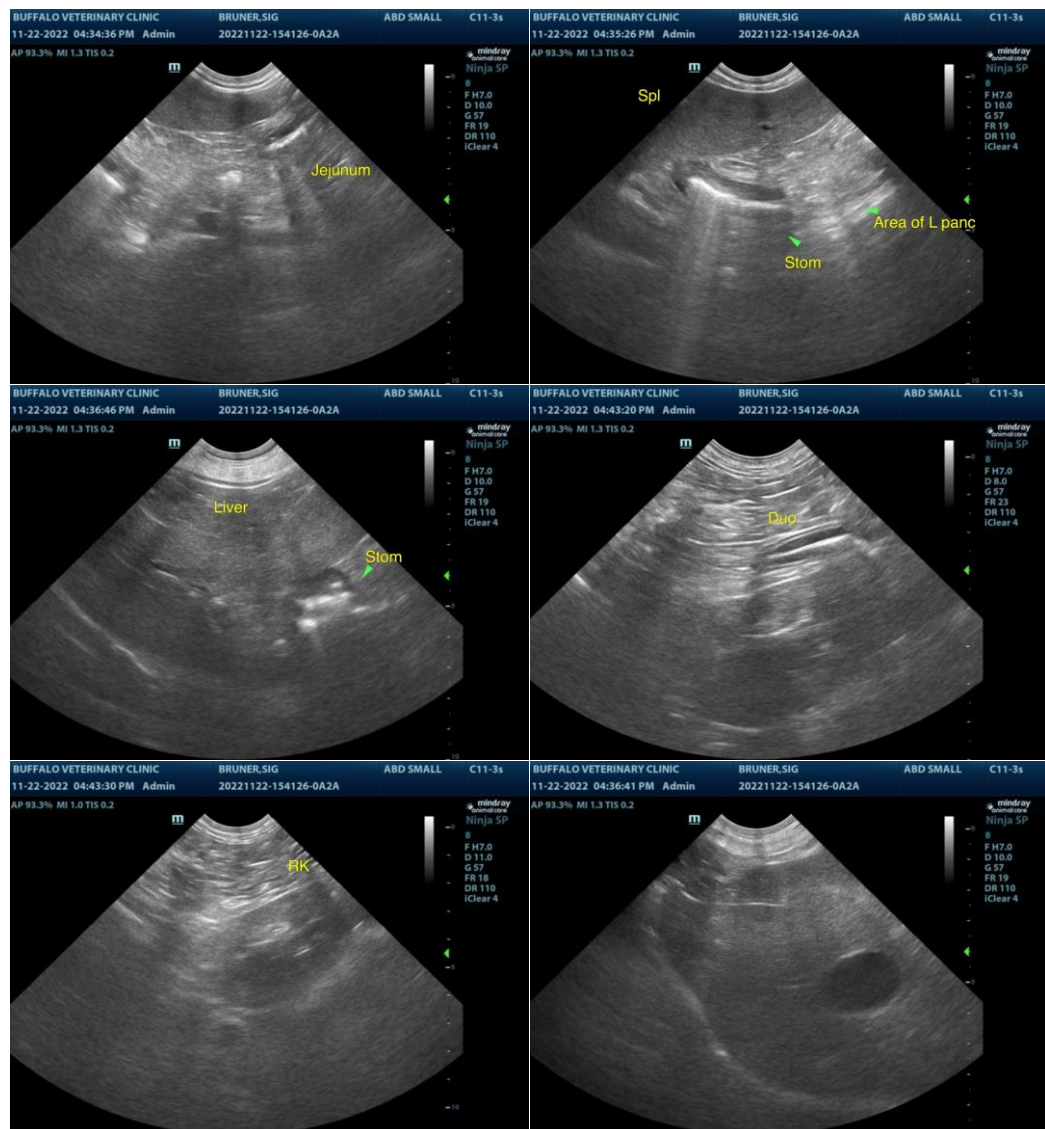
11/22/2022

ULTRASONOGRAPHIC FINDINGS

- Normal echocardiogram
- Subjective mild benign hepatomegaly
- Sonographically normal spleen
- Sonographically unremarkable GI tract
- Mild to moderate chronic renal changes-no evidence of renal neoplasia

INTERPRETATION OF THE FINDINGS & FURTHER RECOMMENDATIONS

No evidence of structural or functional cardiomyopathy with a largely geriatric abdomen. A definitive cardiac or non-cardiac/intra-abdominal cause of the arrhythmia or of the patient's weight loss was not obvious. A cardiology ECG consult +/- Holter monitor and a GI panel to include PLI/TLI/Cobalamin/Folate is recommended. Three view chest radiographs are recommended if not done to assess for occult thoracic pathology. A thorough musculoskeletal and neurological examination is warranted.





PATIENT

Sig Bruner

SPECIES

Canine

BREED

Heeler

SEX

MN

AGE

13yr

WEIGHT

44

INTERPRETED BY

R. McKenzie Daniel,
DVM, DABVP
(Canine and Feline)

IMAGING PERFORMED BY

Nicole Gotfredson

HOSPITAL NAME

Buffalo Veterinary
Clinic

REFERRING VET

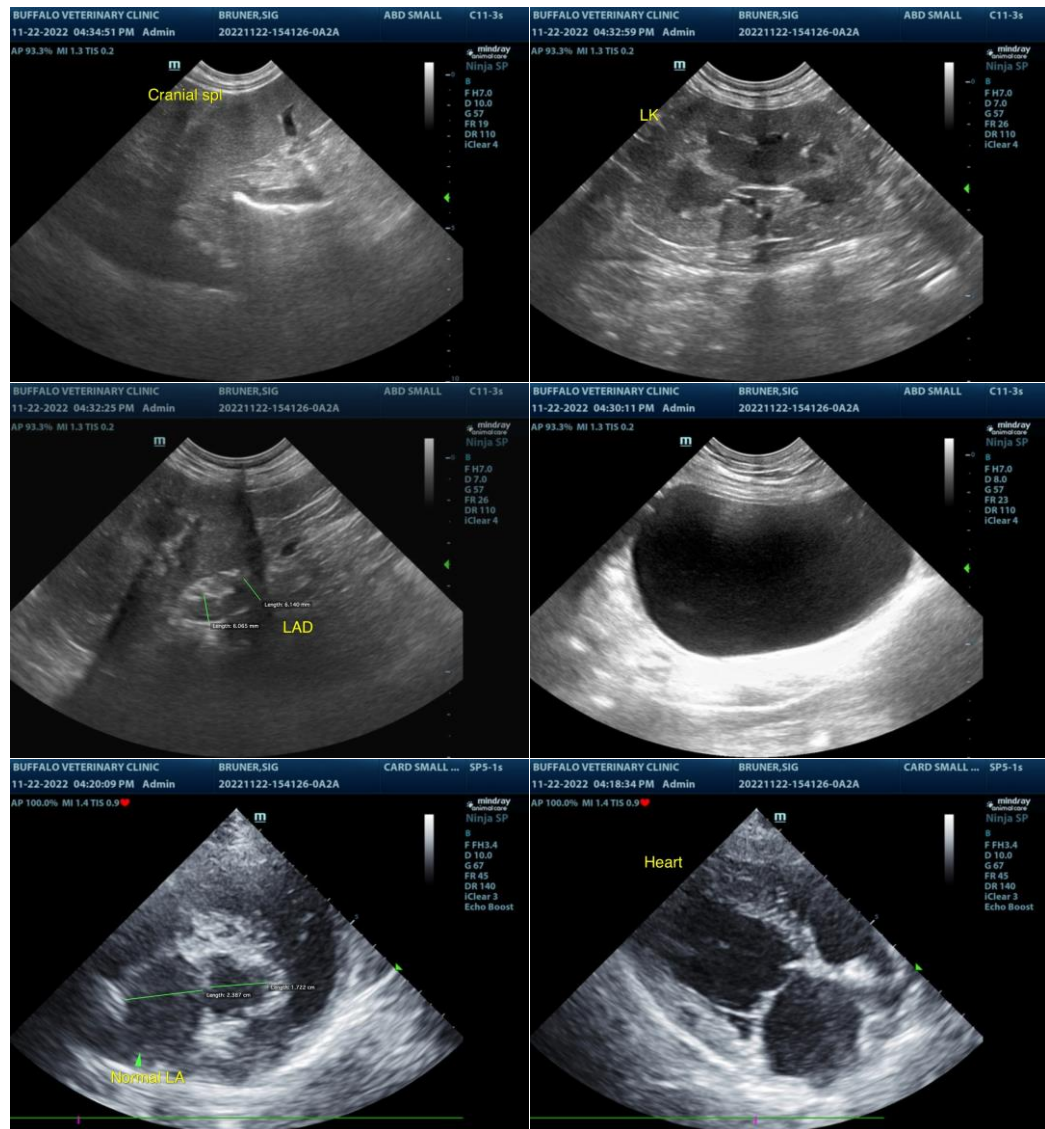
Dr, Garry Gotfredson

INVOICE

12236ag

DATE

11/22/2022



The information and recommendations provided are based on the images presented by the referring veterinarian/sonographer. No evaluation can be communicated regarding pathology that was not visible in the image/video clips provided.

Thank you for this referral. If the clinical or image interpretation does not parallel your findings or if I can be of any further assistance, please contact me.

R. McKenzie Daniel, DVM, DABVP (Canine/Feline Practice)
mac.daniel@sonopath.com