



PATIENT

Fox Santomauro

SPECIES

Canine

BREED

Pomeranian Mix

SEX

MN

AGE

10 years

WEIGHT

16.4 lbs.

INTERPRETED BY

R. McKenzie Daniel,
DVM, DABVP

IMAGING PERFORMED BY

Kelly Vazquez

HOSPITAL NAME

Well Pet AH

REFERRING VET

Dr. David Wellington

INVOICE

15551

DATE

11/22/22

PRESENTING CLINICAL SIGNS

Patient presents for grade 3/4 heart murmur.

Abnormal PE/Chem/CBC/UA Results: Pending.

ULTRASONOGRAPHIC EXAMINATION OF THE HEART

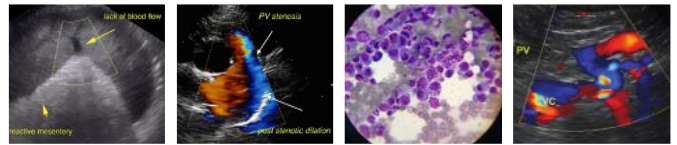
| CANINE CARDIAC PARAMETERS | MR VMAX (m/s) | TR VMAX (m/s) | LA/AO (Boon method) | LA/AO (Heart Base; Swe) | FS (%) | EF (%) | EPSS (cm) |
|---------------------------|---------------|---------------|---------------------|-------------------------|---------------------------------|------------------------------------------|------------------------------------------|
| NORMAL PARAMETER | 4.5-5.5 | <2.7 | 1.3 | <1.6 | 28-40 | 40-100 | <0.6 |
| PATIENT | | | | 1.35 | 44.4 | 79 | 0.1 |
| CANINE CARDIAC PARAMETERS | HR (BPM) | AV VMAX (m/s) | PV MAX (m/s) | BODY WEIGHT (kg) | LA 2D short axis Base view (cm) | LVIDd Avg; 2D and m-mode short axis (cm) | LVIDs Avg; 2D and m-mode short axis (cm) |
| NORMAL PARAMETER | 50-100 | 0.7-1.7 | 0.7-1.6 | BELOW | BELOW | BELOW | BELOW |
| PATIENT | 105 | 2.0 | 1.3 | | 2.7 | 2.7 | |

Cardiac Presentation

The echocardiogram in this patient demonstrated normal **left atrial** size based on 3 different LA measurement methods. Chamber volumes and echogenicity were normal. The cranial and caudal **mitral** valve leaflets presented mild thickening consistent with mild endocardiosis, more prominent in the septal leaflet. No evidence of valvular prolapse. Doppler indicated mild eccentric insufficiency. The **left ventricle** presented thicknesses with linear contour and was not dilated nor restricted. The **myocardium** presented normal echogenicity without subjective evidence of significant fibrotic or ischemic disease. **Contractility** of the ventricular walls was adequate and in normal range for this patient evidenced by the fractional shortening measurement and subjective evaluation of the different regions of the myocardium. The **left ventricular outflow** tract demonstrated normal laminar flow and subjective structural integrity. The **right atrium** and auricle revealed normal size, structure and content. No evidence of masses was noted or chamber overload. **Tricuspid** valvular assessment demonstrated adequate linear morphology. The **right ventricle** was of normal size (1/3 diameter of LV), chordae structure, myocardial echogenicity and thickness. **Pulmonic** tract assessment revealed normal valve structure, laminar flow, and diameter (approx. 1:1 pa/ao ratio). No visible **pericardial** or free pleura fluid was noted. No echographically detectable evidence of infiltrative disease was visible. The cranial **mediastinum and pericardial regions** were free of masses in the visible window.

ULTRASONOGRAPHIC FINDINGS

- Chronic mitral valve disease (ACVIM B1)



PATIENT

Fox Santomauro

SPECIES

Canine

BREED

Pomeranian Mix

SEX

MN

AGE

10 years

WEIGHT

16.4 lbs.

INTERPRETED BY

R. McKenzie Daniel, DVM, DABVP

IMAGING PERFORMED BY

Kelly Vazquez

HOSPITAL NAME

Well Pet AH

REFERRING VET

Dr. David Wellington

INVOICE

15551

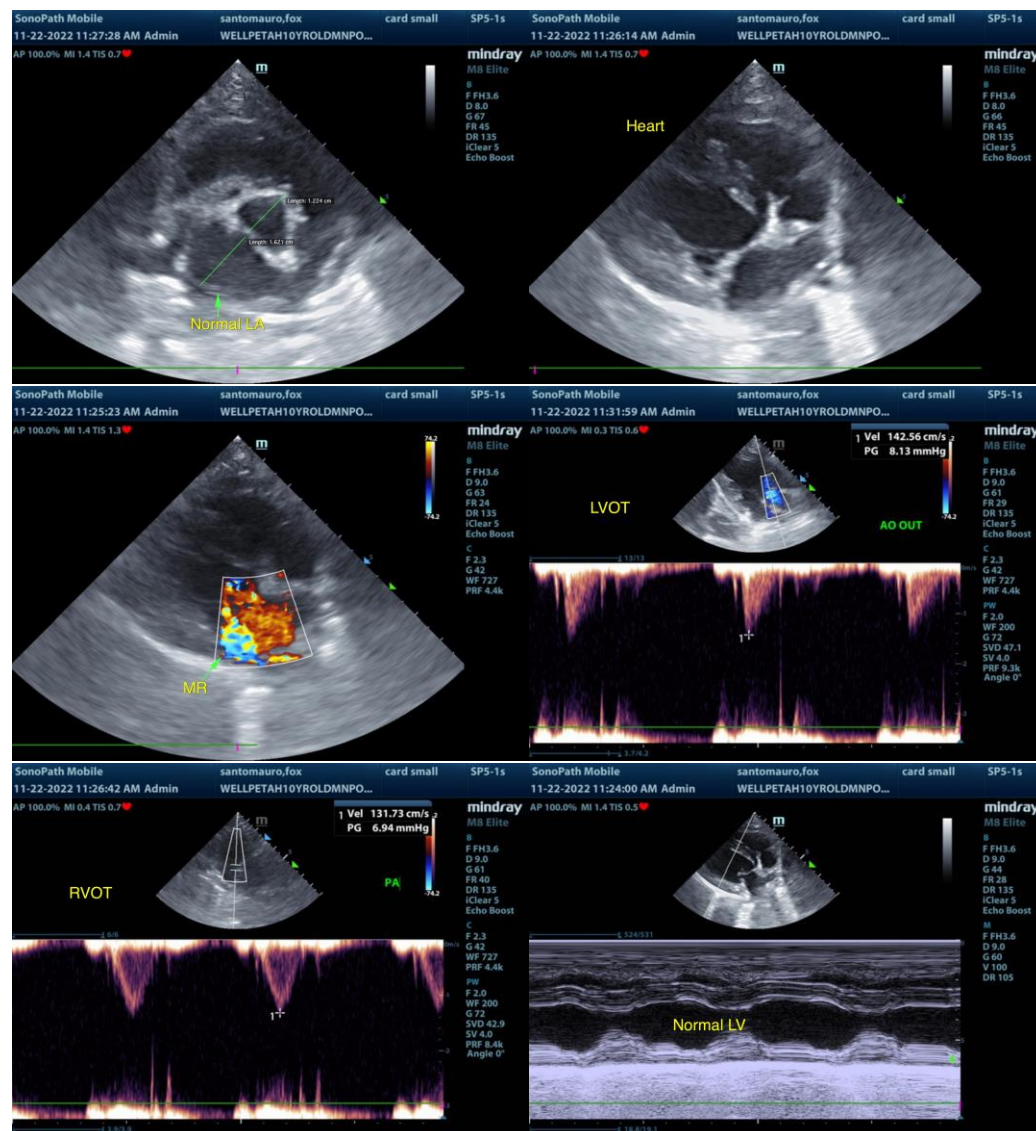
DATE

11/22/22

INTERPRETATION OF THE FINDINGS & FURTHER RECOMMENDATIONS

The cause of the murmur is chronic degenerative valvular changes with secondary eccentric mitral valve insufficiency. No evidence of additional clinical issues such as LV systolic dysfunction or clinical pulmonary hypertension.

The lack of left atrial enlargement implies that the risk of complication secondary to mitral valve insufficiency is low at this time and, without current clinical signs, indicates that medical therapy is not required. Prognosis at this stage is highly variable and serial sonographic monitoring is recommended. Recheck echocardiogram is recommended in 6-12 months, sooner if clinical signs arise suggestive of heart disease arise.



The information and recommendations provided are based on the images presented by the referring veterinarian/sonographer. No evaluation can be communicated regarding pathology that was not visible in the image/video clips provided.



PATIENT

Fox Santomauro

Thank you for this referral. If the clinical or image interpretation does not parallel your findings or if I can be of any further assistance please contact me.

SPECIES

Canine

R. McKenzie Daniel, DVM, DABVP (Canine / Feline Practice)
info@SonoPath.com

BREED

Pomeranian Mix

SEX

MN

AGE

10 years

WEIGHT

16.4 lbs.

INTERPRETED BY

R. McKenzie Daniel,
DVM, DABVP

**IMAGING
PERFORMED BY**

Kelly Vazquez

HOSPITAL NAME

Well Pet AH

REFERRING VET

Dr. David Wellington

INVOICE

15551

DATE

11/22/22