



**PATIENT**

Ragnar Morrell

**SPECIES**

Canine

**BREED**

Great Dane

**SEX**

Male

**AGE**

1

**WEIGHT**

126

**INTERPRETED BY**

R. McKenzie Daniel,  
DVM, DABVP

**IMAGING PERFORMED BY**

Jenn

**HOSPITAL NAME**

Rockaway Animal  
Hospital

**REFERRING VET**

Dr. Maniar

**INVOICE**

12367

**DATE**

11/21/25

**PRESENTING CLINICAL SIGNS**

Presented for F/U re check abd only from 11/11 Owner reports doing well at home

**ULTRASONOGRAPHIC EXAMINATION OF THE ABDOMEN**

**Urinary System**

The urinary bladder, trigone, cystourethral junction, and visible pelvic urethra exhibited normal thickness and tone. Anechoic urine was present in the lumen with no uroliths or sediment. The ureteral papillae were normal. The ureters were not visible which is normal. No evidence of inflammatory or neoplastic change were noted.

The prostate was mildly enlarged in size with intact, symmetrical capsule contour. The margins of the gland were intact and able to be differentiated from the surrounding tissue. The prostatic parenchyma was mildly echogenic to heteroechoic without parenchymal mineralization. The prostate measured 3.5 cm in diameter.

Normal size and margination was present in the kidneys. A normal 1:3 cortex / medulla ratio and normal corticomedullary definition were maintained. The echogenicity of the cortex was similar to or slightly less than normal liver parenchyma while the medulla echogenicity was hypoechoic to the cortex with no evidence of pelvic dilation. The left kidney measured 8.6 cm in length. The right kidney measured 8.4 cm in length.

**Adrenal Glands**

The left adrenal gland was uniform in size and contour with a uniformly hypoechoic parenchyma. The left adrenal gland measured 0.64 cm width at the caudal pole. The right adrenal gland was uniform in size and contour with a uniformly hypoechoic parenchyma. The right adrenal gland measured 0.65 cm width at the caudal pole.

**Spleen**

The spleen exhibited a finely textured and homogenous parenchyma which was hyperechoic to the liver and renal cortical parenchyma. The capsule was smooth and regular without apparent expansion. The splenic vasculature at the hilus was normal in volume with no evidence of congestion or thrombosis. Acute to chronic inflammatory, neoplastic, or benign parenchyma changes were not noted.

**Liver**

The liver was subjectively normal in size, structure, and contour. The liver parenchyma was uniform and hypoechoic to the spleen with a mild coarse echotexture. The hepatic and portal vasculature were normal in appearance without signs of congestion. The gallbladder was non-distended in size with thin walls and primarily anechoic luminal content. The cystic and common bile ducts were normal.

**Gastrointestinal**

The stomach presented intact wall layering with a normal wall layer ratio. The lumen of the stomach was empty with no signs of ileus, obstruction or foreign material.

The small intestine presented intact wall layering with 1:3 muscularis/mucosa ratio. The lumen of the small intestine was empty with no signs of ileus, obstruction or foreign material.



**PATIENT**

Normal visible colon wall layers were present with apparent formed feces in lumen.

Ragnar Morrell

**Pancreas**

**SPECIES**

The parenchyma of the left limb, body and right limb of the pancreas presented isoechoic to the adjacent omental fat. A normal curvilinear capsule contour of the pancreas was present. The visible pancreatic duct was normal. No signs of active inflammation or neoplastic disease was evident.

Canine

**BREED**

**Free Abdomen**

Great Dane

No overt lymphadenopathy or peritoneal effusion was present.

**SEX**

**ULTRASONOGRAPHIC FINDINGS**

Male

- Sonographically normal abdomen.
- Mild benign prostatic hyperplasia- normal prostatic presentation for a young intact male canine.

**AGE**

**INTERPRETATION OF THE FINDINGS & FURTHER RECOMMENDATIONS**

1

No evidence of visceral pathology.

**WEIGHT**

126

**INTERPRETED BY**

R. McKenzie Daniel,  
DVM, DABVP

**IMAGING PERFORMED BY**

Jenn

**HOSPITAL NAME**

Rockaway Animal  
Hospital

**REFERRING VET**

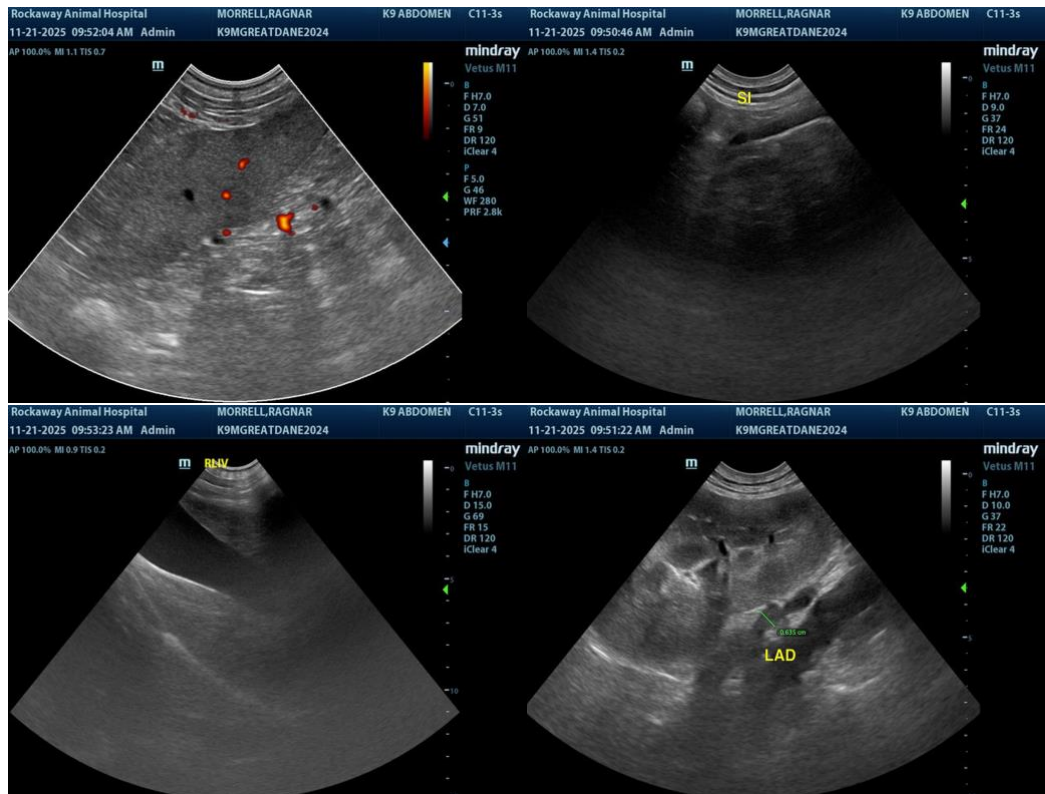
Dr. Maniar

**INVOICE**

12367

**DATE**

11/21/25





**PATIENT**

Ragnar Morrell

**SPECIES**

Canine

**BREED**

Great Dane

**SEX**

Male

**AGE**

1

**WEIGHT**

126

**INTERPRETED BY**

R. McKenzie Daniel,  
DVM, DABVP

**IMAGING PERFORMED BY**

Jenn

**HOSPITAL NAME**

Rockaway Animal  
Hospital

**REFERRING VET**

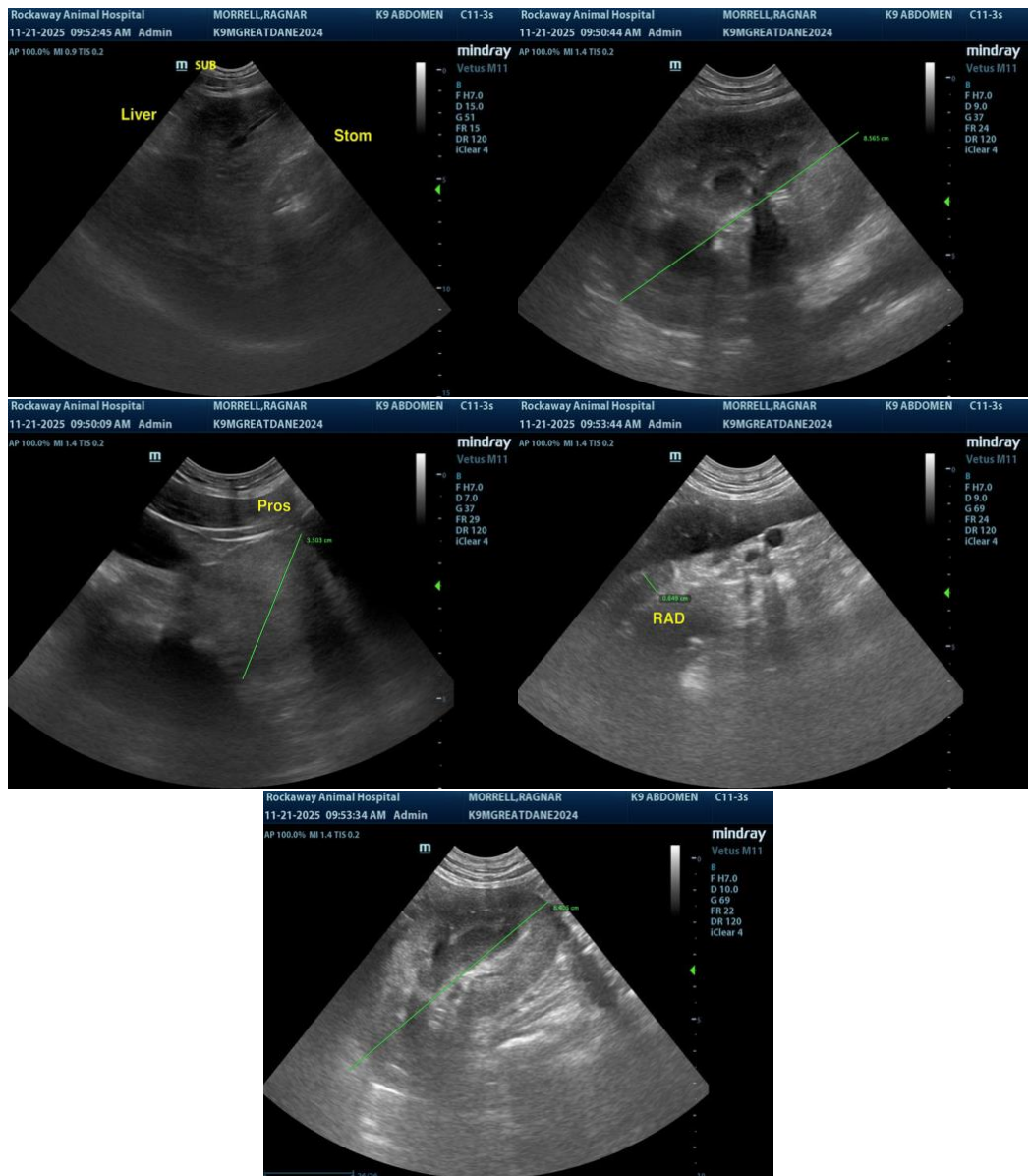
Dr. Maniar

**INVOICE**

12367

**DATE**

11/21/25



The information and recommendations provided are based on the images presented by the referring veterinarian/sonographer. No evaluation can be communicated regarding pathology that was not visible in the image/video clips provided.

Thank you for this referral. If the clinical or image interpretation does not parallel your findings or if I can be of any further assistance, please contact me.

R. McKenzie Daniel, DVM, DABVP (Canine / Feline Practice)

[info@SonoPath.com](mailto:info@SonoPath.com)