

PATIENT

Marmalade Eden

SPECIES

Feline

BREED

DSH

SEX

FS

AGE

7m

WEIGHT

1.73 kg

INTERPRETED BY

R. McKenzie Daniel,
DVM, DABVP
(Canine and Feline)

IMAGING PERFORMED BY

Lauren Kuzimski,
DVM

HOSPITAL NAME

Animal Emergency
Hospital Deland

REFERRING VET

Dr. Kari Lemanski,
DVM

INVOICE

10377

DATE

11/20/25

PRESENTING CLINICAL SIGNS

Marmalade is a 7m FS DSH that presents for lethargy and not eating. O states pt was spayed three weeks ago and since then has not been wanting to eat as much and did not want to eat at all today. No vomiting or diarrhea. Bloodwork revealed pancreatitis and elevated liver enzymes.

ULTRASONOGRAPHIC EXAMINATION OF THE ABDOMEN

Urinary System

The urinary bladder, trigone, cystourethral junction, and visible pelvic urethra to a depth of 2.0 cm exhibited normal thickness and tone. Anechoic urine was present in the lumen with no evidence of urine or lumen sediment, mineral, or calculi. The ureteral papillae were normal. The ureters were not visible which is normal. No evidence of inflammatory or neoplastic changes was noted.

No evidence of pathology in the area of the aortic trifurcation.

Normal size and margination were present in the kidneys. A normal 1:3 cortex / medulla ratio and normal corticomedullary definition were maintained. The echogenicity of the cortex was similar to or slightly less than normal liver parenchyma while the medulla echogenicity was hypoechoic to the cortex with no evidence of pelvic dilation. A prominent hyperechoic corticomedullary band, consistent with a medullary rim sign, was present. This is a nonspecific finding seen in both normal and abnormal kidneys. It may be associated interstitial renal disease, hypercalcemia, tubular necrosis, lymphoma, and FIP. However, it is a nonspecific finding. The left kidney measured 4.0 cm in length. The right kidney measured 3.9 cm in length.

Adrenal Glands

The left adrenal gland was overtly normal in size, position, and shape. The left adrenal gland measured 0.38 cm width. The right adrenal gland was not definitively visualized.

Spleen

The spleen was normal in size and contour, exhibiting nonhomogeneous hypoechoic parenchyma. The spleen measured 0.64 cm diameter.

Liver/ Gallbladder

The liver was subjectively mildly enlarged with mild asymmetrical hepatic capsule contour and nonhomogeneous parenchyma. Intermittent, hypoechoic intraparenchymal hepatic nodules were present with an example measuring 0.93 cm diameter. The gallbladder was non-distended in size with thin walls and primarily anechoic luminal content. The proximal common bile duct was dilated and tortuous without overt post hepatic obstruction.



PATIENT

Marmalade Eden

SPECIES

Feline

BREED

DSH

SEX

FS

AGE

7m

WEIGHT

1.73 kg

INTERPRETED BY

R. McKenzie Daniel,
DVM, DABVP
(Canine and Feline)

IMAGING PERFORMED BY

Lauren Kuzimski,
DVM

HOSPITAL NAME

Animal Emergency
Hospital Deland

REFERRING VET

Dr. Kari Lemanski,
DVM

INVOICE

10377

DATE

11/20/25

Gastrointestinal

The stomach presented intact wall layering with a normal wall layer ratio. The lumen of the stomach was empty without evidence of retained ingesta, fluid, or foreign material.

The small intestine presented intact wall layering with 1:3 muscularis/mucosa ratio. The lumen of the small intestine was empty with no signs of ileus, obstruction, or foreign material. The small Intestinal wall width measured 0.20 cm.

Normal visible colon wall layers were present with apparent formed feces in lumen.

Pancreas

The left pancreas exhibited subjective enlargement with swollen capsule contour and hypoechoic mildly nonhomogeneous parenchyma. The left pancreatic limb measured 0.79 cm width.

Free Abdomen

Multiple, variably enlarged to swollen, nonhomogeneous, hypoechoic mesenteric lymph nodes were present, with an example measuring 3.3 cm x 1.2 cm. Mild volume peritoneal effusion was noted. Generalized omental hyperechogenicity was present.

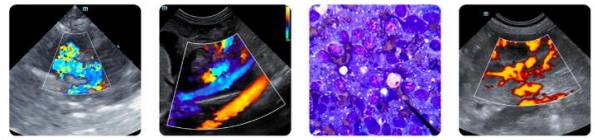
ULTRASONOGRAPHIC FINDINGS

- Bilateral renal medullary rim sign
- Enlarged nonhomogeneous nodular liver
- Mild nonobstructive proximal common bile duct dilation
- Sonographically normal gastrointestinal tract
- Hypoechoic swollen pancreas
- Non-enlarged hypoechoic spleen
- Multiple variably enlarged to swollen nonhomogeneous hypoechoic mesenteric lymph nodes, mild volume peritoneal effusion

INTERPRETATION OF THE FINDINGS & FURTHER RECOMMENDATIONS

Multicentric to significant inflammatory disease, including pancreatitis, neoplasia, or FIP are primary considerations, with primary concern for neoplastic criteria warranted.

Assuming normal clotting status and using a 25-gauge needle, further assessment may include FNA cytology of mesenteric lymph node, liver, +/- spleen, as well as effusion analysis cytology, +/- C/S and FIP titers / PCR if clinically indicated is recommended. Pending additional diagnostics, supportive care and empirical therapy for pancreatitis would be reasonable. A guarded prognosis is indicated.



PATIENT

Marmalade Eden

SPECIES

Feline

BREED

DSH

SEX

FS

AGE

7m

WEIGHT

1.73 kg

INTERPRETED BY

R. McKenzie Daniel,
DVM, DABVP
(Canine and Feline)

IMAGING PERFORMED BY

Lauren Kuzimski,
DVM

HOSPITAL NAME

Animal Emergency
Hospital Deland

REFERRING VET

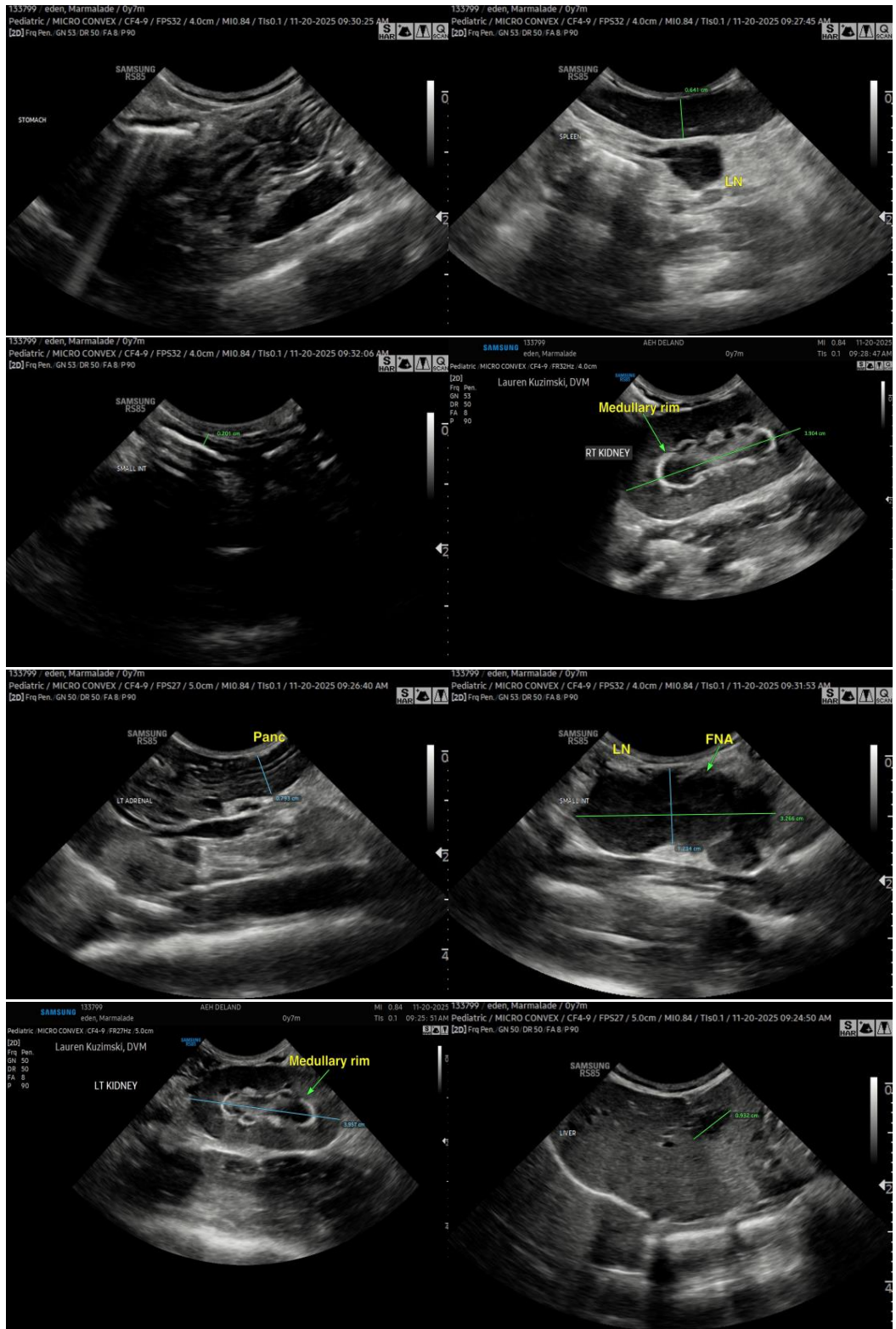
Dr. Kari Lemanski,
DVM

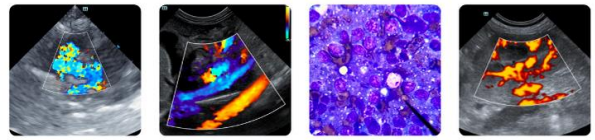
INVOICE

10377

DATE

11/20/25





PATIENT

Marmalade Eden

SPECIES

Feline

BREED

DSH

SEX

FS

AGE

7m

WEIGHT

1.73 kg

INTERPRETED BY

R. McKenzie Daniel,
DVM, DABVP
(Canine and Feline)

IMAGING PERFORMED BY

Lauren Kuzimski,
DVM

HOSPITAL NAME

Animal Emergency
Hospital Deland

REFERRING VET

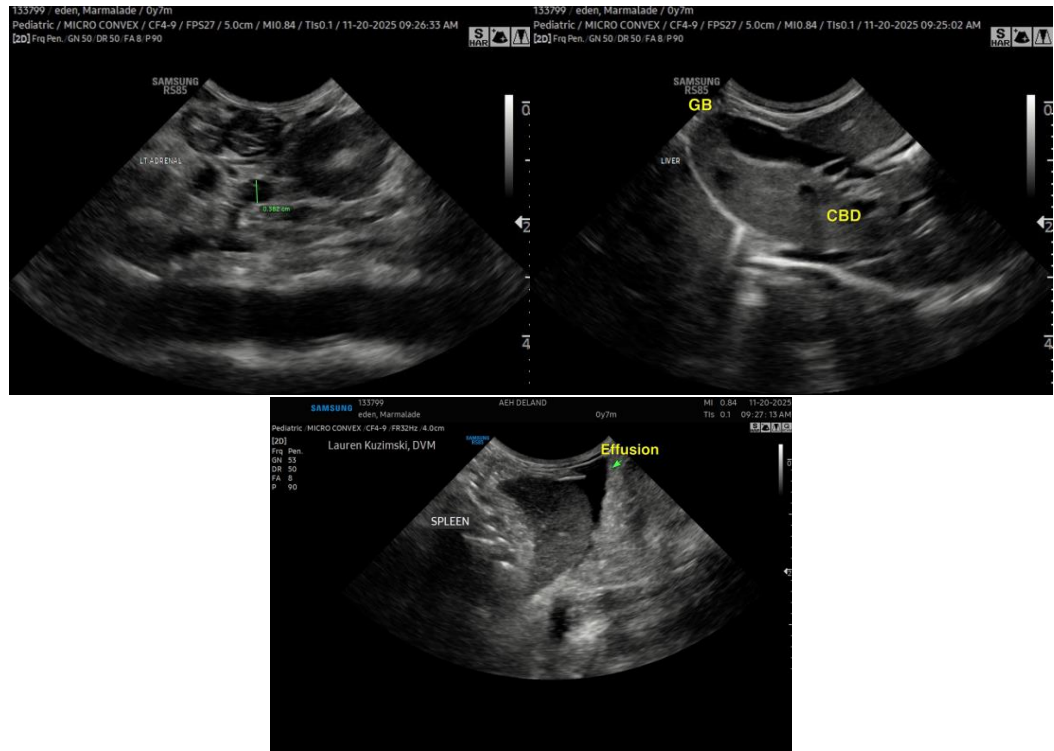
Dr. Kari Lemanski,
DVM

INVOICE

10377

DATE

11/20/25



The information and recommendations provided are based on the images presented by the referring veterinarian/sonographer. No evaluation can be communicated regarding pathology that was not visible in the image/video clips provided.

Thank you for this referral. If the clinical or image interpretation does not parallel your findings or if I can be of any further assistance, please contact me.

R. McKenzie Daniel, DVM, DABVP (Canine/Feline Practice)

info@sonopath.com