



PATIENT

Duncan Santana

SPECIES

Canine

BREED

Pug

SEX

Neutered Male

AGE

15 Years 4 Months

WEIGHT

23.4 pounds

INTERPRETED BY

R. McKenzie Daniel,
DVM, DABVP (Canine
/ Feline Practice)

IMAGING PERFORMED BY

Shari Reffi, CVT

HOSPITAL NAME

Barton Heights

REFERRING VET

Dr. Bienkowski

INVOICE

12347

DATE

11/20/25

PRESENTING CLINICAL SIGNS

Elevated LE's and bile acids. Weight loss, slight icteric (skin). Receiving Metronidazole

Abnormal PE/Chem/CBC/UA Results: Elevated Le's, low bg, albumin, chol. Elevated bile acids.

ULTRASONOGRAPHIC EXAMINATION OF THE ABDOMEN

Urinary System

Multifocal small, dependent lumen urinary bladder mineral to calculi were visualized. Mild ventroapical to dorsal apical cystitis pattern was present with concurrent nondependent particulate urine sediment. The trigone and cystourethral junction were free of obvious pathology. The urethra was normal in structure and tone.

The area of the aortic trifurcation was free of pathology.

No obvious pathology in the area of the residual prostate.

Normal size and margination was present in the kidneys. A normal 1:3 cortex / medulla ratio was maintained. The medulla and cortices were uniform in texture with some increased echogenicity and mild loss of corticomedullary symmetry and definition expected for the age of the patient. Mild medullary mineral was visualized. The left kidney measured 4.5 cm in length. The right kidney measured 5.1 cm in length.

Adrenal Glands

The left adrenal gland was normal in size with mildly enlarged right adrenal gland size.. Mild parenchyma heterogeneity and mild capsule asymmetry was present without suspicion for overt neoplasia. The left adrenal gland measured 0.52 cm width in the caudal pole. The right adrenal gland measured 0.80 cm width in the caudal pole.

Spleen

The spleen exhibited primarily finely textured parenchyma which was hyperechoic to the liver and renal cortical parenchyma. Mild generalized parenchyma heterogeneity was present without evidence of nodular changes. The capsule was smooth and regular without apparent expansion. The splenic vasculature at the hilus was normal in volume with no evidence of congestion or thrombosis. The parenchymal heterogeneity is likely consistent with benign changes such as extramedullary hematopoiesis or age-related remodeling with minor potential for inflammatory or neoplastic disease.

Liver

The liver presented with enlarged size, asymmetrical capsule contour and diffuse nonhomogenous variably nodular parenchyma. An example of liver nodule measured 2.4 cm in diameter. A moderately expansive mixed echogenic mid liver mass was visualized measuring approximately 7.0 cm in diameter.

The gallbladder was non-distended in size. The gallbladder lumen was primarily occupied by mildly organized nonmineralized bile sediment. The common bile duct was not visualized.

Gastrointestinal

The stomach presented with intact mildly thickened wall. The stomach was nondistended with lumen gas.



PATIENT

Duncan Santana

The intestinal walls demonstrated intact wall layering and maintained 1:3 muscularis / mucosa ratio. Segmental intestinal mucosal speckling and subjective decreased mucosa echogenicity. Possible nonobstructive duodenal mural lesion measuring approximately 1.5 cm in diameter.

SPECIES

Canine

Normal visible colon wall layers were present with apparent formed feces in lumen.

Pancreas

BREED

Pug

The pancreas was normal in size and contour with heterogeneous remodeled parenchyma compared to adjacent omentum. No signs of active inflammation or neoplasia.

Free Abdomen

SEX

Neutered Male

Generalized omental hyperechogenicity and scant pockets of peritoneal effusion were evident.

ULTRASONOGRAPHIC FINDINGS

AGE

15 Years 4 Months

Primary Findings

- Diffuse nonhomogenous nodular hepatic parenchyma with hepatic mass.
- Gallbladder mucocele.
- Nonspecific potentially acute to subacute gastroenteropathy with possible nonobstructive duodenal lumen lesion.
- Heterogeneous remodeled pancreas.
- Peritonitis.

WEIGHT

23.4 pounds

Secondary Findings

- Bilateral chronic renal changes exhibiting mild medullary mineral.
- Urinary bladder dependent lumen mineral/small calculi.

INTERPRETED BY

R. McKenzie Daniel,
DVM, DABVP (Canine
/ Feline Practice)

INTERPRETATION OF THE FINDINGS & FURTHER RECOMMENDATIONS

IMAGING PERFORMED BY

Shari Reffi, CVT

The liver presentation is consistent with diffuse hepatic neoplasia criteria. Multicentric neoplasia potentially involving the gastrointestinal tract or regional perihepatic to generalized omental seeding is possible. Assuming normal clotting status, hepatic parenchyma and mass FNA cytology could be considered for further clarification. Unfortunately, curative surgical options appear precluded. An unfavorable prognosis is indicated. Empirical supportive care is indicated.

HOSPITAL NAME

Barton Heights

REFERRING VET

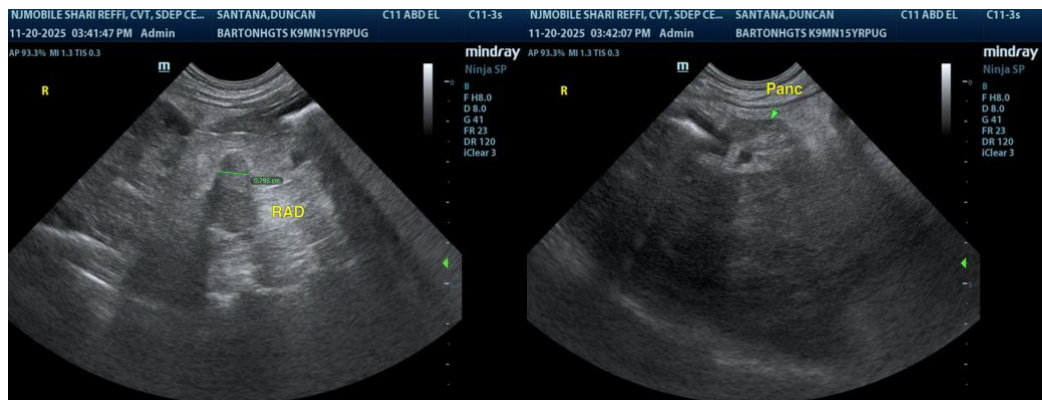
Dr. Bienkowski

INVOICE

12347

DATE

11/20/25





PATIENT

Duncan Santana

SPECIES

Canine

BREED

Pug

SEX

Neutered Male

AGE

15 Years 4 Months

WEIGHT

23.4 pounds

INTERPRETED BY

R. McKenzie Daniel,
 DVM, DABVP (Canine
 / Feline Practice)

IMAGING PERFORMED BY

Shari Reffi, CVT

HOSPITAL NAME

Barton Heights

REFERRING VET

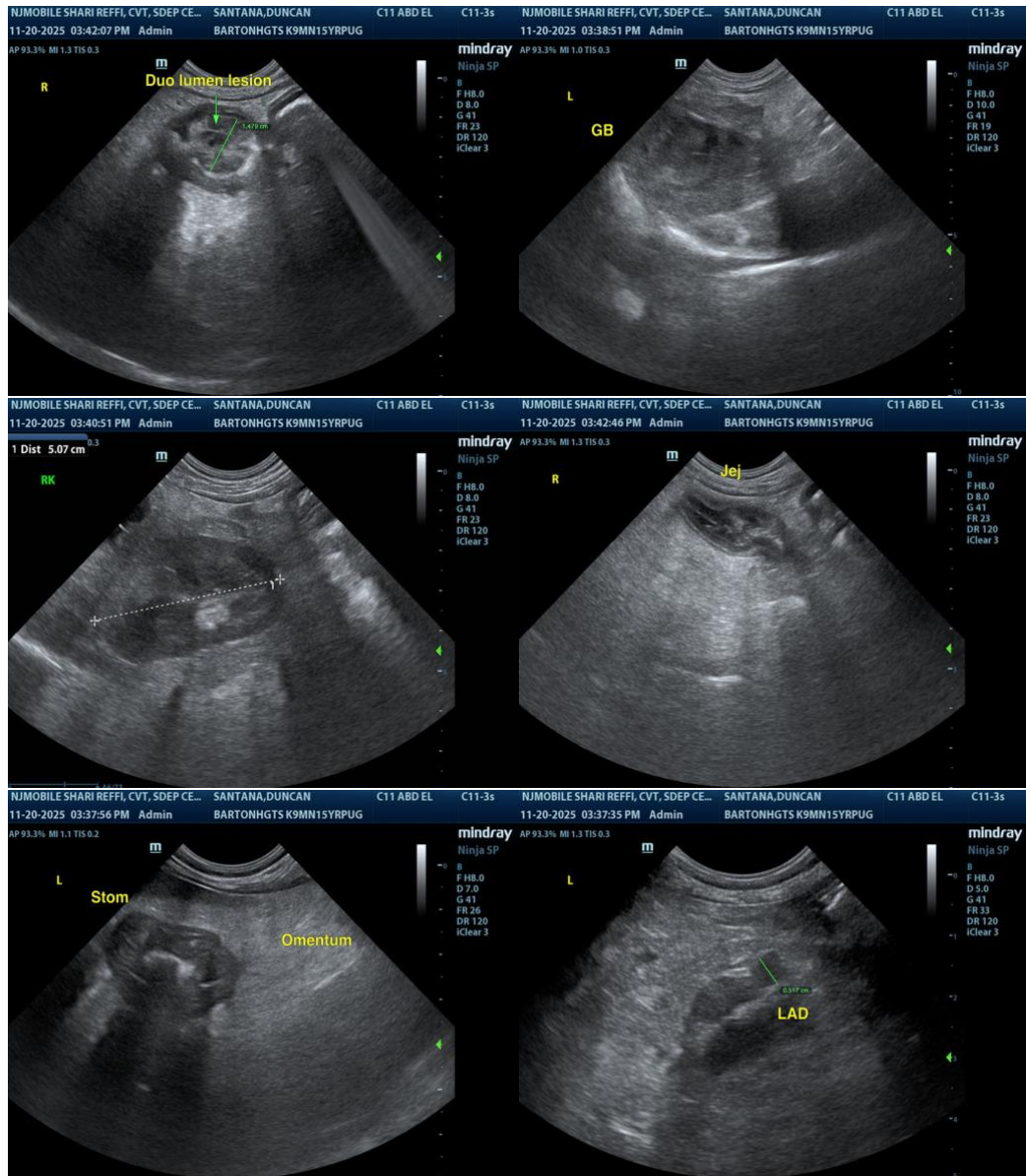
Dr. Bienkowski

INVOICE

12347

DATE

11/20/25





PATIENT

Duncan Santana

SPECIES

Canine

BREED

Pug

SEX

Neutered Male

AGE

15 Years 4 Months

WEIGHT

23.4 pounds

INTERPRETED BY

R. McKenzie Daniel,
DVM, DABVP (Canine
/ Feline Practice)

IMAGING PERFORMED BY

Shari Reffi, CVT

HOSPITAL NAME

Barton Heights

REFERRING VET

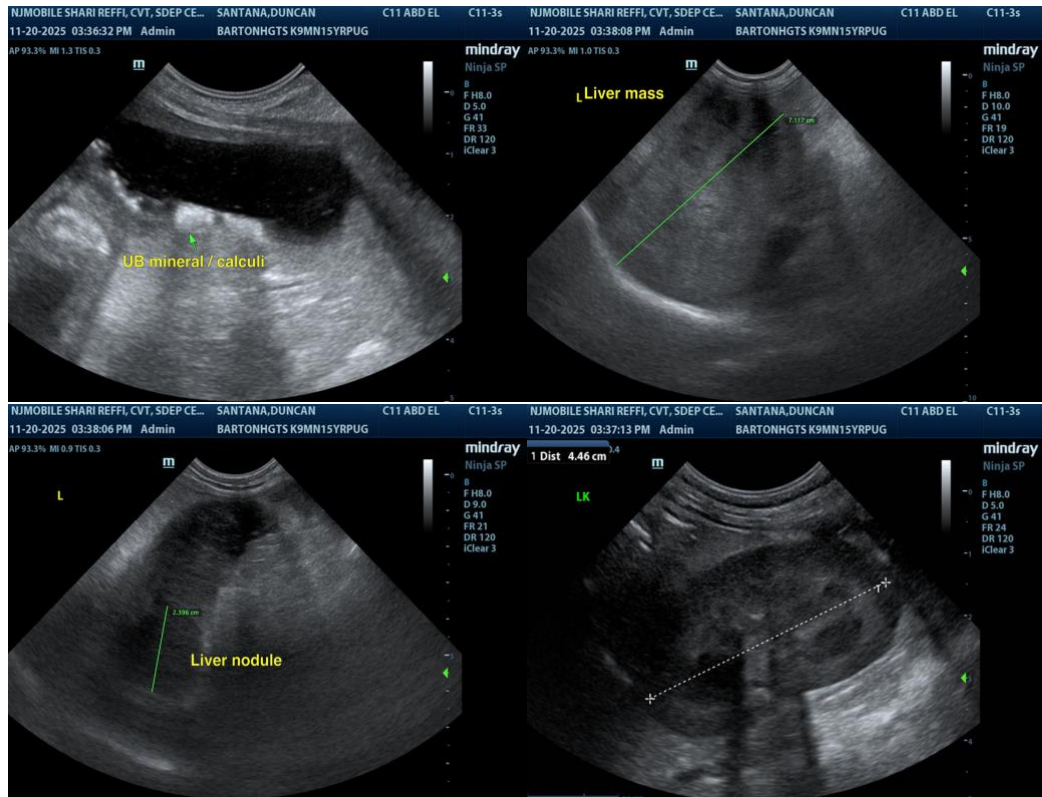
Dr. Bienkowski

INVOICE

12347

DATE

11/20/25



The information and recommendations provided are based on the images presented by the referring veterinarian/sonographer. No evaluation can be communicated regarding pathology that was not visible in the image/video clips provided.

Thank you for this referral. If the clinical or image interpretation does not parallel your findings or if I can be of any further assistance, please contact me.

R. McKenzie Daniel, DVM, DABVP (Canine / Feline Practice)

info@SonoPath.com