

**PATIENT**

Smeez White

SPECIES

Feline

BREED

DSH

SEX

NM

AGE

12 years

WEIGHT

13 lbs.

INTERPRETED BY

R. McKenzie Daniel,
DVM, DABVP
(Canine and Feline)

IMAGING PERFORMED BY

Sarah Pender, CVT

HOSPITAL NAME

SVS Imaging QC

REFERRING VET

Dr. Westerhof

INVOICE

15332

DATE

11/2/22

PRESENTING CLINICAL SIGNS

Urinary accidents

Abnormal PE/Chem/CBC/UA Results: urinalysis showed RBC plus WBC, pH 6.5, (+) cocci; SG 1050

ULTRASONOGRAPHIC EXAMINATION OF THE ABDOMEN**Urinary System**

The urinary bladder, trigone, cystourethral junction, and visible pelvic urethra to a depth of 2.0 cm exhibited normal thickness and tone. Anechoic urine was present in the lumen with no uroliths or sediment. The ureteral papillae were normal. The ureters were not visible which is normal. No evidence of inflammatory or neoplastic changes was noted.

The area of the aortic trifurcation was free of pathology.

Normal size and margination were present in the kidneys. A normal 1:3 cortex / medulla ratio was maintained. The medulla and cortices were uniform in texture with some increased echogenicity and mild loss of corticomodullary symmetry and definition expected for the age of the patient. No evidence of pyelectasia was present. The left kidney measured 4.7 cm in length. The right kidney measured 4.0 cm in length.

Adrenal Glands

The left adrenal gland was uniform in size and contour with a uniformly hypoechoic parenchyma. The left adrenal gland measured 0.28 cm width. The right adrenal gland was uniform in size and contour with a uniformly hypoechoic parenchyma. The right adrenal gland measured 0.23 cm width.

Spleen

The spleen exhibited a finely textured and homogenous parenchyma which was hyperechoic to the liver and renal cortical parenchyma. The capsule was smooth and regular without apparent expansion. The splenic vasculature at the hilus was normal in volume with no evidence of congestion or thrombosis. Acute to chronic inflammatory, neoplastic, or benign parenchyma changes were not noted.

Liver/ Gallbladder

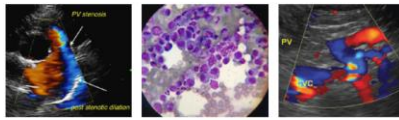
The liver was subjectively normal in size, structure, and contour. The liver parenchyma was uniform and hypoechoic to the spleen with a mild coarse echotexture. The hepatic and portal vasculature were normal in appearance without signs of congestion. The gallbladder was non-distended in size with thin walls and primarily anechoic luminal content. The cystic and common bile ducts were normal.

Gastrointestinal

The stomach presented intact wall layering with a normal wall layer ratio. Minor retained anechoic fluid was present.

The small intestine presented intact wall layering with 1:3 muscularis/mucosa ratio. The lumen of the small intestine was empty with no signs of ileus, obstruction, or foreign material.

Normal visible colon wall layers were present with apparent formed feces in lumen.



PATIENT

Smeez White

SPECIES

Feline

BREED

DSH

SEX

NM

AGE

12 years

WEIGHT

13 lbs.

Pancreas

The parenchyma of the left limb, body, and right limb of the pancreas presented isoechoic to the adjacent omental fat. A normal curvilinear capsule contour of the pancreas was present. The visible pancreatic duct was normal. No signs of active inflammation or neoplastic disease were evident.

Free Abdomen

No omental masses, lymphadenopathy, or peritoneal effusion were noted.

ULTRASONOGRAPHIC FINDINGS

- Sonographically unremarkable urinary bladder and visible proximal urethra
- Nonspecific mild chronic renal changes

INTERPRETATION OF THE FINDINGS & FURTHER RECOMMENDATIONS

No evidence of upper or lower urinary tract pathology as a definitive cause of the patient's urinary accidents and urinalysis abnormalities. No evidence of pyelonephritis, upper or lower urinary tract criteria, cystic calculi, cystitis, or other pathology.

Urine C/S on a sterile urine sample is recommended to assess for underlying infection. If underlying urinary infection is ruled out, empirical therapy for possible mild feline idiopathic cystitis could be considered with an assessment of clinical response.

INTERPRETED BY

R. McKenzie Daniel,
 DVM, DABVP
 (Canine and Feline)

IMAGING PERFORMED BY

Sarah Pender, CVT

HOSPITAL NAME

SVS Imaging QC

REFERRING VET

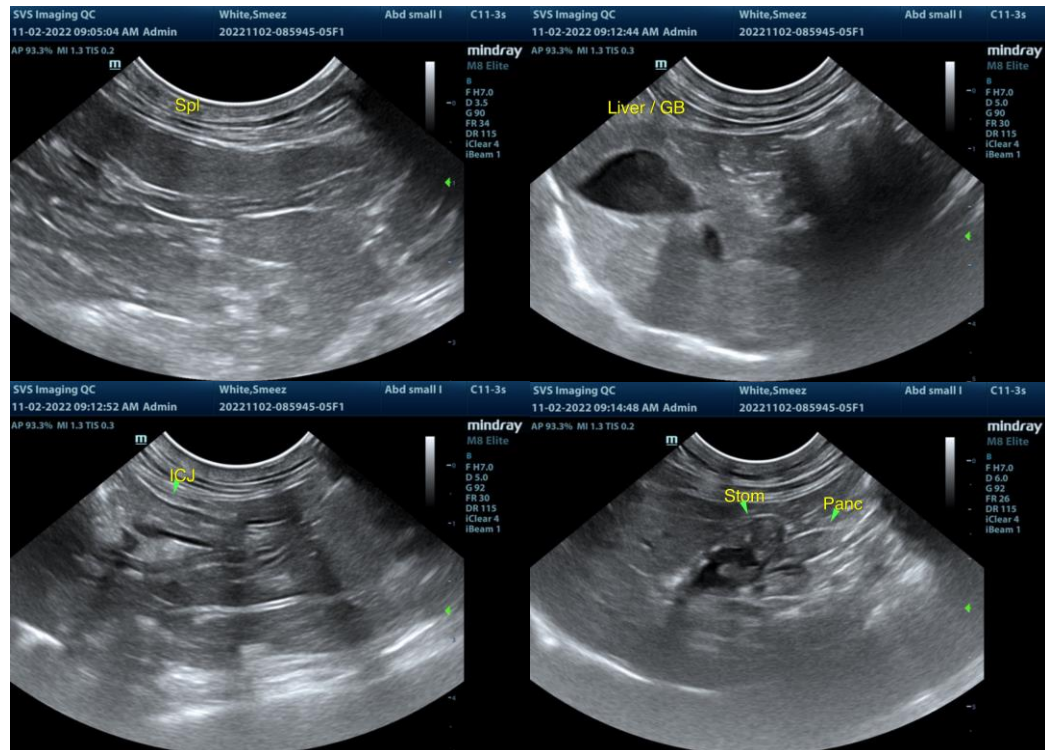
Dr. Westerhof

INVOICE

15332

DATE

11/2/22



IMAGING PERFORMED BY

svsmobileimaging.com 309-737-3070



Clinical Sonography & Telectyology

EDUCATIONAL TELECONSULTATION SERVICES™

1-800-838-4268 info@sonopath.com SonoPath.com

PATIENT

Smeez White

SPECIES

Feline

BREED

DSH

SEX

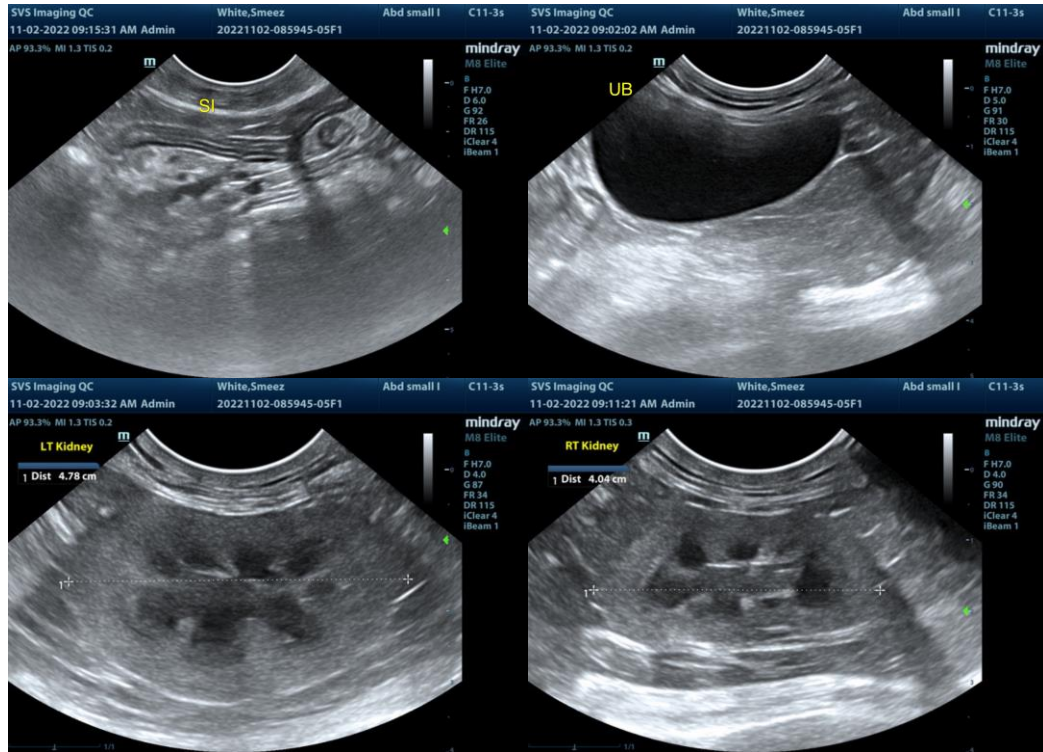
NM

AGE

12 years

WEIGHT

13 lbs.



INTERPRETED BY

R. McKenzie Daniel, DVM, DABVP (Canine and Feline)

IMAGING PERFORMED BY

Sarah Pender, CVT

HOSPITAL NAME

SVS Imaging QC

REFERRING VET

Dr. Westerhof

INVOICE

15332

DATE

11/2/22

The information and recommendations provided are based on the images presented by the referring veterinarian/sonographer. No evaluation can be communicated regarding pathology that was not visible in the image/video clips provided.

Thank you for this referral. If the clinical or image interpretation does not parallel your findings or if I can be of any further assistance please contact me.

R. McKenzie Daniel, DVM, DABVP (Canine / Feline Practice)
info@SonoPath.com