



PATIENT

Pete Iverson

SPECIES

Canine

BREED

Shepard Mix

SEX

MN

AGE

10

WEIGHT

76

INTERPRETED BY

R. McKenzie Daniel,
DVM, DABVP
(Canine and Feline)

IMAGING PERFORMED BY

Jenn

HOSPITAL NAME

Rockaway AH

REFERRING VET

Dr. Maniar

INVOICE

15318

DATE

11/2/22

PRESENTING CLINICAL SIGNS

Presented for echo but client reports dogs appetite is off, and is drinking excessively

ULTRASONOGRAPHIC EXAMINATION OF THE HEART & ABDOMEN

| CANINE | MR | TR | LA/AO | LA/AO | FS | EF | EPSS |
|---------------------------|----------------------|----------------------|---------------------|-------------------|------------------------------------|---------------------------------------|---------------------------------------|
| CARDIAC PARAMETERS | VMAX (m/s) | VMAX (m/s) | (Boon method) | (Heart Base; Swe) | (%) | (%) | (cm) |
| NORMAL PARAMETER | 4.5-5.5 | <2.7 | 1.3 | <1.3 | 28-40 | 40-100 | <0.6 |
| PATIENT | | | NM | 1.33 | 33 | 60 | 0.3 |
| CANINE | HR | AV | PV | BODY WEIGHT | LA | LVIDd | LVIDs |
| CARDIAC PARAMETERS | (BPM) | VMAX (m/s) | MAX (m/s) | (kg) | 2D short axis Base view (cm) | Avg; 2D and m-mode short axis (cm) | Avg; 2D and m-mode short axis (cm) |
| NORMAL PARAMETER | 50-100 | 0.7-1.7 | 0.7-1.6 | | | | |
| PATIENT | NM | 1.3 | 1.1 | | 3.9 | 3.6 | |

Cardiac Presentation

The echocardiogram in this patient demonstrated normal **left atrial** size based on 3 separate methods of LA evaluation. The cranial and caudal **mitral** valve leaflets presented normal linear structure, extension in systole, and union in diastole with normal kinesis. No overt MR was noted. The **left ventricle** presented thicknesses with linear contour and was not dilated nor restricted. The **myocardium** presented normal echogenicity without subjective evidence of significant fibrotic or ischemic disease. **Contractility** of the ventricular walls was adequate and in normal range for this patient evidenced by the fractional shortening measurement and subjective evaluation of the different regions of the myocardium. The **left ventricular outflow** tract demonstrated normal laminar flow and subjective structural integrity. Normal measured LVOT velocity was noted. The **right atrium** and auricle revealed normal size, structure and content. No evidence of masses was noted. **Tricuspid** valvular assessment demonstrated adequate linear morphology and kinesis. No overt TR was noted. The **right ventricle** was of normal size (1/3 diameter of LV), chordae structure, myocardial echogenicity and thickness. **Pulmonary outflow** tract assessment revealed normal valve structure, laminar flow, and diameter (approx. 1:1 pa/ao ratio). Normal measured RVOT velocity was noted. No visible **pericardial** or free pleura fluid was noted. The cranial **mediastinum and pericardial and extra-cardiac regions** were free of masses in the visible window. Possible arrhythmia was noted.

Urinary System

The urinary bladder, trigone, cystourethral junction, and visible pelvic urethra to a depth of 3.0 cm exhibited normal thickness and tone. Anechoic urine was present in the lumen with no uroliths or



| | |
|--|--|
| PATIENT | sediment. The ureteral papillae were normal. The ureters were not visible which is normal. No evidence of inflammatory or neoplastic changes was noted. |
| Pete Iverson | |
| SPECIES | The area of the aortic trifurcation was free of pathology. |
| Canine | Normal size and margination were present in the kidneys. A normal 1:3 cortex / medulla ratio and normal corticomedullary definition were maintained. The echogenicity of the cortex was similar to or slightly less than normal liver parenchyma while the medulla echogenicity was hypoechoic to the cortex with no evidence of pelvic dilation. The left kidney measured 7.1 cm in length. The right kidney measured 6.9 cm in length. |
| BREED | |
| Shepard Mix | |
| SEX | Adrenal Glands |
| MN | The bilateral adrenal glands were prominent in size with maintained symmetrical capsule contour and subtle nonhomogeneous yet nonmineralized parenchyma. The left adrenal gland measured 2.8 cm length x 1.0 cm width at the caudal pole. The right adrenal gland measured 2.8 cm length x 0.84 cm width at the caudal pole. |
| AGE | |
| 10 | |
| WEIGHT | Spleen |
| 76 | The spleen was normal in size and contour with generalized mild parenchymal heterogeneity and intermittent, discrete, non-disruptive, hypoechoic splenic nodules. Normal splenic vascularity was present. |
| INTERPRETED BY | Liver/ Gallbladder |
| R. McKenzie Daniel, DVM, DABVP (Canine and Feline) | The liver exhibited generalized enlargement with a symmetrical capsule contour. Mild generalized increased hepatic parenchyma echogenicity was present with multiple, variably sized, mild expansive, hypoechoic intraparenchymal nodules. An example measured 2.4 cm in diameter. The gallbladder was non-distended in size with thin walls and primarily anechoic luminal content. The cystic and common bile ducts were normal. |
| IMAGING PERFORMED BY | Gastrointestinal |
| Jenn | The stomach presented intact wall layering with a normal wall layer ratio. The lumen of the stomach was empty with no signs of ileus, obstruction, or foreign material. |
| HOSPITAL NAME | The small intestine presented intact wall layering with 1:3 muscularis/mucosa ratio. The lumen of the small intestine was empty with no signs of ileus, obstruction, or foreign material. |
| Rockaway AH | |
| REFERRING VET | Normal visible colon wall layers were present with apparent formed feces in lumen. |
| Dr. Maniar | |
| INVOICE | Pancreas |
| 15318 | The parenchyma of the left limb, body, and right limb of the pancreas presented isoechoic to the adjacent omental fat. A normal curvilinear capsule contour of the pancreas was present. The visible pancreatic duct was normal. No signs of active inflammation or neoplastic disease were evident. |
| DATE | Free Abdomen |
| 11/2/22 | No overt lymphadenopathy, omental masses, or peritoneal free fluid was present. |



PATIENT

Pete Iverson

SPECIES

Canine

BREED

Shepard Mix

SEX

MN

AGE

10

WEIGHT

76

ULTRASONOGRAPHIC FINDINGS

- Overtly normal cardiac structure and function
- Possible arrhythmia
- Hepatomegaly exhibiting multiple, variably sized to expansive, hypoechoic intraparenchymal nodules
- Intermittent concurrent discrete nondisruptive hypoechoic splenic nodules
- Bilateral prominent to nonhomogeneous adrenal glands

INTERPRETATION OF THE FINDINGS & FURTHER RECOMMENDATIONS

ECG assessment, given possible arrhythmia, is recommended. Considerations for the liver, including the intraparenchymal nodules, may include vacuolar hepatopathy, inflammatory / immune-mediated disease, nodular hyperplasia, hematopoiesis, granulomas, infiltrative neoplasia, or other hepatopathy.

Correlation with a full CBC/Chemistry panel is recommended. Full adrenal workup could be considered, given polydipsia, if concurrent clinical signs suggestive of adrenal hyperfunction are present. Screening hepatic parenchyma and nodule FNA cytology, if accessible, is suggested. Three-view chest radiographs are recommended if not done.

INTERPRETED BY

R. McKenzie Daniel,
DVM, DABVP
(Canine and Feline)

IMAGING PERFORMED BY

Jenn

HOSPITAL NAME

Rockaway AH

REFERRING VET

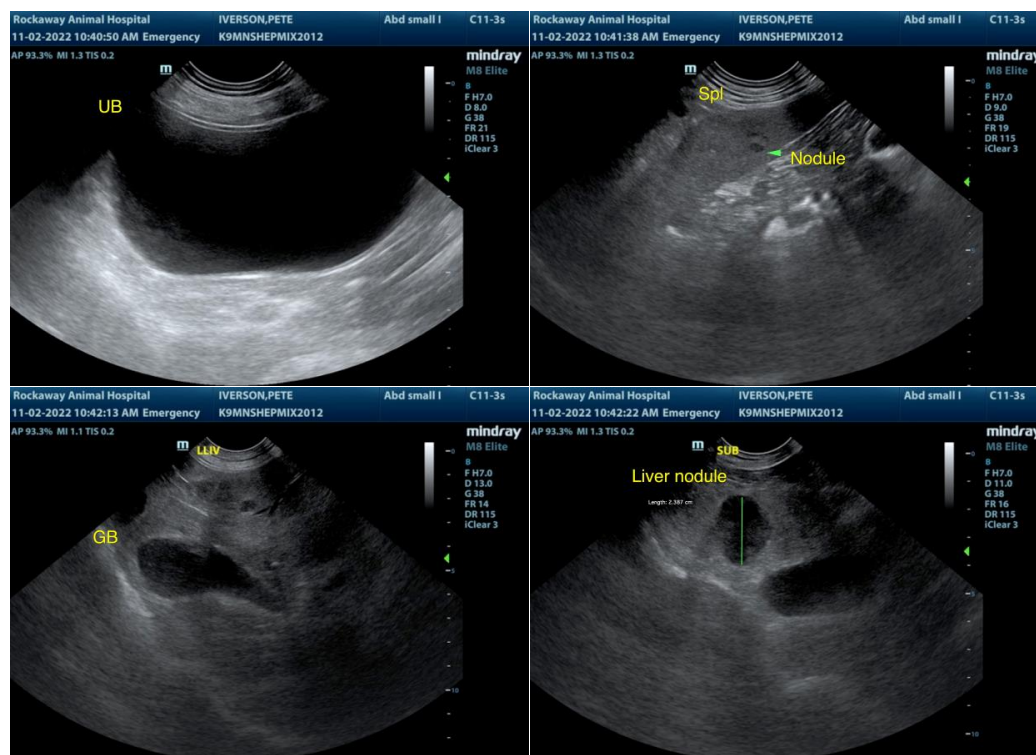
Dr. Maniar

INVOICE

15318

DATE

11/2/22





PATIENT

Pete Iverson

SPECIES

Canine

BREED

Shepard Mix

SEX

MN

AGE

10

WEIGHT

76

INTERPRETED BY

R. McKenzie Daniel,
DVM, DABVP
(Canine and Feline)

IMAGING PERFORMED BY

Jenn

HOSPITAL NAME

Rockaway AH

REFERRING VET

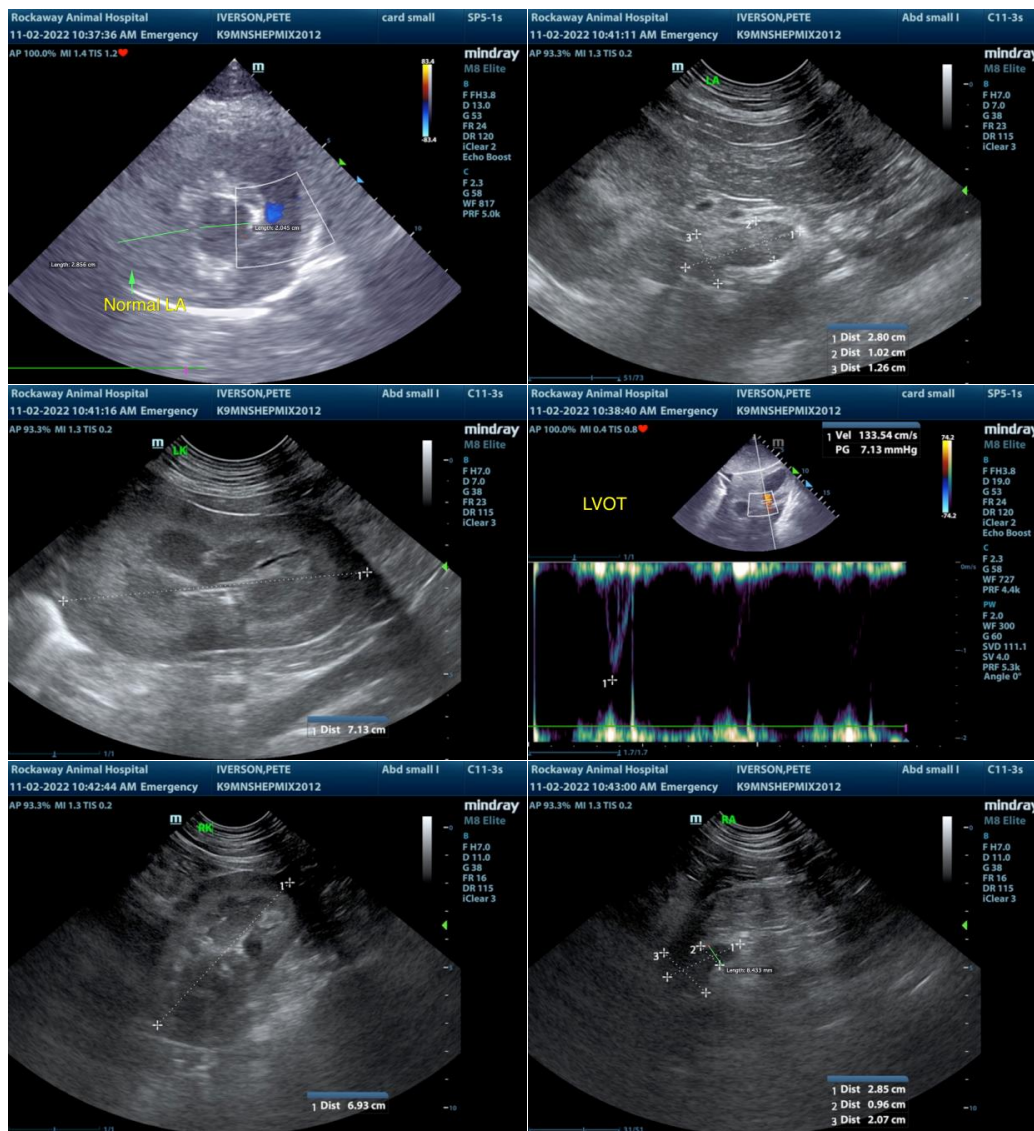
Dr. Maniar

INVOICE

15318

DATE

11/2/22



The information and recommendations provided are based on the images presented by the referring veterinarian/sonographer. No evaluation can be communicated regarding pathology that was not visible in the image/video clips provided.

Thank you for this referral. If the clinical or image interpretation does not parallel your findings or if I can be of any further assistance please contact me.

R. McKenzie Daniel, DVM, DABVP (Canine / Feline Practice)
info@SonoPath.com