



PATIENT

Elvira Chapman
Bond

SPECIES

Feline

BREED

Domestic
Mediumhair

SEX

SF

AGE

14 y

WEIGHT

8.06

INTERPRETED BY

R. McKenzie Daniel,
DVM, DABVP
(Canine and Feline)

IMAGING PERFORMED BY

Dr Matt Haghighat

HOSPITAL NAME

Beaches-
Fallingbrook VC

REFERRING VET

Dr Matt Haghighat

INVOICE

15343

DATE

11/2/22

PRESENTING CLINICAL SIGNS

Elvira is a 14 year old female spayed DMH that was presented initially 5 days ago with hyporexia. CBC, Chemistry and Urinalysis revealed mild elevation on ALT and ALP (ALT>ALP). On the examination she was bright, alert and responsive. She was eating better on Cyproheptadine, but still not eating as close as the normal amount. Main complaint; Hyporexia.

ULTRASONOGRAPHIC EXAMINATION OF THE ABDOMEN

Urinary System

The urinary bladder, trigone, cystourethral junction, and visible pelvic urethra to a depth of 2.0 cm exhibited normal thickness and tone. Anechoic urine was present in the lumen with no uroliths or sediment. The ureteral papillae were normal. The ureters were not visible which is normal. No evidence of inflammatory or neoplastic changes was noted.

The area of the aortic trifurcation was free of pathology.

Normal size and margination were present in the kidneys. A normal 1:3 cortex / medulla ratio was maintained. The medulla and cortices were uniform in texture with some increased echogenicity and mild to moderate loss of corticomedullary symmetry and definition expected for the age of the patient. No evidence of pelvic dilation was present. Cranial and caudal cortical infarcts were noted in the right kidney. The left kidney measured 3.4 cm in length. The right kidney measured 3.3 cm in length.

Adrenal Glands

The left adrenal gland was uniform in size and contour with a uniformly hypoechoic parenchyma. The left adrenal gland measured 0.32 cm width. The right adrenal gland was uniform in size and contour with a uniformly hypoechoic parenchyma. The right adrenal gland measured 0.40 cm width.

Spleen

The spleen exhibited primarily finely textured parenchyma which was hyperechoic to the liver and renal cortical parenchyma. Mild generalized parenchyma heterogeneity was present without evidence of nodular changes. The capsule was smooth and regular without apparent expansion. The splenic vasculature at the hilus was normal in volume with no evidence of congestion or thrombosis. The parenchymal heterogeneity is likely consistent with benign changes such as extramedullary hematopoiesis or age-related remodeling with minor potential for inflammatory or neoplastic disease. The spleen measured 0.77 cm width at the level of the hilus.

Liver/ Gallbladder

The liver exhibited borderline to possible mild enlargement with the ventral liver extending to the level of the gastric axis. The liver parenchyma was mildly nonuniform and hypoechoic to the spleen with a moderate coarse echotexture and subjective mild to benign parenchymal remodeling. The hepatic and portal vasculature were normal in appearance without signs of congestion. The gallbladder was non-distended in size containing primarily anechoic luminal content with mild, nondependent, particulate to echogenic nonorganized luminal debris. A focal area of scant, pericholecystic, free fluid was noted. No evidence of gallbladder or peripheral gallbladder inflammatory criteria was noted. The cystic and common bile ducts were normal.



PATIENT

Elvira Chapman
Bond

SPECIES

Feline

BREED

Domestic
Mediumhair

SEX

SF

AGE

14 y

WEIGHT

8.06

INTERPRETED BY

R. McKenzie Daniel,
DVM, DABVP
(Canine and Feline)

**IMAGING
PERFORMED BY**

Dr Matt Haghigat

HOSPITAL NAME

Beaches-
Fallingbrook VC

REFERRING VET

Dr Matt Haghigat

INVOICE

15343

DATE

11/2/22

Gastrointestinal

The stomach presented intact wall layering with a normal wall layer ratio. The lumen of the stomach was empty with no signs of ileus, obstruction, or foreign material. The gastric body wall width measured 0.27 cm.

The small intestine presented intact wall layering and primarily maintained 1:3 muscularis/mucosa ratio. Segmental prominent small bowel walls with subjective propensity for mildly prominent muscularis layer were present in the subjective segmental jejunum. The duodenum wall measured up to 0.27 cm width.

Normal visible colon wall layers were present with apparent formed feces in lumen.

Pancreas

The pancreas was normal in size and contour with isoechoic to heterogeneous parenchyma compared to adjacent omentum. No signs of active inflammation or neoplasia. Minor pancreatic duct dilation was noted.

Free Abdomen

No evidence of significant lymphadenopathy or omental masses were present. Normal uniform omental echogenicity was present.

ULTRASONOGRAPHIC FINDINGS

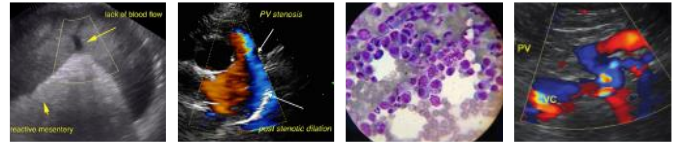
- Chronic renal changes with right kidney cortical infarcts
- Hepatopathy - subjectively benign, suspicion for cholangitis / cholangiohepatitis, potential for vacuolar hepatopathy, emerging cholestasis or other hepatopathy with Infiltrative neoplasia considered an unlikely differential diagnosis
- Mild gallbladder debris
- Heterogeneous pancreas - age-related / patient variant, minor remodeling owing to previous or chronic inflammation possible
- Intact yet segmental subjective mild prominent small intestinal walls

INTERPRETATION OF THE FINDINGS & FURTHER RECOMMENDATIONS

Although potential for patient variant, the segmental subjective intact yet prominent small bowel walls may suggest underlying inflammatory criteria. Assuming normal clotting status screening hepatic FNA cytology is warranted for further assessment primarily to assess for or identify inflammatory cell type if present. Triad Disease may be a potential in this patient, especially if weight loss or progressive GI signs going forward are noted and pending hepatic cytology. Further assessment may include a GI panel to include PLI/TLI/Cobalamin/Folate.

Further renal staging to include urine C/S and protein: creatinine ratio on sterile urine sample may be considered.

Empirically, as-needed GI and hepatic support would be reasonable.



PATIENT

Elvira Chapman
Bond

SPECIES

Feline

BREED

Domestic
Mediumhair

SEX

SF

AGE

14 y

WEIGHT

8.06

INTERPRETED BY

R. McKenzie Daniel,
DVM, DABVP
(Canine and Feline)

IMAGING PERFORMED BY

Dr Matt Haghighat

HOSPITAL NAME

Beaches-
Fallingbrook VC

REFERRING VET

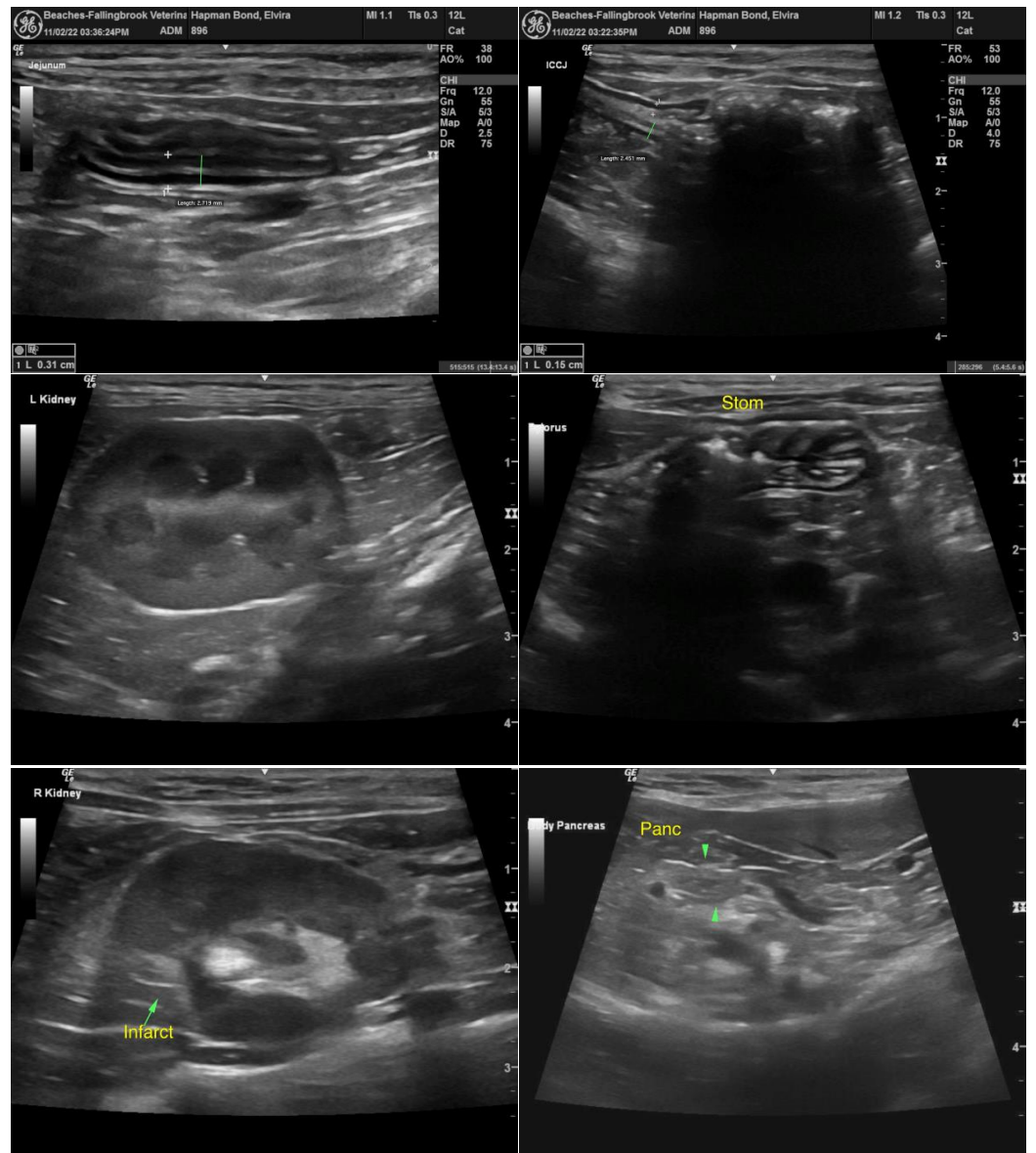
Dr Matt Haghighat

INVOICE

15343

DATE

11/2/22





PATIENT

Elvira Chapman
Bond

SPECIES

Feline

BREED

Domestic
Mediumhair

SEX

SF

AGE

14 y

WEIGHT

8.06

INTERPRETED BY

R. McKenzie Daniel,
DVM, DABVP
(Canine and Feline)

IMAGING PERFORMED BY

Dr Matt Haghighat

HOSPITAL NAME

Beaches-
Fallingbrook VC

REFERRING VET

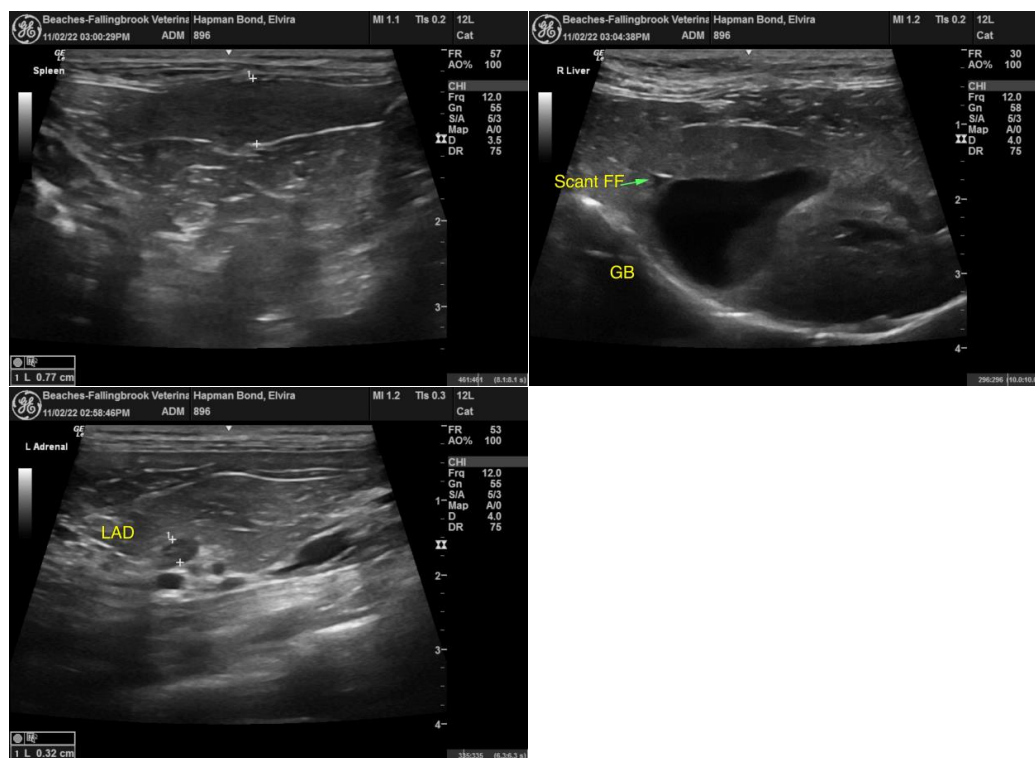
Dr Matt Haghighat

INVOICE

15343

DATE

11/2/22



The information and recommendations provided are based on the images presented by the referring veterinarian/sonographer. No evaluation can be communicated regarding pathology that was not visible in the image/video clips provided.

Thank you for this referral. If the clinical or image interpretation does not parallel your findings or if I can be of any further assistance please contact me.

R. McKenzie Daniel, DVM, DABVP (Canine / Feline Practice)
info@SonoPath.com