



**PATIENT**

Jasmine Schwartz

**PRESENTING CLINICAL SIGNS**

Previously noted heart murmur low grade and not clinical about 1 year ago. Recently presented for a dental cleaning and noted a 3-4/6 grade heart murmur. Are there any anesthesia restrictions for dental?

**SPECIES**

Canine

**ULTRASONOGRAPHIC EXAMINATION OF THE HEART**

**BREED**

Shih Tzu X

**SEX**

Spayed Female

**AGE**

10 Years

**WEIGHT**

21.9 Pounds

CANINE CARDIAC PARAMETERS	MR VMAX (m/s)	TR VMAX (m/s)	LA/AO (Boon method)	LA/AO (Heart Base; Swe)	FS (%)	EF (%)	EPSS (cm)
NORMAL PARAMETER	4.5-5.5	<2.7	1.3	<1.6	28-40	40-100	<0.6
PATIENT	5.2	1.5	NM	1.46	43	76.3	0.25
CANINE CARDIAC PARAMETERS	HR (BPM)	AV VMAX (m/s)	PV MAX (m/s)	BODY WEIGHT (kg)	LA 2D short axis Base view (cm)	LVIDd Avg; 2D and m-mode short axis (cm)	LVIDs Avg; 2D and m-mode short axis (cm)
NORMAL PARAMETER	50-100	0.7-1.7	0.7-1.6				
PATIENT	130	1.5	0.8		2.7	2.51	

**Cardiac Presentation**

The echocardiogram in this patient demonstrated normal **left atrial** size based on 3 different LA measurement methods. Chamber volumes and echogenicity were normal. The cranial and caudal **mitral** valve leaflets presented vegetative thickening consistent with endocardiosis. Doppler indicated measurable insufficiency. The **left ventricle** presented thicknesses with linear contour and was not dilated nor restricted. The **myocardium** presented normal echogenicity without subjective evidence of significant fibrotic or ischemic disease. **Contractility** of the ventricular walls was adequate and in normal range for this patient evidenced by the fractional shortening measurement and subjective evaluation of the different regions of the myocardium. The **left ventricular outflow** tract demonstrated normal laminar flow and subjective structural integrity. The **right atrium** and auricle revealed normal size, structure and content. No evidence of masses was noted or chamber overload. **Tricuspid** valvular assessment demonstrated adequate linear morphology. The **right ventricle** was of normal size (1/3 diameter of LV), chordae structure, myocardial echogenicity and thickness. **Pulmonic** tract assessment revealed normal valve structure, laminar flow, and diameter (approx. 1:1 pa/ao ratio). No visible **pericardial** or free pleura fluid was noted. No echographically detectable evidence of infiltrative disease was visible. The cranial **mediastinum** and **pericardial** regions were free of masses in the visible window.

**ULTRASONOGRAPHIC FINDINGS**

- Chronic mitral valve disease (ACVIM B1)
- Mild tricuspid valve insufficiency

**INTERPRETATION OF THE FINDINGS & FURTHER RECOMMENDATIONS**

The cause of the murmur is chronic degenerative valvular changes with secondary eccentric mitral valve insufficiency. The lack of left atrial enlargement implies that the risk of complication secondary to mitral valve insufficiency is low at this time, although prognosis is highly variable. Without current clinical

**INTERPRETED BY**

R. McKenzie Daniel,  
DVM, DABVP  
(Canine and Feline)

**IMAGING PERFORMED BY**

Kim Liedberg

**HOSPITAL NAME**

SVS Imaging WI

**REFERRING VET**

Dr. Miller

**INVOICE**

26772

**DATE**

11/2/21



**PATIENT**

Jasmine Schwartz

**SPECIES**

Canine

**BREED**

Shih Tzu X

**SEX**

Spayed Female

**AGE**

10 Years

**WEIGHT**

21.9 Pounds

**INTERPRETED BY**

R. McKenzie Daniel, DVM, DABVP (Canine and Feline)

**IMAGING PERFORMED BY**

Kim Liedberg

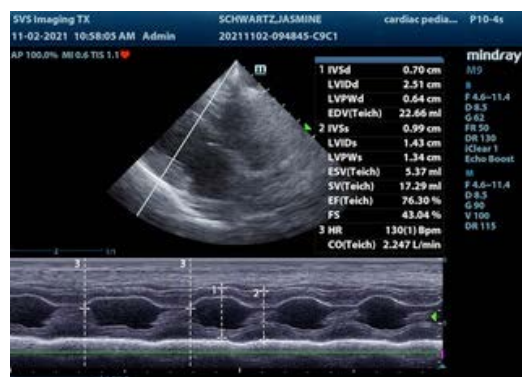
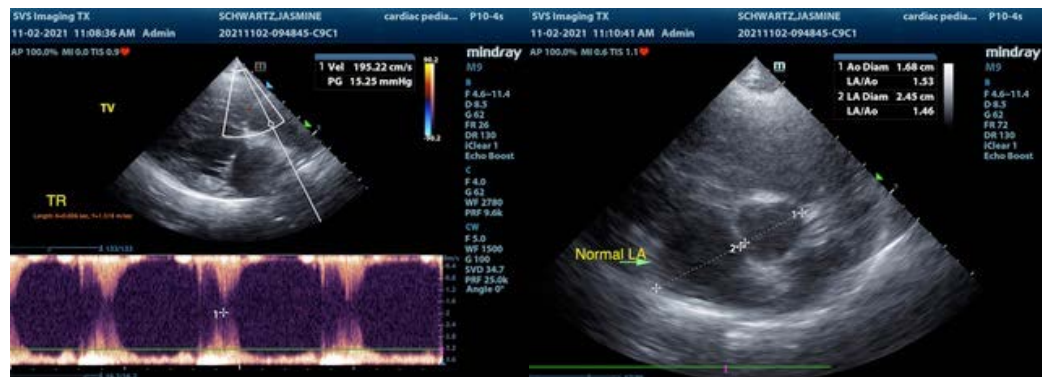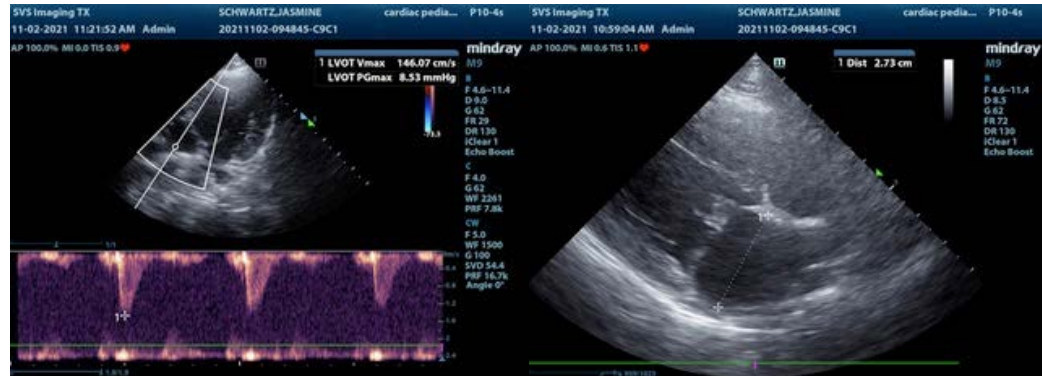
**HOSPITAL NAME**

SVS Imaging WI

**REFERRING VET**

Dr. Miller

signs, no indication for medical therapy at this time. No other clinical issues such as systolic dysfunction or evidence of clinical pulmonary hypertension noted. Conservative monitoring is recommended with a recheck echocardiogram in 6-12 months, sooner if clinical signs suggestive of heart disease develop. No overt anesthetic contraindications. Suggested anesthetic protocol may include opioid or Benzodiazepine pre-med, induction with Propofol or Alfaxalone, and appropriate gas anesthesia with avoidance of alpha 2 agonists.



**INVOICE**

26772

**DATE**

11/2/21

The information and recommendations provided are based on the images presented by the referring veterinarian. No evaluation can be communicated regarding pathology that was not visible in the image/video clips provided.

Thank you for this referral. If the clinical or image interpretation does not parallel your findings or if I can be of any further assistance please contact me.

R. McKenzie Daniel, DVM, DABVP (Canine / Feline Practice)  
info@SonoPath.com