



PATIENT PRESENTING CLINICAL SIGNS

Glory Cheatham History: Elevated liver values, leaking urine, concern for neoplasia
Medication: Hepatobenefits

SPECIES ALP not read, ALT 296, GGT 12, Lipase 5480, unremarkable CBC.

Canine

ULTRASONOGRAPHIC EXAMINATION OF THE ABDOMEN

BREED

German Shepherd

Urinary System

The urinary bladder, trigone, cystourethral junction, and visible pelvic urethra to a depth of 5.0 cm exhibited normal thickness and tone. Anechoic urine was present in the lumen with no uroliths or sediment. The ureteral papillae were normal. The ureters were not visible which is normal. No evidence of inflammatory or neoplastic changes were noted.

SEX

Neutered Male

The residual prostate was symmetrically normal in size with uniform parenchyma and slight coarse echotexture. The prostate measured 1.0 cm diameter.

AGE

12 years

The area of the aortic trifurcation was free of pathology.

Normal size and margination were present in the kidneys. A normal 1:3 cortex / medulla ratio was maintained. The medulla and cortices were uniform in texture with some increased echogenicity and loss of corticomedullary symmetry and definition expected for the age of the patient. No evidence of pelvic dilation was present. The right kidney measured 6.2 cm. The left kidney measured 7.5 cm.

WEIGHT

71 Pounds

Adrenal Glands

The adrenal glands were uniform in size and contour with a uniformly hypoechoic parenchyma. The right adrenal gland measured 3.3 cm length x 0.84 cm at the caudal pole. The left adrenal gland measured 3.1 cm length x 0.78 cm at the caudal pole.

INTERPRETED BY

R. McKenzie Daniel,
DVM, DABVP
(Canine and Feline)

Spleen

The spleen exhibited subjective mild generalized enlargement with primarily finely textured parenchyma which was hyperechoic to the liver and renal cortical parenchyma. Mild generalized parenchyma heterogeneity was present without evidence of nodular changes. The capsule was smooth and regular without apparent expansion. The splenic vasculature at the hilus was normal in volume with no evidence of congestion or thrombosis. The parenchymal heterogeneity is likely consistent with benign changes such as extramedullary hematopoiesis or age related remodeling with minor potential for inflammatory or neoplastic disease.

IMAGING PERFORMED BY

Rebekah Jakum, CVT
ARDMS/RVT

HOSPITAL NAME

Pocono Peak VC

Liver

The liver exhibited generalized enlargement. The liver parenchyma was mildly nonuniform and hypoechoic to the spleen with a moderate coarse echotexture and subjective mild to benign parenchymal remodeling. A moderately sized, non-homogeneous to potentially cystic mass lesion was noted in the mid caudal liver, measuring 5.5-6.0 m in diameter. The hepatic and portal vasculature were normal in appearance without signs of congestion. The gallbladder was non distended in size with mild, echogenic, nonmineralized biliary sludge. No evidence of gallbladder or peripheral inflammation. The cystic duct and common bile ducts were normal without evidence of dilation.

REFERRING VET

Dr. Coyle

INVOICE

26770

DATE

11.2.2021

Gastrointestinal



PATIENT Glory Cheatham
The lumen of the stomach contained mild to moderate retained echogenic ingesta and chyme. Intact yet subjective prominent gastric walls were present. No overt evidence of gastric foreign material or mechanical pyloric outflow obstruction. Gastric body wall measured 0.53 cm.

SPECIES
The small intestine presented intact wall layering with 1:3 muscularis/mucosa ratio. The lumen of the small intestine was empty with no signs of ileus, obstruction or foreign material.

Canine
Normal visible colon wall layers were present with apparent formed feces in lumen.

Pancreas

BREED

German Shepherd
The pancreas was normal in size and contour with isoechoic to heterogeneous parenchyma compared to adjacent omentum. No signs of active inflammation or neoplasia.

SEX *Free Abdomen*

Neutered Male
Generalized cranial abdominal (primarily perihepatic to perigastric) echogenic mesentery was noted, suggestive of mesenteric reactivity.

AGE **ULTRASONOGRAPHIC FINDINGS**

- 12 years
- Generalized hepatomegaly with mid caudal non-homogeneous mass lesion
 - Gastric ingesta with potential gastritis
 - Cranial abdominal, primarily perihepatic and perigastric reactive mesentery
 - Sonographically unremarkable urinary bladder, residual prostate and visible proximal urethra
 - Mild age related kidneys
 - Possible mild splenomegaly – subjectively benign

WEIGHT

71 Pounds

INTERPRETATION OF THE FINDINGS & FURTHER RECOMMENDATIONS

Considerations for the mid caudal hepatic mass lesion as well as the overall generalized hepatomegaly may include vacuolar or inflammatory hepatopathy with minor parenchymal remodeling, mid caudal nodular hyperplasia, hematopoiesis, non-homogeneous granuloma, neoplasia, or other. Given the presence of the mid caudal mass lesion, neoplasia is favored, although not definitive. Further assessment may include screening cytology obtained without complication during the ultrasound. Some degree of gastric hypomotility may be present if documented NPO. The addition of Ursodiol to current hepatosupportive medication may prove beneficial.

INTERPRETED BY

R. McKenzie Daniel,
DVM, DABVP
(Canine and Feline)

IMAGING PERFORMED BY

Rebekah Jakum, CVT
ARDMS/RVT

HOSPITAL NAME

Pocono Peak VC

REFERRING VET

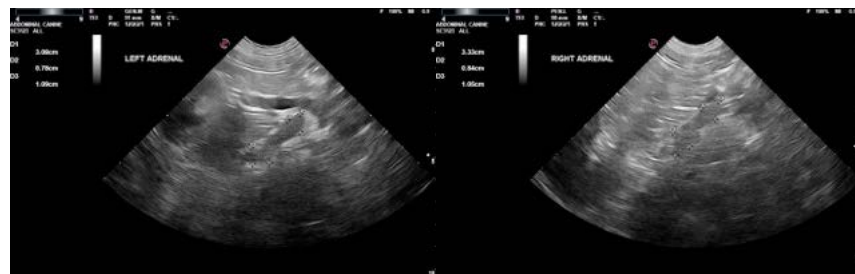Dr. Coyle

INVOICE

26770

DATE

11.2.2021





PATIENT

Glory Cheatham

SPECIES

Canine

BREED

German Shepherd

SEX

Neutered Male

AGE

12 years

WEIGHT

71 Pounds

INTERPRETED BY

R. McKenzie Daniel,
DVM, DABVP
(Canine and Feline)

IMAGING PERFORMED BY

Rebekah Jakum, CVT
ARDMS/RVT

HOSPITAL NAME

Pocono Peak VC

REFERRING VET

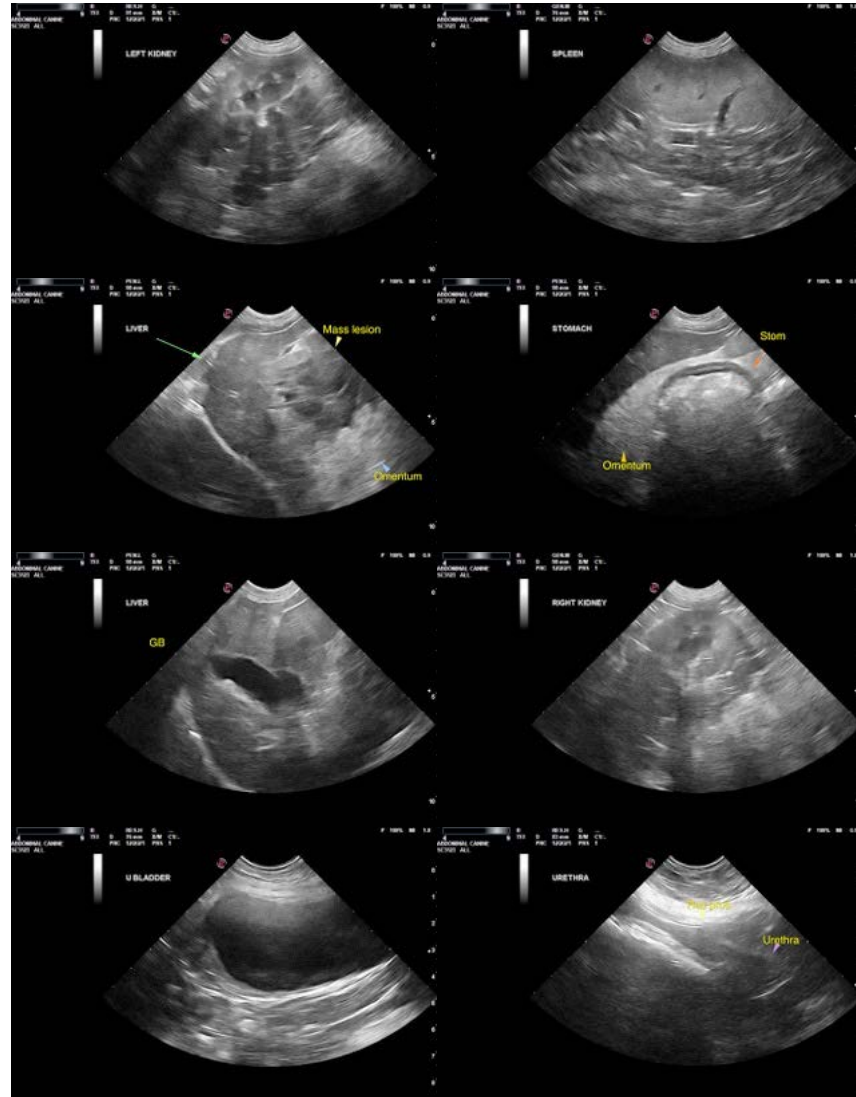
Dr. Coyle

INVOICE

26770

DATE

11.2.2021



The information and recommendations provided are based on the images presented by the referring veterinarian. No evaluation can be communicated regarding pathology that was not visible in the image/video clips provided.

Thank you for this referral. If the clinical or image interpretation does not parallel your findings or if I can be of any further assistance please contact me.

R. McKenzie Daniel, DVM, DABVP (Canine/Feline Practice)
mac.daniel@sonopath.com