



PATIENT

Oliva Rivera

SPECIES

Canine

BREED

Mixed

SEX

Spayed Female

AGE

12 Years

WEIGHT

56.2 pounds

INTERPRETED BY

R. McKenzie Daniel,
DVM, DABVP

IMAGING PERFORMED BY

Dr. Gabriel Ferrer
DVM

HOSPITAL NAME

Pulse Pet Ultrasound
Services

REFERRING VET

Dra. Sonia Cajigas

INVOICE

12327

DATE

11/19/25

PRESENTING CLINICAL SIGNS

Presented as a referral for a neck ultrasound. During PE a mass was palpated on the neck region mostly on right side. Recommended ultrasound and FNA of the mass to further evaluate.

Abnormal PE/Chem/CBC/UA Results: PE: Mass palpated on thyroid area bilateral, but mostly on right neck region. FNA of the right and left mass were done pending cytology results.

ULTRASONOGRAPHIC EXAMINATION OF THE NECK

The left and right thyroid lobes were enlarged in size with the right thyroid lobe larger than the left thyroid lobe. Both enlarged thyroid lobes exhibited nonhomogenous parenchyma with subjective small fluid cavitations. Color doppler assessment of the enlarged left and right thyroid lobe exhibited subjective moderate vascularity. The enlarged right thyroid lobe measured 6.0 cm x 4.0 cm. The enlarged left thyroid lobe measured 3.0 cm x 2.6 cm.

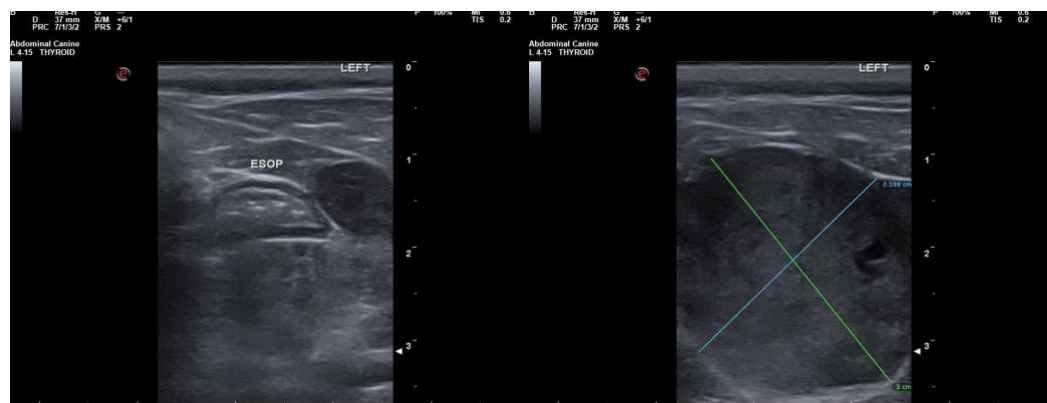
The visualized trachea and esophagus were sonographically normal.

ULTRASONOGRAPHIC FINDINGS

- Bilateral thyroid lobe masses- enlarged right thyroid lobe mass compared to the left thyroid lobe mass.

INTERPRETATION OF THE FINDINGS & FURTHER RECOMMENDATIONS

Although pending sampling is required for further clarification, the bilateral thyroid lobe masses are consistent with neoplastic criteria with considerations including carcinoma, adenocarcinoma, adenoma or mixed pathology. Correlation with cytology and T4 level is recommended. Cervical CT could be considered for further clarification and extent of thyroid lobe pathology or if surgery/oncology consultation is a potential.





PATIENT

Oliva Rivera

SPECIES

Canine

BREED

Mixed

SEX

Spayed Female

AGE

12 Years

WEIGHT

56.2 pounds

INTERPRETED BY

R. McKenzie Daniel,
DVM, DABVP

IMAGING PERFORMED BY

Dr. Gabriel Ferrer
DVM

HOSPITAL NAME

Pulse Pet Ultrasound
Services

REFERRING VET

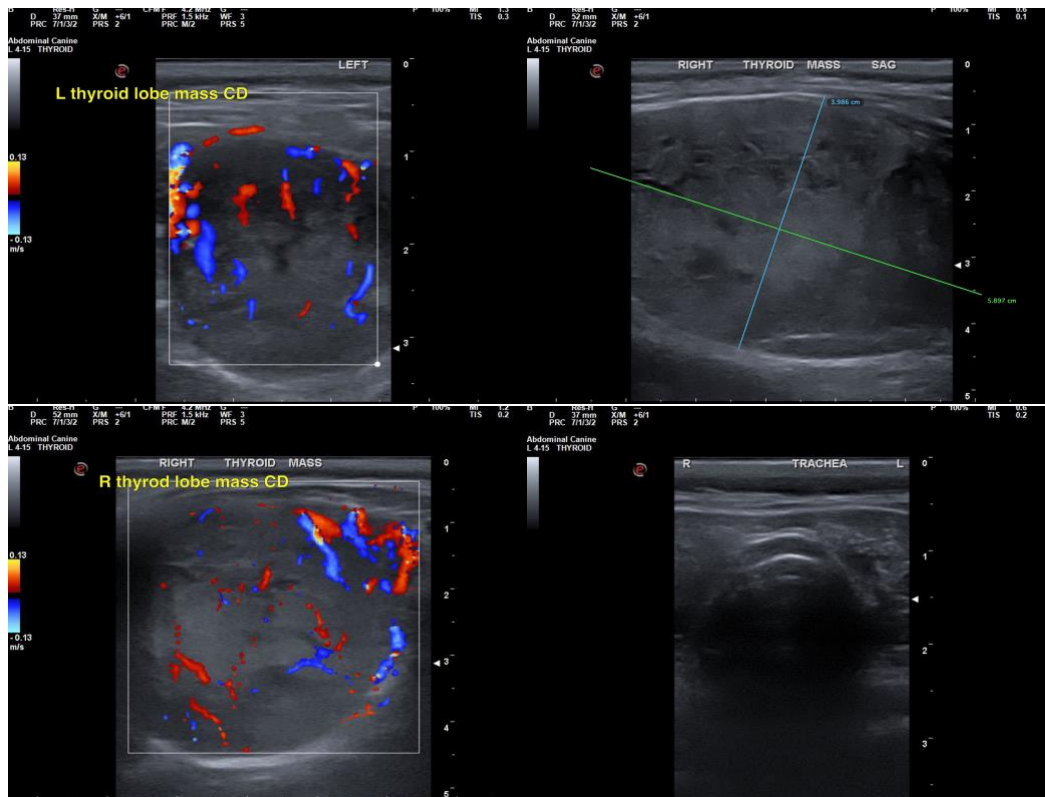
Dra. Sonia Cajigas

INVOICE

12327

DATE

11/19/25



The information and recommendations provided are based on the images presented by the referring veterinarian/sonographer. No evaluation can be communicated regarding pathology that was not visible in the image/video clips provided.

Thank you for this referral. If the clinical or image interpretation does not parallel your findings or if I can be of any further assistance, please contact me.

R. McKenzie Daniel, DVM, DABVP (Canine / Feline Practice)

info@SonoPath.com