

PATIENT

Finnigan Cummings

SPECIES

Feline

BREED

DSH

SEX

Neutered Male

AGE

2021

WEIGHT

10.2

INTERPRETED BY

R. McKenzie Daniel,
DVM, DABVP (Canine
/ Feline Practice)

**IMAGING
PERFORMED BY**

Rebekah Jakum, CVT,
ARDMS/RVT

HOSPITAL NAME

Creekview Veterinary
Hospital

REFERRING VET

Dr. Ballek

INVOICE

12334

DATE

11/19/25

PRESENTING CLINICAL SIGNS

3 day duration decreased appetite, projectile vomiting, weight loss

ULTRASONOGRAPHIC EXAMINATION OF THE ABDOMEN

Urinary System

The urinary bladder, trigone, cystourethral junction, and visible pelvic urethra to a depth of 3.0 cm exhibited normal thickness and tone. Primarily anechoic urine was present in the lumen. Dependent to nondependent particulate to pinpoint hyperechoic mild to moderate sediment was present without evidence of calculus formation. The ureteral papillae were normal. The ureters were not visible which is normal. No evidence of inflammatory or neoplastic mural changes were noted.

Adequate to borderline prominent size and primarily symmetrical margination was present in the kidneys. A normal 1:3 cortex / medulla ratio and mild uniform hyperechoic cortex with enhanced corticomedullary border demarcation. No evidence of pelvic dilation. The left kidney measured 4.4 cm in length. The right kidney measured 4.6 cm in length.

Adrenal Glands

The left adrenal gland was uniform in size and contour with a uniformly hypoechoic parenchyma. The left adrenal gland measured 0.49 cm width. The right adrenal gland was uniform in size and contour with a uniformly hypoechoic parenchyma. The right adrenal gland measured 0.46 cm width.

Spleen

The spleen exhibited a finely textured and homogenous parenchyma which was hyperechoic to the liver and renal cortical parenchyma. The capsule was smooth and regular without apparent expansion. The splenic vasculature at the hilus was normal in volume with no evidence of congestion or thrombosis. Acute to chronic inflammatory, neoplastic, or benign parenchyma changes were not noted.

Liver

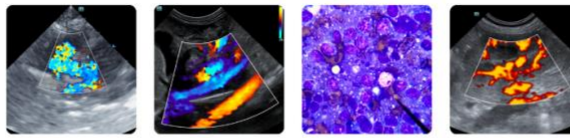
The liver was subjectively normal in size, structure, and contour. The liver parenchyma was uniform and hypoechoic to the spleen with a mild coarse echotexture. The hepatic and portal vasculature were normal in appearance without signs of congestion.

The gallbladder was non-distended in size with thin walls and primarily anechoic luminal content. The common bile duct was dilated and mild to moderate tortuous extending from the cystic duct towards the level of the duodenum. Common bile duct dilation measured 0.35 cm. The dilated common bile duct contained anechoic content.

Gastrointestinal

The stomach presented with normal intact wall layering. The stomach exhibited moderate distention with retained primarily nonshadowing ingesta/chyme. No evidence of obstruction to the pyloric outflow.

A segmental irregular to variably thickened small intestine mass was visualized in the mid to right cranial abdomen. The mass exhibited variable thickened hypoechoic wall and loss of mural detail potentially measuring approximately 4.0 cm in length with wall thickness measuring 0.60 cm. Retained



PATIENT

Finnigan Cummings

SPECIES

Feline

BREED

DSH

SEX

Neutered Male

AGE

2021

WEIGHT

10.2

INTERPRETED BY

R. McKenzie Daniel,
 DVM, DABVP (Canine
 / Feline Practice)

IMAGING PERFORMED BY

Rebekah Jakum, CVT,
 ARDMS/RVT

HOSPITAL NAME

Creekview Veterinary
 Hospital

REFERRING VET

Dr. Ballek

INVOICE

12334

DATE

11/19/25

generally mild nonshadowing ingesta/chyme in proximal intestinal segments and subjective duodenum. Nonshadowing content within the lumen of the intestine mass. Primarily empty small intestinal segments exhibiting intact wall layering and maintained wall layer ratio, subjectively distal. Intact duodenum wall measured 0.25 cm wall width. Intact distal small intestine wall measured 0.22 cm wall width.

Normal visible colon wall layers were present with formed to semi formed fecal matter and lumen gas.

Pancreas

The area of the pancreas was sonographically normal.

Free Abdomen

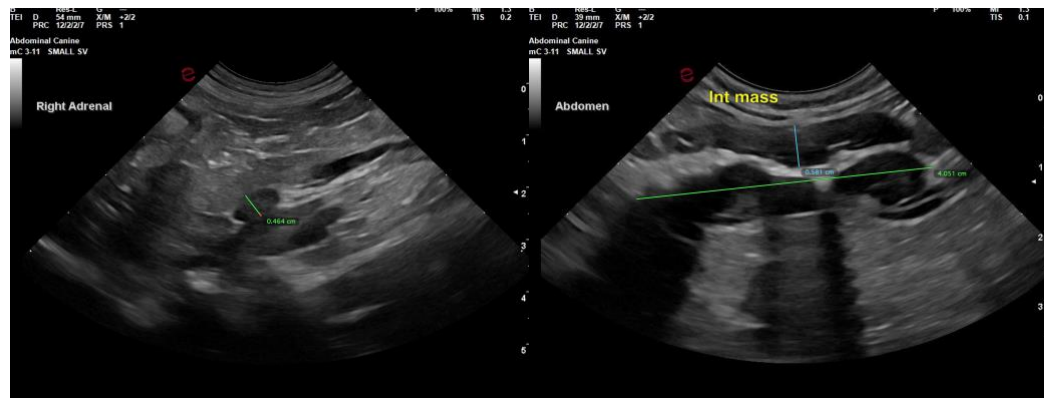
Intermittent hypoechoic to swollen homogenous mesenteric lymph nodes were visualized adjacent to the intestine mass with an example measuring 1.7 cm x 1.0 cm. Mild associated regional peri-intestinal hyperechoic omentum. No evidence of peritoneal effusion was present.

ULTRASONOGRAPHIC FINDINGS

- Intestinal mass- subjectively involving the duodenum and potential upper jejunum.
- Retained gastric and segmental duodenal nonshadowing ingesta, primarily empty sonographically normal visualized small intestinal segments likely distal.
- Associated hypoechoic to swollen mesenteric lymphadenopathy and mild peri-intestinal hyperechoic omentum.
- Primarily diffuse mild to moderate common bile duct dilation- concurrent cholangitis, potential for emerging posthepatic obstruction possible.

INTERPRETATION OF THE FINDINGS & FURTHER RECOMMENDATIONS

Assuming normal clotting status and using a 25-gauge needle, intestinal mass wall and adjacent lymph node FNA cytology could be considered for further clarification and potential for oncology and/or surgical consult. No overt evidence of hepatosplenic primary or metastatic neoplastic criteria. Three view chest radiographs are recommended.





PATIENT

Finnigan Cummings

SPECIES

Feline

BREED

DSH

SEX

Neutered Male

AGE

2021

WEIGHT

10.2

INTERPRETED BY

R. McKenzie Daniel,
 DVM, DABVP (Canine
 / Feline Practice)

**IMAGING
 PERFORMED BY**

Rebekah Jakum, CVT,
 ARDMS/RVT

HOSPITAL NAME

Creekview Veterinary
 Hospital

REFERRING VET

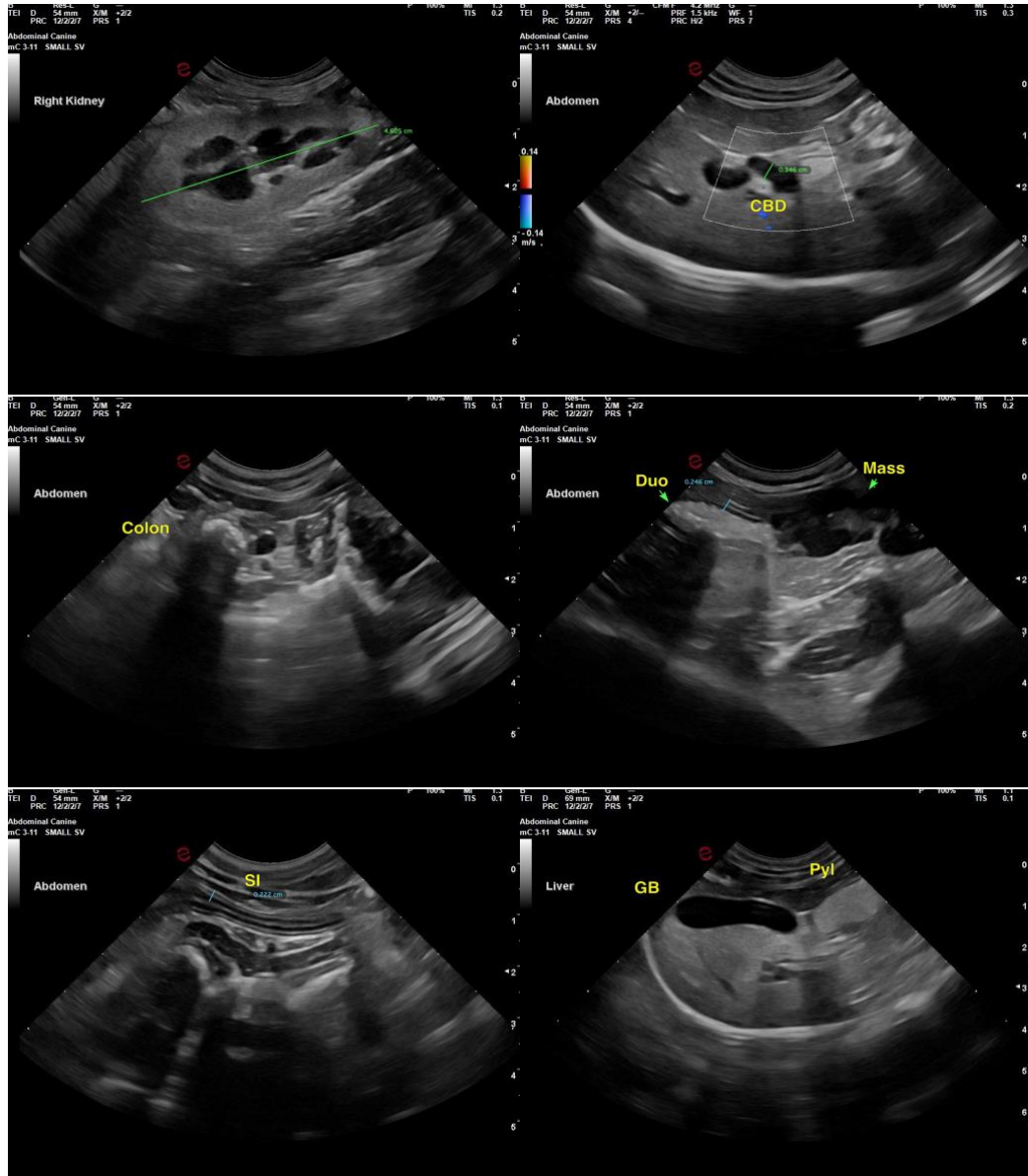
Dr. Ballek

INVOICE

12334

DATE

11/19/25





PATIENT

Finnigan Cummings

SPECIES

Feline

BREED

DSH

SEX

Neutered Male

AGE

2021

WEIGHT

10.2

INTERPRETED BY

R. McKenzie Daniel,
 DVM, DABVP (Canine
 / Feline Practice)

IMAGING PERFORMED BY

Rebekah Jakum, CVT,
 ARDMS/RVT

HOSPITAL NAME

Creekview Veterinary
 Hospital

REFERRING VET

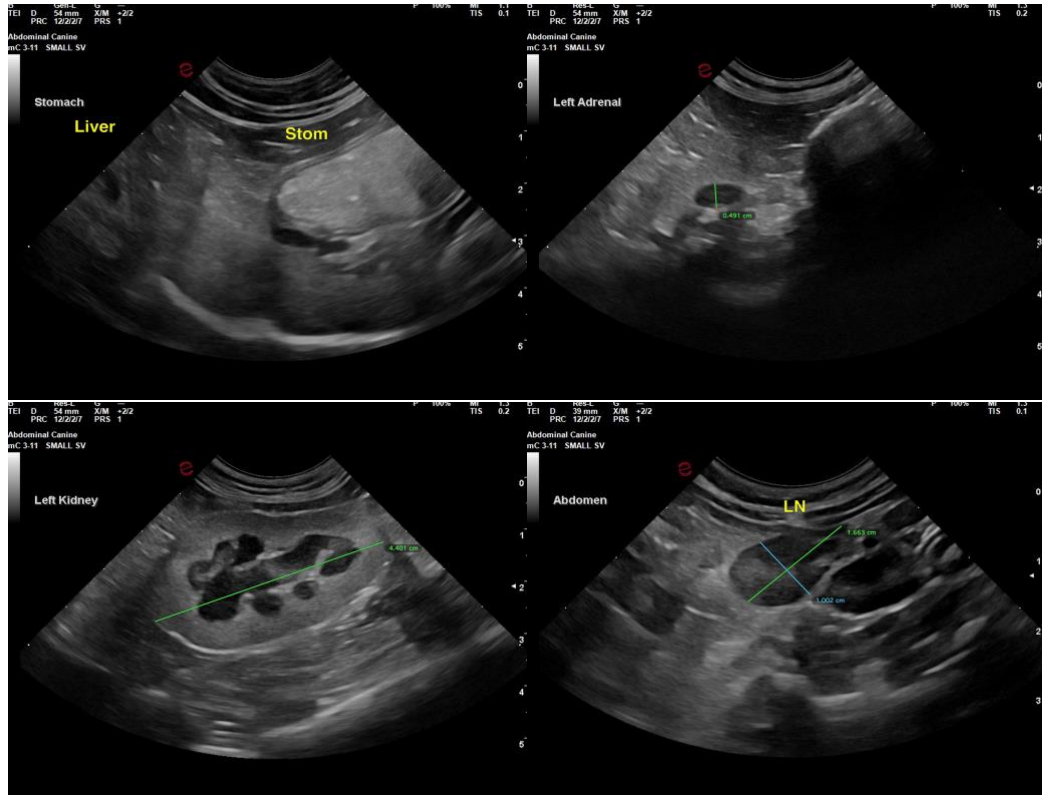
Dr. Ballek

INVOICE

12334

DATE

11/19/25



The information and recommendations provided are based on the images presented by the referring veterinarian/sonographer. No evaluation can be communicated regarding pathology that was not visible in the image/video clips provided.

Thank you for this referral. If the clinical or image interpretation does not parallel your findings or if I can be of any further assistance, please contact me.

R. McKenzie Daniel, DVM, DABVP (Canine / Feline Practice)

info@SonoPath.com