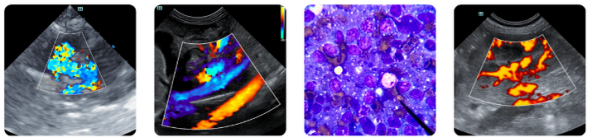

PATIENT
Cheetah Gudoski

SPECIES
Feline

BREED
DSH

SEX
Female Spayed

AGE
15y

WEIGHT
6.8 lbs

INTERPRETED BY
R. McKenzie Daniel, DVM, DABVP (Canine and Feline)

IMAGING PERFORMED BY
Meghan Myers, VMD

HOSPITAL NAME
Hershire AH

REFERRING VET
Noelle Weeks, VMD

INVOICE
12842

DATE
11/19/25

PRESENTING CLINICAL SIGNS

History: senior patient, outside ultrasound referral for gagging, excessive gas and weight loss. PE: chronic mild dehydration, grade 3/5 parasternal systolic heart murmur, underweight, muscle wasting, intestines palpate thickened. recent blood work at humane society showed early renal disease with mildly elevated sdma, creat and bun.

ULTRASONOGRAPHIC EXAMINATION OF THE ABDOMEN

Urinary System

The urinary bladder was normal in size and tone with generalized mild to variable thickened urinary bladder wall exhibiting homogeneous mural echogenicity and asymmetrical luminal surface contour. No evidence of mural mineralization or tumors. Urinary bladder wall measured 0.51 cm. Anechoic urine was present without evidence of mineral or calculi. The visible proximal urethra to a depth of 2.0 cm exhibited normal thickness and tone.

The area of the aortic trifurcation was free of pathology.

Normal size and margination was present in the kidneys. A normal 1:3 cortex / medulla ratio was maintained. The medulla and cortices were uniform in texture with some increased echogenicity and mild to moderate indistinct loss of corticomedullary symmetry and definition expected for the age of the patient. No evidence of pelvic dilation was present. The left kidney measured 3.7 cm in length. The right kidney measured 3.6 cm in length.

Adrenal Glands

The left adrenal gland was uniform in size and contour with a uniformly hypoechoic parenchyma. The left adrenal gland measured 0.47 cm. The right adrenal gland was uniform in size and contour with a uniformly hypoechoic parenchyma. The right adrenal gland measured 0.36 cm.

Spleen

The spleen was mildly enlarged in size with maintained symmetrical capsule contour and mild heterogeneous parenchyma. The spleen measured 1.1 cm width level of the mid spleen.

Liver

The liver was subjectively normal in size, structure, and contour. The liver parenchyma was mildly nonuniform and hypoechoic to the spleen with a moderate coarse echotexture and subjective mild to benign parenchymal remodeling. The hepatic and portal vasculature were normal in appearance without signs of congestion. The gallbladder was non-distended in size with thin walls and primarily anechoic luminal content. The cystic and common bile ducts were normal.

Gastrointestinal

The stomach presented intact wall layering with a normal wall layer ratio. The lumen of the stomach was empty with no signs of ileus, obstruction or foreign material.

The small intestine presented intact mildly thickened wall with mild altered wall layer ratio owing to propensity for borderline prominent to thickened muscularis/mucosa layer. Duodenum wall measured 0.36 cm, jejunum wall measured 0.33 cm, and ileocolic wall measured 0.43 cm.

PATIENT
Cheetah Gudoski

SPECIES
Feline

BREED
DSH

SEX
Female Spayed

AGE
15y

WEIGHT
6.8 lbs

INTERPRETED BY
R. McKenzie Daniel, DVM, DABVP (Canine and Feline)

IMAGING PERFORMED BY
Meghan Myers, VMD

HOSPITAL NAME
Hershire AH

REFERRING VET
Noelle Weeks, VMD

INVOICE
12842

DATE
11/19/25

Normal visible colon wall layers were present with apparent formed feces in lumen.

Pancreas

The area of the pancreas was sonographically normal.

Free Abdomen

Intermittent, mild to variably enlarged non-homogeneous mesenteric lymph nodes were present exhibiting width: length ratio >0.5. An example of lymph node measurement was 1.6 cm x 1.1 cm. Scant peritoneal effusion was present,

ULTRASONOGRAPHIC FINDINGS

- Thickened urinary bladder
- Bilateral chronic renal changes
- Mildly enlarged non-homogeneous spleen
- Sonographically normal empty stomach
- Chronic enteropathy pattern exhibiting intact mildly thickened wall
- Variable non-homogeneous mesenteric lymphadenopathy, scant peritoneal effusion

INTERPRETATION OF THE FINDINGS & FURTHER RECOMMENDATIONS

Chronic IBD or other inflammatory enteropathy with lymphatic hyperplasia or lymphadenitis favored, intestinal round cell neoplasia such as lymphoma and metastatic lymphadenopathy not excluded. Further assessment may include lymph node FNA cytology and a GI panel to include PLI/TLI/Cobalamin/Folate. Gastrointestinal support and empirical therapy for chronic enteropathy including gastro protectants if evidence of esophagitis is recommended. Correlation with urinary workup including C/S and baseline UPC level for renal staging is recommended. Sonographic monitoring of the gastrointestinal tract if progressive weight loss as well as the urinary bladder if lower urinary tract signs is recommended.

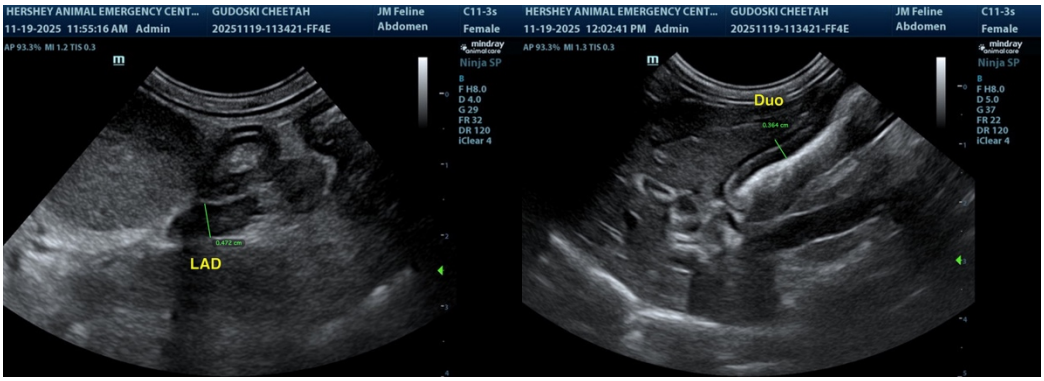

SonoPath

FOSTERING THE ART OF VETERINARY MEDICINE™

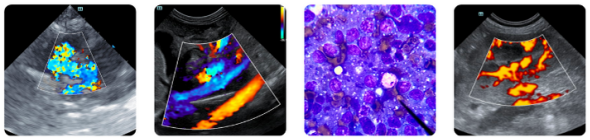

Clinical Sonography & Telecytology

Educational Teleconsultation Services™

SonoPath.com *info@sonopath.com* *1.800.838.4268*

PATIENT

Cheetah Gudoski

SPECIES

Feline

BREED

DSH

SEX

Female Spayed

AGE

15y

WEIGHT

6.8 lbs

INTERPRETED BY

R. McKenzie Daniel, DVM, DABVP (Canine and Feline)

IMAGING PERFORMED BY

Meghan Myers, VMD

HOSPITAL NAME

Hershire AH

REFERRING VET

Noelle Weeks, VMD

INVOICE

12842

DATE

11/19/25

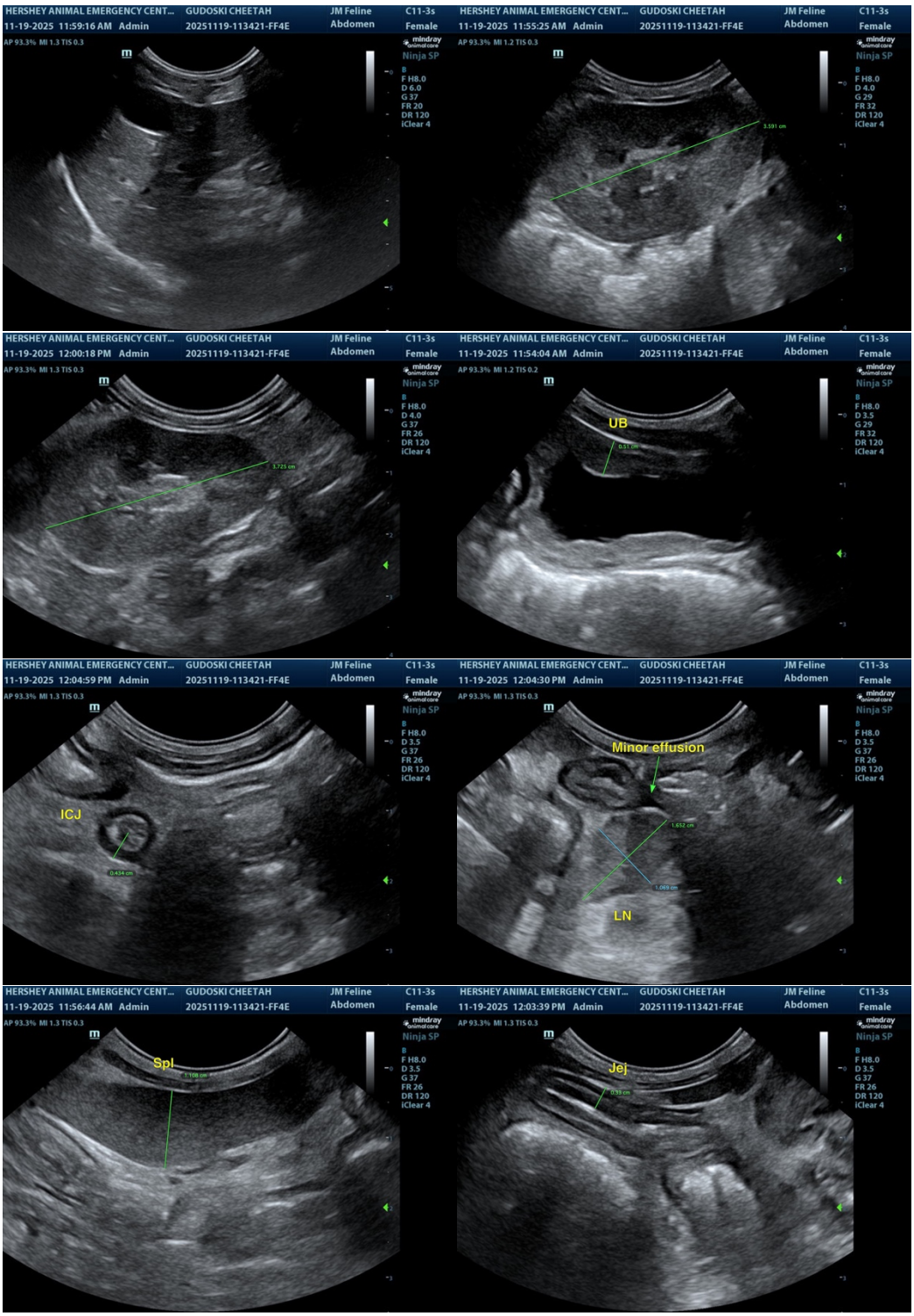

SonoPath
FOSTERING THE ART OF VETERINARY MEDICINE™

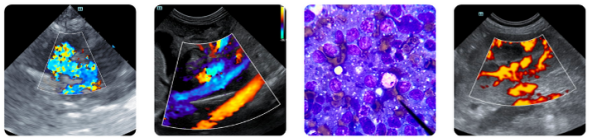

Clinical Sonography & Telecytology
Educational Teleconsultation Services™

SonoPath.com *info@sonopath.com* *1.800.838.4268*

PATIENT

Cheetah Gudoski

SPECIES

Feline

BREED

DSH

SEX

Female Spayed

AGE

15y

WEIGHT

6.8 lbs

INTERPRETED BY

R. McKenzie Daniel, DVM, DABVP (Canine and Feline)

IMAGING PERFORMED BY

Meghan Myers, VMD

HOSPITAL NAME

Hershire AH

REFERRING VET

Noelle Weeks, VMD

INVOICE

12842

DATE

11/19/25

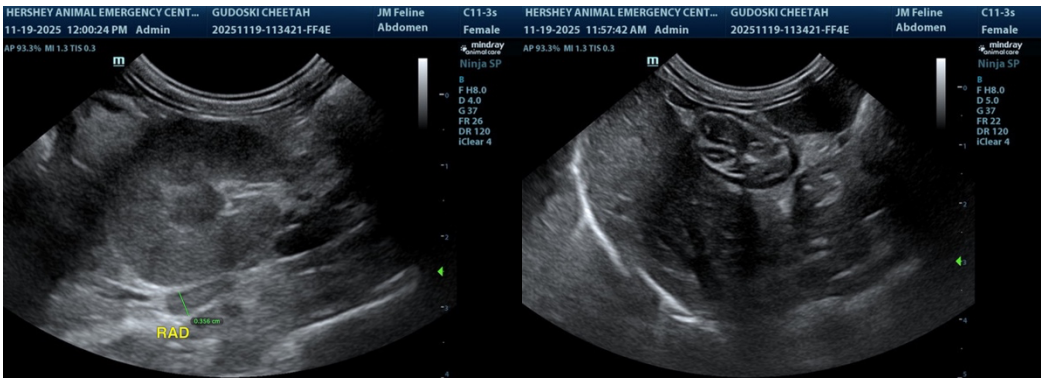

The information and recommendations provided are based on the images presented by the referring veterinarian/sonographer. No evaluation can be communicated regarding pathology that was not visible in the image/video clips provided.

Thank you for this referral. If the clinical or image interpretation does not parallel your findings or if I can be of any further assistance, please contact me.

R. McKenzie Daniel, DVM, DABVP (Canine / Feline Practice)

info@sonopath.com