



PATIENT

Cheyenne Caswell

SPECIES

Canine

BREED

Labradoodle

SEX

Intact Female

AGE

11 Years 6 Months

WEIGHT

31.2

INTERPRETED BY

R. McKenzie Daniel,
DVM, DABVP

IMAGING PERFORMED BY

Dr. Aaron Lucas DVM,
PhD

HOSPITAL NAME

Taylorville Veterinary
Clinic

REFERRING VET

Dr. Aaron Lucas DVM,
PhD

INVOICE

12290

DATE

11/17/25

PRESENTING CLINICAL SIGNS

Evaluated for cough on 10/21/25 Grade 5/6 holosystolic heart murmur heard best over left heart base (Historical HM from previous DVM, but lower grade) Dry hacking cough upon tracheal palpation Mild cardiac enlargement (VHS - 11.5) Mammary mass (intact female) in left mammary chain Treated with doxycycline and hydrocodone PO and cough has greatly improved Patient re-evaluated for collapse (alert, but unable to rise in rear limbs per owner during coughing episode) on 10/24/25. - ECG unremarkable at this time - Cardiac cause suspected given murmur and radiographic signs of cardiac enlargement - Cough has resolved, however patient still has been having episodes of collapse per owner with increased frequency.

Abnormal PE/Chem/CBC/UA Results: Grade 5/6 left holosystolic HM Mild Normocytic normochromic Nonregenerative Anemia (HCT - 38%) Total T4 - 0.4

ULTRASONOGRAPHIC EXAMINATION OF THE HEART

CANINE CARDIAC PARAMETERS	MR VMAX (m/s)	TR VMAX (m/s)	LA/AO (M-Mode)	LA/AO (Heart Base; Swe)	FS (%)	EF (%)	EPSS (cm)
NORMAL PARAMETER	4.5-5.5	<2.7	1.3	Up to 1.6	28-40	40-100	<0.6
PATIENT	--	--	NM	2.0	47	79	0.4
CANINE CARDIAC PARAMETERS	HR (BPM)	AV VMAX (m/s)	PV MAX (m/s)	BODY WEIGHT (kg)	LAD LA MAX 4 Chamber	LVIDd Avg; 2D and m-mode short axis (cm)	LVIDs Avg; 2D and m-mode short axis (cm)
NORMAL PARAMETER	50-100	0.7-1.7	0.7-1.6				
PATIENT	NM	1.3	0.65	--	5.5	4.8	--

Cardiac Presentation

The echocardiogram in this patient demonstrated moderate to significant increased **left atrial** dimension with intra-atrial septal deviation based on 2 different LA measurement methods. The cranial and caudal **mitral** valve leaflets presented thickening consistent with endocardiosis with mild valve prolapse. Doppler indicated measurable insufficiency. The **left ventricle** presented normal wall thickness with moderate increased LV dimension. The **myocardium** presented normal echogenicity without subjective evidence of significant fibrotic or ischemic disease. **Contractility** of the ventricular walls was adequate and in normal range for this patient evidenced by the fractional shortening measurement and subjective evaluation of the different regions of the myocardium. The **left ventricular outflow** tract demonstrated normal laminar flow and subjective structural integrity. The **right atrium** and auricle revealed normal size, structure and content. No evidence of masses was noted or chamber overload. **Tricuspid** valvular assessment demonstrated thickening with TR on doppler. The **right ventricle** was of normal size (1/3 diameter of LV), chordae structure, myocardial echogenicity and



PATIENT

Cheyenne Caswell

SPECIES

Canine

BREED

Labradoodle

SEX

Intact Female

AGE

11 Years 6 Months

WEIGHT

31.2

INTERPRETED BY

R. McKenzie Daniel,
DVM, DABVP

IMAGING PERFORMED BY

Dr. Aaron Lucas DVM,
PhD

HOSPITAL NAME

Taylorville Veterinary
Clinic

REFERRING VET

Dr. Aaron Lucas DVM,
PhD

INVOICE

12290

DATE

11/17/25

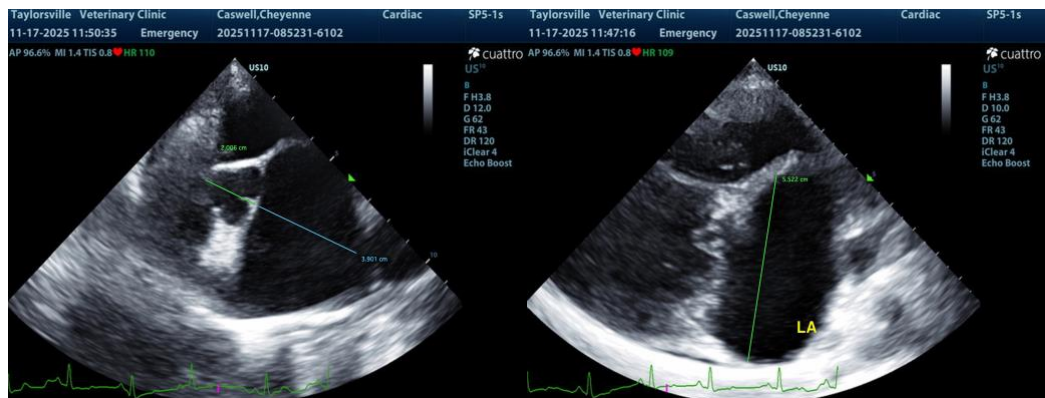
thickness. **Pulmonic** tract assessment revealed normal valve structure, laminar flow, and diameter (approx.1:1 pa/ao ratio). Scant volume of **pericardial** effusion was noted without evidence of cardiac tamponade. No evidence of pleural effusion, pericardial or mediastinal masses in the visible window. No evidence of arrhythmia or current hepatic congestion.

ULTRASONOGRAPHIC FINDINGS

- Chronic mitral valve disease with valve prolapse and left heart volume overload (ACVIM B2-possible emerging B2+).
- TV insufficiency with normal RA/RV dimension.
- Scant pericardial effusion.
- Noncongested liver.

INTERPRETATION OF THE FINDINGS & FURTHER RECOMMENDATIONS

The degree of LA/LV enlargement indicates the current and future risk of complication, secondary to MR and emerging left heart volume overload, is elevated. Pimobendan 0.30 mg/kg BID, lowest effective dose diuretic 1.0 to 2.0 mg/kg PO BID, ACE inhibitor 0.50 mg/kg SID titrating to BID if evidence of hypertension and clinical monitoring is indicated. Definitive evidence of clinical pulmonary hypertension was not obvious. The coughing in this patient may be multifactorial owing to emerging left heart volume overload, main stem bronchi irritation secondary to LA enlargement or concurrent lower airway disease. Continued respiratory support including antitussive medication would be appropriate. A definitive cause of the scant pericardial effusion was not obvious. Abdominal sonogram may be considered to assess for abdominal pathology i.e. splenic pathology as a contributing factor. Monitoring of ECG for evidence of arrhythmia as well as baseline resting respiration rate going forward is recommended. Elevated anesthetic risk. If anesthesia is required, the following protocol is suggested with judicious IV fluid use and limited anesthetic time. Recheck echo is suggested in 3-4 months or sooner if clinically indicated. Suggested anesthetic protocol may include opioid or Benzodiazepine pre-med, induction with Propofol or Alfaxalone, and appropriate gas anesthesia with avoidance of alpha 2 agonists.





PATIENT

Cheyenne Caswell

SPECIES

Canine

BREED

Labradoodle

SEX

Intact Female

AGE

11 Years 6 Months

WEIGHT

31.2

INTERPRETED BY

R. McKenzie Daniel,
DVM, DABVP

IMAGING PERFORMED BY

Dr. Aaron Lucas DVM,
PhD

HOSPITAL NAME

Taylorville Veterinary
Clinic

REFERRING VET

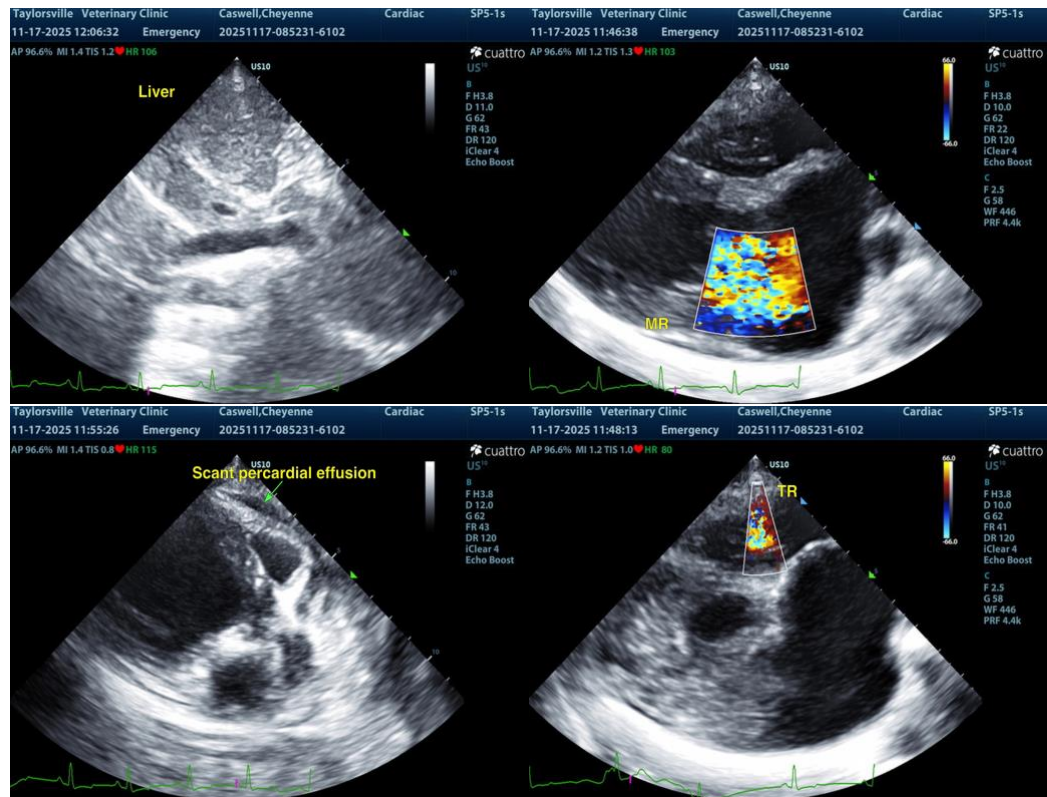
Dr. Aaron Lucas DVM,
PhD

INVOICE

12290

DATE

11/17/25



The information and recommendations provided are based on the images presented by the referring veterinarian/sonographer. No evaluation can be communicated regarding pathology that was not visible in the image/video clips provided.

Thank you for this referral. If the clinical or image interpretation does not parallel your findings or if I can be of any further assistance, please contact me.

R. McKenzie Daniel, DVM, DABVP (Canine / Feline Practice)

info@SonoPath.com