



PATIENT PRESENTING CLINICAL SIGNS

Dallas Black PU/PD for a couple months - no v/d/c/s - no meds at this time - PE stable, NSF
Abnormal PE/Chem/CBC/UA Results: Please see attached blood results. *attached (elevated ALP, isosthenuria and 2+ urine protein) ALP 434, unremarkable CBC.

SPECIES

Canine

ULTRASONOGRAPHIC EXAMINATION OF THE ABDOMEN

Urinary System

BREED

Border Collie X

The urinary bladder, trigone, cystourethral junction, and visible pelvic urethra to a depth of 3.0 cm exhibited normal thickness and tone. Anechoic urine was present in the lumen with no uroliths or sediment. The ureteral papillae were normal. The ureters were not visible which is normal. No evidence of inflammatory or neoplastic changes were noted.

SEX

Neutered Male

The residual prostate was symmetrically normal in size with uniform parenchyma and slight coarse echotexture. The prostate measured 0.86 cm diameter.

The area of the aortic trifurcation was free of pathology.

AGE

8 Years

Normal size and margination were present in the kidneys. A normal 1:3 cortex / medulla ratio and normal corticomedullary definition were maintained. The echogenicity of the cortex was similar to or slightly less than normal liver parenchyma while the medulla echogenicity was hypoechoic to the cortex with no evidence of pelvic dilation. The left kidney measured 6.8 cm. The right kidney measured 7.1 cm.

WEIGHT

29.3 kg

Adrenal Glands

The adrenal glands were uniform in size and contour with a uniformly hypoechoic parenchyma. The left adrenal gland measured 2.4 cm length x 0.91 cm at the caudal pole. The right adrenal gland measured 2.3 cm length x 0.65 cm at the caudal pole.

INTERPRETED BY

R. McKenzie Daniel, DVM,
DABVP (Canine and
Feline)

Spleen

The spleen exhibited a finely textured and homogenous parenchyma which was hyperechoic to the liver and renal cortical parenchyma. The capsule was smooth and regular without apparent expansion. The splenic vasculature at the hilus was normal in volume with no evidence of congestion or thrombosis. Acute to chronic inflammatory, neoplastic, or benign parenchyma changes were not noted.

IMAGING PERFORMED BY

Crystal Hill

Liver

HOSPITAL NAME

Yates Animal Hospital

The liver exhibited mild enlargement. The parenchyma of the liver was subjectively normal in echogenicity compared to the spleen and renal cortices. The liver parenchyma was uniform with a mildly coarse echotexture. The capsule of the liver was symmetrically rounded to mildly swollen in margination. The hepatic and portal vasculature were normal in appearance without signs of congestion. The gallbladder was non distended in size with mild, echogenic, nonmineralized biliary sludge. The cystic duct and common bile ducts were normal without evidence of dilation.

REFERRING VET

Dr. Krizmanich

Gastrointestinal

INVOICE

29859

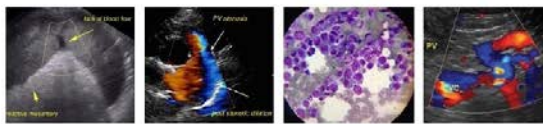
The stomach presented intact wall layering with a normal wall layer ratio. The lumen of the stomach was empty with no signs of ileus, obstruction or foreign material.

The small intestine presented intact wall layering with 1:3 muscularis/mucosa ratio. The lumen of the small intestine was empty with no signs of ileus, obstruction or foreign material.

DATE

11/17/21

Normal visible colon wall layers were present with apparent formed feces in lumen.



PATIENT *Pancreas*

Dallas Black The parenchyma of the left limb, body and right limb of the pancreas presented isoechoic to the adjacent omental fat. A normal curvilinear capsule contour of the pancreas was present. The visible pancreatic duct was normal. No signs of active inflammation or neoplastic disease was evident.

SPECIES

Canine

BREED

Border Collie X

SEX

Neutered Male

AGE

8 Years

WEIGHT

29.3 kg

ULTRASONOGRAPHIC FINDINGS

- Mild hepatomegaly - subjectively benign.
- Minor gallbladder debris, (non-mucocele)
- Sonographically unremarkable bilateral kidneys, no overt pyelonephritis
- Sonographically unremarkable bilateral adrenal glands, no overt hyperplasia or tumors

INTERPRETATION OF THE FINDINGS & FURTHER RECOMMENDATIONS

The overall appearance of the liver is consistent with benign hepatopathy/hepatomegaly with considerations including vacuolar hepatopathy or non-clinical cholestasis given the elevated ALP along with minor gallbladder debris. Potential for low-grade inflammatory hepatopathy is considered less likely without evidence of neoplastic criteria. Subjectively, the appearance of the liver was not overtly consistent with steroid hepatopathy.

Full adrenal workup could be considered if strong clinical suspicion for hyperadrenocorticism. Further assessment may include further renal staging to include urine culture and sensitivity and baseline UPC on sterile urine sample and Leptospirosis titers/PCR. Hepatosupportive medications may be considered empirically.

INTERPRETED BY

R. McKenzie Daniel, DVM,
DABVP (Canine and
Feline)

IMAGING PERFORMED BY

Crystal Hill

HOSPITAL NAME

Yates Animal Hospital

REFERRING VET

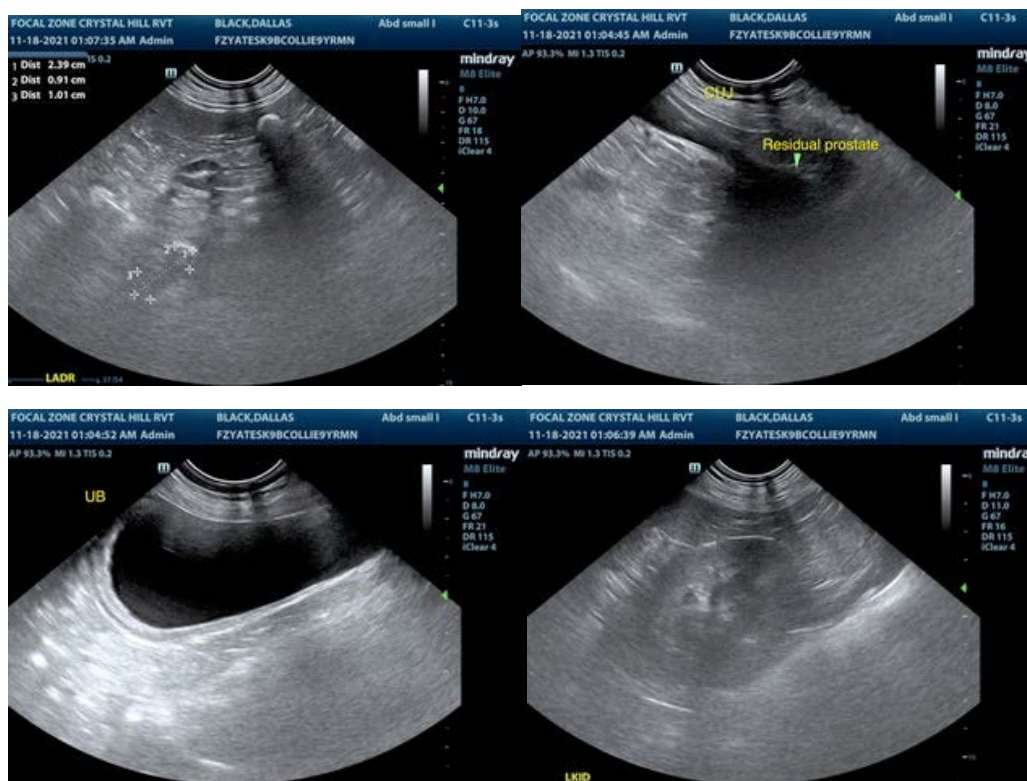
Dr. Krizmanich

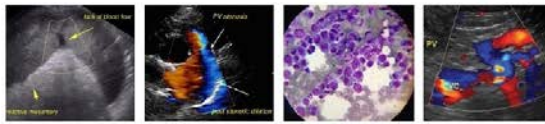
INVOICE

29859

DATE

11/17/21





PATIENT

Dallas Black

SPECIES

Canine

BREED

Border Collie X

SEX

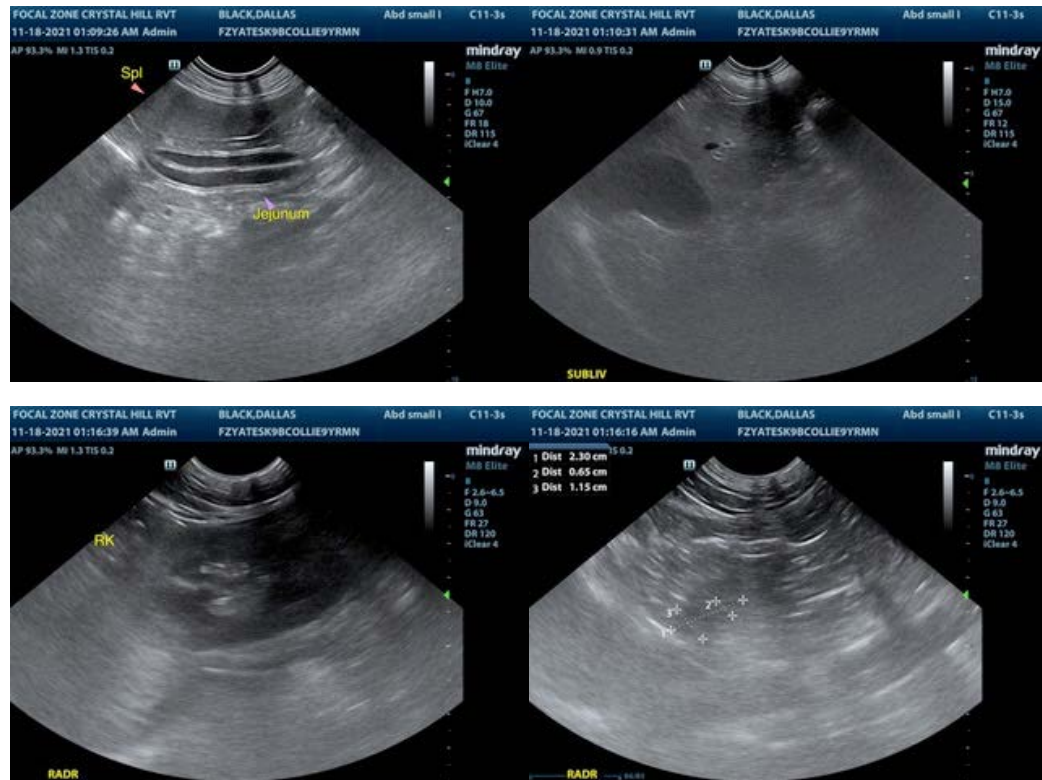
Neutered Male

AGE

8 Years

WEIGHT

29.3 kg



INTERPRETED BY

R. McKenzie Daniel, DVM,
DABVP (Canine and
Feline)

**IMAGING
PERFORMED BY**

Crystal Hill

HOSPITAL NAME

Yates Animal Hospital

REFERRING VET

Dr. Krizmanich

INVOICE

29859

DATE

11/17/21

The information and recommendations provided are based on the images presented by the referring veterinarian. No evaluation can be communicated regarding pathology that was not visible in the image/video clips provided.

Thank you for this referral. If the clinical or image interpretation does not parallel your findings or if I can be of any further assistance please contact me.

R. McKenzie Daniel, DVM, DABVP (Canine / Feline Practice)
info@SonoPath.com