



PATIENT

Pippi Carter

SPECIES

Feline

BREED

DSH

SEX

FS

AGE

9 years 4 months

WEIGHT

9.2 lbs

INTERPRETED BY

R. McKenzie Daniel,
DVM, DABVP
(Canine and Feline)

IMAGING PERFORMED BY

Amanda Crook -
SDEP Certified
Clinical Sonographer

HOSPITAL NAME

Rivers Edge PMC

REFERRING VET

Dr. David Gray

INVOICE

12624

DATE

11/16/21

PRESENTING CLINICAL SIGNS

History of crystals/UTI - P inapprop. urinated in front of owners today which is usually a sign that P has another UTI

Abnormal PE/Chem/CBC/UA Results: See attached UA (free catch) - gross hematuria on table top catch and unable to hold urine long term

ULTRASONOGRAPHIC EXAMINATION OF THE URINARY SYSTEM

Urinary System

The urinary bladder was subnormal in size owing to a lack of urine distention. The lack of a full urinary bladder prohibited full evaluation of the urinary bladder walls, yet generalized mild to potentially moderate mural hypertrophy exhibiting primarily homogeneous mural echogenicity was present. Mild to moderate, dependent to adhered mineral to potential small calculi were present in the urinary bladder lumen. The majority of the adhered mineral appeared to be subjectively in the region of the ventral to ventroapical urinary bladder wall likely consistent with where the mineral is generally located when the patient is awake or sternal. No overt evidence of neoplastic criteria was noted. Mild tissue inflammation was noted around the urinary bladder. The urethra exhibited normal subjective structure and tone to a depth of 2.0 cm with pinpoint to focal areas of nonobstructive concurrent urethral luminal mineral.

Normal size and margination were present in the kidneys. A normal 1:3 cortex / medulla ratio and normal corticomedullary definition were maintained. The echogenicity of the cortex was similar to or slightly less than normal liver parenchyma while the medulla echogenicity was hypoechoic to the cortex with no evidence of pelvic dilation. The left kidney measured 3.6 cm in length. The right kidney measured 3.7 cm in length.

ULTRASONOGRAPHIC FINDINGS

Primary Findings

- Chronic cystitis pattern with mild to moderate, dependent to adhered mineral to potential small calculi
- Nonobstructive pinpoint to focal urethral luminal mineral
- Sonographically unremarkable bilateral kidneys

INTERPRETATION OF THE FINDINGS & FURTHER RECOMMENDATIONS

Cystostomy with urinary bladder and urethral flush, as well as urinary bladder mural biopsies for histopathology, as well as tissue C/S could be considered. Conservatively, medical therapy for chronic cystitis / feline idiopathic cystitis including dissolution diet, analgesia, anti-inflammatory medications, as well as environmental enrichment, and increased water intake, among other potential treatment options, would be appropriate.



PATIENT

Pippi Carter

SPECIES

Feline

BREED

DSH

SEX

FS

AGE

9 years 4 months

WEIGHT

9.2 lbs

INTERPRETED BY

R. McKenzie Daniel,
DVM, DABVP
(Canine and Feline)

IMAGING PERFORMED BY

Amanda Crook -
SDEP Certified
Clinical Sonographer

HOSPITAL NAME

Rivers Edge PMC

REFERRING VET

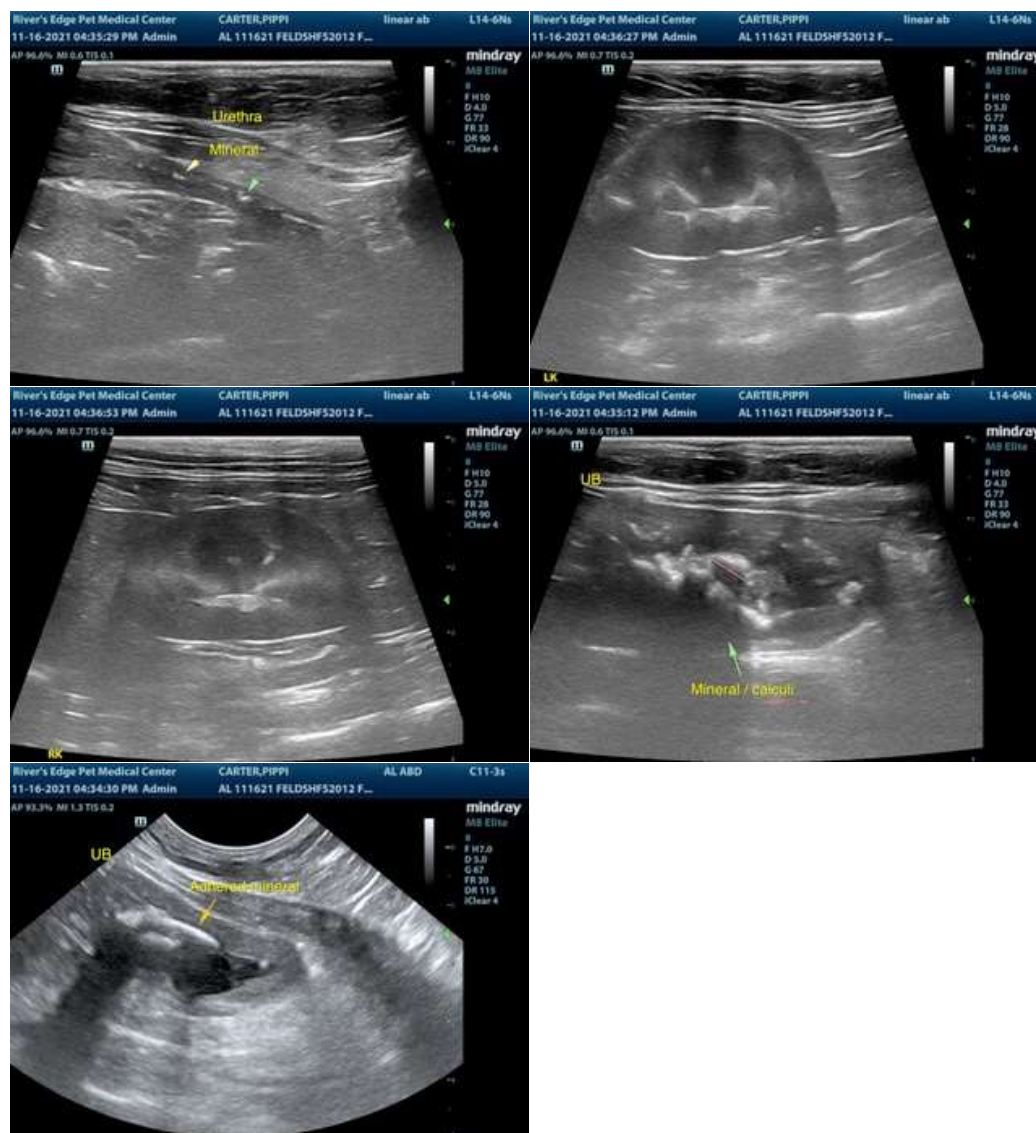
Dr. David Gray

INVOICE

12624

DATE

11/16/21



The information and recommendations provided are based on the images presented by the referring veterinarian. No evaluation can be communicated regarding pathology that was not visible in the image/video clips provided.

Thank you for this referral. If the clinical or image interpretation does not parallel your findings or if I can be of any further assistance please contact me.

R. McKenzie Daniel, DVM, DABVP (Canine / Feline Practice)
info@SonoPath.com


PATIENT
<http://www.sonopath.com/FelineCystitis>

Pippi Carter

SPECIES

Feline

BREED

DSH

SEX

FS

AGE

9 years 4 months

WEIGHT

9.2 lbs

INTERPRETED BY

 R. McKenzie Daniel,
 DVM, DABVP
 (Canine and Feline)

IMAGING PERFORMED BY

 Amanda Crook -
 SDEP Certified
 Clinical Sonographer

HOSPITAL NAME

Rivers Edge PMC

REFERRING VET

Dr. David Gray

INVOICE

12624

DATE

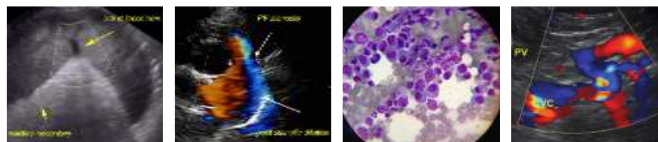
11/16/21

Description: Feline idiopathic cystitis (FIC) is defined as recurrent stranguria and hematuria in cats in the absence of an underlying cause. It is considered to be an exclusionary diagnosis once radiographs, ultrasound, coagulation profile, and aerobic urine culture by cystocentesis have eliminated the possibilities of urinary tract infection, urolithiasis, coagulopathies, and neoplasia. Clinical signs may resolve spontaneously within 3-7 days, with 30-50% recurrence within a year. Cats most frequently acquire the disease between the ages of 2 and 6, and although any breed is susceptible, Persian cats are overrepresented among those affected. Overweight spayed females and neutered males in a multi-cat household are at higher risk than their lean, solitary, or intact counterparts. Indoor, sedentary, dry-food eaters are at higher risk than outdoor cats that eat *ad libitum*. Psychosomatic influences—change of residence, new household members, pet additions, change of household objects—on the urinary bladder have been shown to play an important role in the pathophysiology of the disease. Neurogenic inflammation, decreased glycosaminoglycan concentration, and increased bladder permeability are tissue alterations found on histopathological review of affected bladders. Neurotransmitter P is increased in affected tissue and may be specifically targeted in eventual courses of treatment.

Clinical Signs: In the absence of an underlying urinary tract infection or evidence of neoplasia, FIC may present in an acute or chronic form with the following intermittent lower urinary tract symptoms: inappropriate urination (> 6 times/week in 70% of cases); stranguria (70%); hematuria (50%); and pollakiuria (80%).

Diagnostics: Since FIC is a diagnosis of exclusion, abdominal radiographs, abdominal ultrasound, blood pressure, coagulation profile, and urine culture are all required to rule out other differentials. Biopsy of the bladder wall can be useful to evaluate for lymphocytic plasmacytic inflammation, which can occur in some cases. Taking a history and having a thorough conversation about the cat's environmental stressors are imperative.

Treatment: Given that no specific cause has been cited and that FIC is considered a multifactorial disease, multimodal therapy is recommended. To date, no specific therapeutic has been effective in treating FIC. Palliation with pain management can be achieved with buprenorphine (0.02 mg/kg PO, IM, or IV BID-TID for 3-4 days). Practitioners have attempted the following with varying results: the introduction of a strict canned food diet; a change of feeding location in multi-cat households; and stimulating increased water intake using tuna or clam juice additives or circulating water fountains. To date, the most scientifically valid evidence points to the need for reducing urine concentration, which is achieved with canned food diets. In multiple studies, the simple act of switching to a canned therapeutic diet has been shown to reduce the risk of recurrence significantly. One study showed that only 11% of cats on a canned diet exhibited recurrent signs after a year, while those on a dry food diet displayed a 40% recurrence rate. Urine concentration can be reduced further by adding additional water into servings of canned food. Reduction of stress may be achieved by increasing litter box hygiene, placing the litter box in a quieter environment, and providing separate food, water, and litter areas for the affected patient in a multi-cat household. It has been suggested that Feliway, the feline facial pheromone, can be used as a calming agent for cats when they are in unfamiliar surroundings. Feliway mimics the natural facial hormone released when a cat marks his or her territory by face rubbing. For unresponsive or severe cases,



PATIENT

Pippi Carter

SPECIES

Feline

BREED

DSH

SEX

FS

AGE

9 years 4 months

WEIGHT

9.2 lbs

INTERPRETED BY

R. McKenzie Daniel,
DVM, DABVP
(Canine and Feline)

**IMAGING
PERFORMED BY**

Amanda Crook -
SDEP Certified
Clinical Sonographer

HOSPITAL NAME

Rivers Edge PMC

REFERRING VET

Dr. David Gray

INVOICE

12624

DATE

11/16/21

amitriptyline (10 mg PO Q24hr at bedtime) has been shown to have visceral analgesic, anticholinergic, mucosal mast cell inhibition, and anti-noradrenergic properties. Amitriptyline is considered standard therapy, but is only pursued once the preceding husbandry and feeding practices have proven to be ineffective. Amitriptyline should be used with caution in patients with cardiac disease or arrhythmias, and if instituted, should be used long-term. Studies indicate that short-term use of amitriptyline can result in faster recurrences. Note: Urine retention may occur while therapy is being administered. Biochemical panels should be monitored while a patient is undergoing amitriptyline therapy as liver enzyme elevation can occur. Glycosaminoglycan supplementation (pentosan polysulphate 2-10 mg/kg PO BID) has shown modest success (10-20%) in human trials for idiopathic cystitis. If used, a powder form is recommended to avoid the stress of pill administration (feline Cosequin capsules contain a powder that can be sprinkled onto food). Antiviral agents have not been shown to be effective, and even though researchers have suggested that the concurrent presence of *Calicivirus* may play a role and virus-like particles have been identified in urethral plugs and urine, no adequate evidence of a viral etiology has yet been demonstrated. A double-blind placebo trial suggested that glucocorticoids had no clinical benefits in 12 cases. All cases were self-limiting, in spite of whether the subjects were medicated with corticosteroids or not.

If hematuria seems persistent despite therapy and does not follow a typical FIC pattern (i.e., resolving within one week but recurring within a few weeks), cystoscopy or surgical evaluation may be indicated. Biopsies can be obtained, which allows for histopathology and bladder wall culture.

Environmental enrichment is also important to reduce stress. Providing vertical climbing surfaces, such as cat trees, increasing the number of litter boxes on different floors of the house (the rule of thumb is the number of litter boxes per house should equal the number of cats plus one), and increasing owner attention time, scheduled playtime, as well as supervised outdoor activity can decrease stress for cats.

Conclusion: Effective treatment of FIC involves a multi-modal approach with a strong emphasis on husbandry. Pet owners should focus on the fastidious upkeep of litter boxes and feed their cats canned food to both increase dietary water intake and maintain their cat's lean body weight. Stress management is also key and can be facilitated with environmental enrichment as well as an understanding of feline behavior.

References:

Buffington CA, Westropp JL, et al. Clinical evaluation of multimodal environmental modification (MEMO) in the management of cats with idiopathic cystitis. *J Feline Med Surg* 2006;8:261-68.

Chew DJ, Buffington CA, Kendall MS, et al. Amitriptyline treatment for severe recurrent idiopathic cystitis in cats. *J Am Vet Med Assoc* 1998;213(9):1282-86.

Defauw PAM, Van de Maele I, et al. Risk factors and clinical presentation of cats with feline idiopathic cystitis. *J Feline Med Surg* 2011;13(12):967-75.



PATIENT

Pippi Carter

Kraijer M, Fink-Gremmels J, Nickel RF. The short-term efficacy of amitriptyline in the management of idiopathic feline lower urinary tract disease: a controlled clinical study. *J Feline Med Surg* 2003;5(3):191-96.

SPECIES

Feline

Kruger JM, Conway TS, Kaneene JB, et al. Randomized controlled trial of the efficacy of short-term amitriptyline administration for treatment of acute, nonobstructive, idiopathic lower urinary tract disease in cats. *J Am Vet Med Assoc* 2003;222(6):749-58.

BREED

DSH

Westropp JL, Kass PH, Buffington CA. Evaluation of the effects of stress in cats with idiopathic cystitis. *Am J Vet Res* 2006;67:731-36.

SEX

FS

AGE

9 years 4 months

WEIGHT

9.2 lbs

INTERPRETED BY

R. McKenzie Daniel,
DVM, DABVP
(Canine and Feline)

**IMAGING
PERFORMED BY**

Amanda Crook -
SDEP Certified
Clinical Sonographer

HOSPITAL NAME

Rivers Edge PMC

REFERRING VET

Dr. David Gray

INVOICE

12624

DATE

11/16/21