

PATIENT PRESENTING CLINICAL SIGNS

Gabriel Hennig Three day history anorexia, mild vomiting, historical diabetic well controlled on 2u vetsulin q12.
Abnormal PE/Chem/CBC/UA Results: PSL 534 else unremarkable

SPECIES Urinary System

Feline The urinary bladder, trigone, cystourethral junction, and visible pelvic urethra to a depth of 2.0 cm exhibited normal thickness and tone. Primarily anechoic urine was present in the lumen. Moderate, non-dependent to dependent, particulate sediment likely indicative of cellular or crystalline debris was present without evidence of calculus formation. The ureteral papillae were normal. The ureters were not visible which is normal. No evidence of inflammatory or neoplastic urinary bladder criteria was noted.

SEX The area of the aortic trifurcation was free of pathology.

MN Mild subnormal renal size with asymmetrical margination was present in the left kidney. The renal cortex presented uniformly increased echogenicity with uniform echotexture. The renal cortex appeared to be hypertrophied resulting in an altered cortex: medulla ratio. Mild loss of corticomedullary distinction was also present. Moderate pyelectasia was present in the left kidney. The renal medullary volume was subjectively reduced. The left kidney measured 2.6 cm in length.

AGE 15 years

WEIGHT The right kidney was mildly enlarged in size compared to the left and normal renal size for the species, with asymmetrical margination. The renal cortex presented uniformly increased echogenicity with uniform echotexture. The renal cortex appeared to be hypertrophied resulting in an altered cortex: medulla ratio. Mild loss of corticomedullary distinction was also present. Mild pyelectasia was present in the right kidney. The renal medullary volume was subjectively reduced. The right kidney measured 5.2 cm in length.

INTERPRETED BY

R. McKenzie Daniel, DVM,
DABVP (Canine and Feline)

Adrenal Glands

The left adrenal gland was uniform in size and contour with a uniformly hypoechoic parenchyma. The left adrenal gland measured 0.4 cm width. No overt pathology was noted in the right adrenal gland.

IMAGING PERFORMED BY

Loetitia Saint-Jacques, RVT

Spleen

HOSPITAL NAME

VCA Feline AH

The spleen exhibited primarily finely textured and homogenous parenchyma which was hyperechoic to the liver and renal cortical parenchyma. Intermittent, non-expansive, uniformly echogenic nodules were present throughout the cranial to caudal parenchyma. An example of a nodule measured 0.53 cm in diameter. The capsule was smooth and regular without apparent expansion. The splenic vasculature at the hilus was normal in volume with no evidence of congestion or thrombosis. Acute to chronic inflammatory or neoplastic changes were not noted. The echogenic nodules tend to trend benign and are most consistent with benign hyperplasia or myelolipomas. The spleen itself measured 1.0 cm width at the level of the hilus.

REFERRING VET

Dr. Vincent Fleming

INVOICE

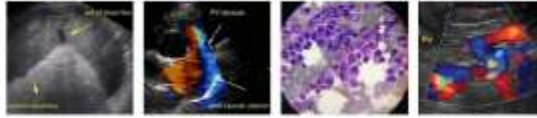
12620

Liver/ Gallbladder

DATE

11/16/21

The liver was subjectively normal in size, structure, and contour. The liver parenchyma was mildly nonuniform and hypoechoic to the spleen with a moderate coarse echotexture and subjective mild to benign parenchymal remodeling. The hepatic and portal vasculature were normal in appearance



PATIENT

Gabriel Hennig

without signs of congestion. The gallbladder was non-distended in size with thin walls and primarily anechoic luminal content. The common bile duct exhibited subtle distention approaching the level of the duodenal papilla, measuring 0.3 cm width. This is not consistent with post-hepatic obstruction.

SPECIES

Feline

Gastrointestinal

The stomach presented intact wall layering and a normal wall layer ratio with mild echogenic to subtle progressively shadowing ingesta present. The gastric body wall width measured 0.26 cm.

BREED

DSH

The small intestine presented intact wall layering with 1:3 muscularis/mucosa ratio. The lumen of the small intestine was empty with no signs of ileus, obstruction, or foreign material. The duodenum wall width measured 0.28 cm. The jejunum wall width measured 0.25 cm. The ileocolic wall width measured 0.37 cm.

SEX

MN

Normal visible colon wall layers were present with apparent formed feces in lumen.

AGE

15 years

Diffuse enlargement of the pancreas with ill-defined, hypoechoic to heterogeneous parenchyma and asymmetrical contour was present. The surrounding omental fat around the enlarged to hypoechoic pancreas was echogenic indicative of reactive change, adhesions, focal peritonitis, or saponification.

WEIGHT

16 lbs.

Free Abdomen

Mild peritoneal free fluid was present around the spleen.

Several, mildly prominent colic lymph nodes were present. The lymph nodes were essentially isoechoic to adjacent omentum without evidence of peripheral inflammation and maintaining a normal width: length ratio (<0.5). An example of a colic lymph node measured 0.56 cm width. No other evidence of significant intraabdominal lymphadenopathy was noted.

INTERPRETED BY

R. McKenzie Daniel, DVM,
DABVP (Canine and Feline)

ULTRASONOGRAPHIC FINDINGS

IMAGING PERFORMED BY

Primary Findings

Loetitia Saint-Jacques, RVT

- Active pancreatitis with regional peri pancreatic reactive to Inflamed mesentery - no overt evidence of abscessation or masses
- Left kidney subnormal size with chronic Interstitial nephrosis pattern and moderate pyelectasia
- Right kidney compensatory hypertrophy to chronic Interstitial nephrosis pattern with moderate pyelectasia
- Moderate urinary bladder sediment
- Previously noted static benign splenic nodules
- Several subjectively benign to prominent colic lymph nodes
- Scant peritoneal free fluid

HOSPITAL NAME

VCA Feline AH

REFERRING VET

Dr. Vincent Fleming

INVOICE

12620

DATE

11/16/21



PATIENT

Gabriel Hennig

INTERPRETATION OF THE FINDINGS & FURTHER RECOMMENDATIONS

The urinary bladder sediment may suggest cellular / crystalline debris or mucus. Cystocentesis for UA +/- C/S if evidence of inflammatory cells is recommended.

SPECIES

Feline

A minor potential for pancreatic neoplasia, which may present in a similar sonographic manner, is possible yet thought less likely. Potentially, pancreatic FNA could be considered for screening cytology. Medical therapy for active pancreatitis with as-needed gastrointestinal support and monitoring of serum glucose levels is recommended. Recheck sonogram could be considered to assess for progressive Inflammatory pancreatic changes pending clinical response to therapy or if continued signs of pancreatitis are noted.

BREED

DSH

SEX

MN

AGE

15 years

WEIGHT

16 lbs.

INTERPRETED BY

R. McKenzie Daniel, DVM,
DABVP (Canine and Feline)

IMAGING PERFORMED BY

Loetitia Saint-Jacques, RVT

HOSPITAL NAME

VCA Feline AH

REFERRING VET

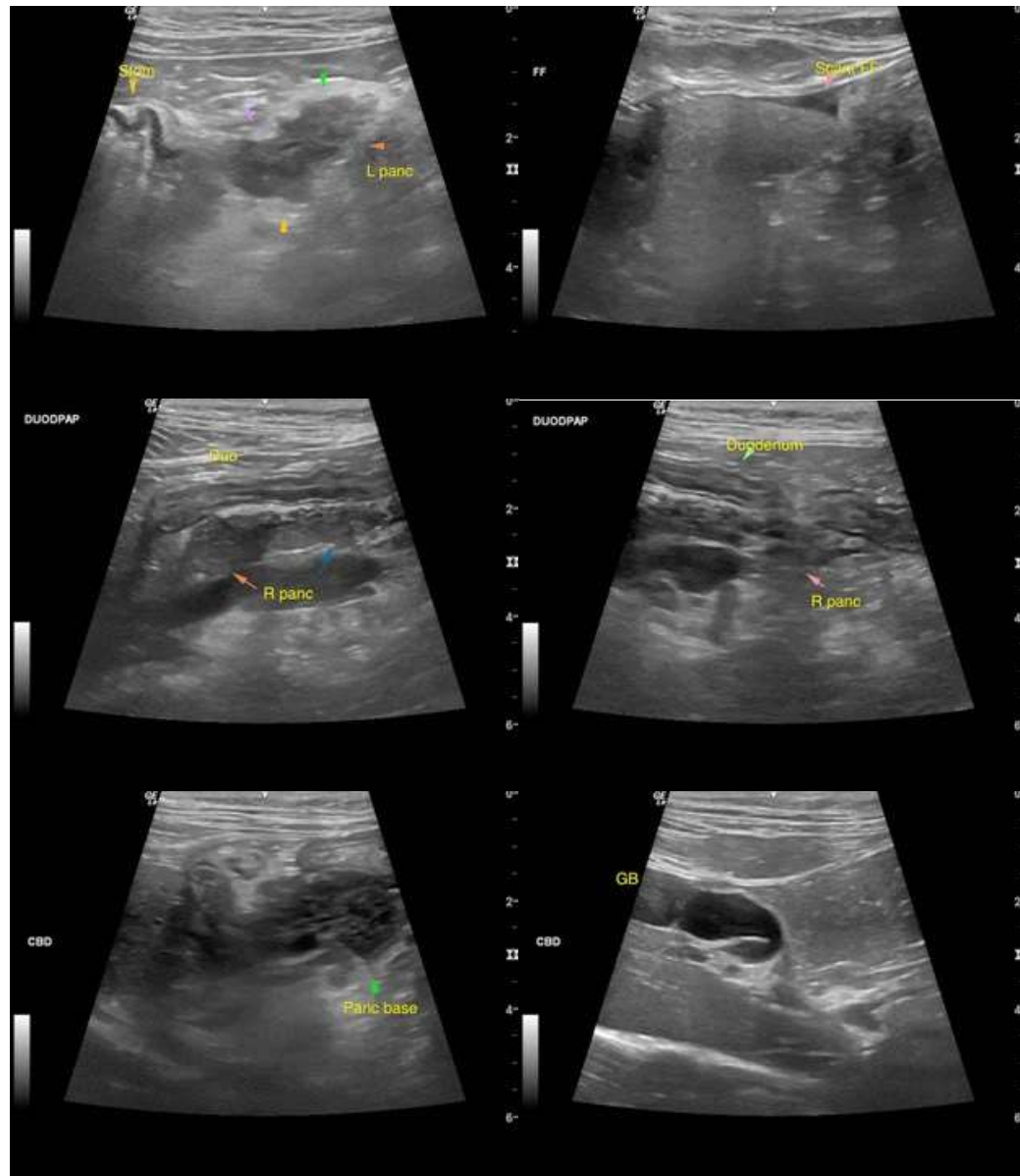
Dr. Vincent Fleming

INVOICE

12620

DATE

11/16/21





PATIENT

Gabriel Hennig

SPECIES

Feline

BREED

DSH

SEX

MN

AGE

15 years

WEIGHT

16 lbs.

INTERPRETED BY

R. McKenzie Daniel, DVM,
DABVP (Canine and Feline)

IMAGING PERFORMED BY

Loetitia Saint-Jacques, RVT

HOSPITAL NAME

VCA Feline AH

REFERRING VET

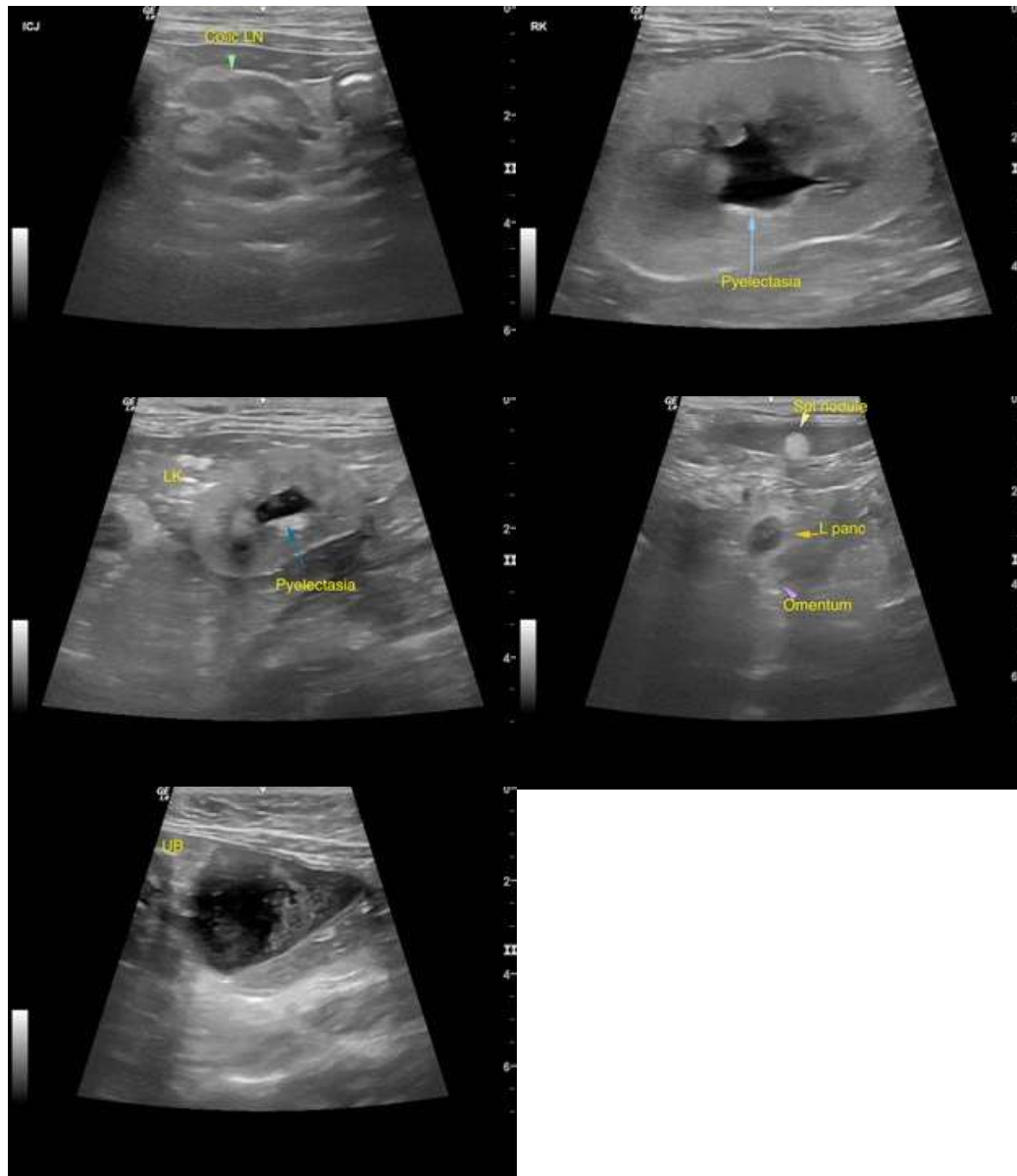
Dr. Vincent Fleming

INVOICE

12620

DATE

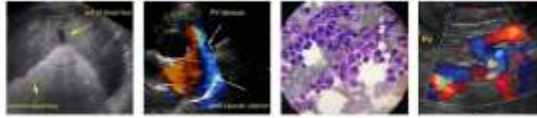
11/16/21



The information and recommendations provided are based on the images presented by the referring veterinarian. No evaluation can be communicated regarding pathology that was not visible in the image/video clips provided.

Thank you for this referral. If the clinical or image interpretation does not parallel your findings or if I can be of any further assistance please contact me.

R. McKenzie Daniel, DVM, DABVP (Canine / Feline Practice)



PATIENT info@SonoPath.com

Gabriel Hennig Crain SK, Sharkey LC, Corder AP, Knudson C, Armstrong PJ. Safety of ultrasound-guided fine-needle aspiration of the feline pancreas: a case-control study. *J Feline Med Surg.* 2015 17(10):858-63.

SPECIES

Feline

The safety of fine-needle aspiration (FNA) of the feline pancreas has not been reported. The incidence of complications following ultrasound-guided pancreatic FNA in 73 cats (pancreatic aspirate [PA] cats) with clinical and ultrasonographic evidence of pancreatic disease was compared with complications in two groups of matched control cats also diagnosed with pancreatic disease that either had abdominal organs other than the pancreas aspirated (control FNA, $n = 63$) or no aspirates performed (control no FNA, $n = 61$). The complication rate within 48 h of the ultrasound and/or aspirate procedure did not differ among the PA cats (11%), control FNA (14%) or control no FNA (8%) cats. There was no difference in rate of survival to discharge (82%, 84% and 83%, respectively) or length of hospital stay among groups. The cytologic recovery rate for the pancreatic samples was 67%. Correlation with histopathology, available in seven cases, was 86%. Pancreatic FNA in cats is a safe procedure requiring further investigation to establish diagnostic value.

BREED

DSH

SEX

MN

AGE

15 years

WEIGHT

16 lbs.

INTERPRETED BY

R. McKenzie Daniel, DVM,
DABVP (Canine and Feline)

IMAGING PERFORMED BY

Loetitia Saint-Jacques, RVT

HOSPITAL NAME

VCA Feline AH

REFERRING VET

Dr. Vincent Fleming

INVOICE

12620

DATE

11/16/21