



PATIENT PRESENTING CLINICAL SIGNS

Winnie Ezhov Wheezing, coughing, no improvement with cardiac medication, suspected pyometra/need for surgery.

ULTRASONOGRAPHIC EXAMINATION OF THE HEART & ABDOMEN

SPECIES

Canine

BREED

Miniature Pinscher

SEX

F

AGE

2010

WEIGHT

14.8

CANINE	MR	TR	LA/AO	LA/AO	FS	EF	EPSS
CARDIAC PARAMETERS	VMAX (m/s)	VMAX (m/s)	(Boon method)	(Heart Base; Swe)	(%)	(%)	(cm)
NORMAL PARAMETER	4.5-5.5	<2.7	1.3	<1.3	28-40	40-100	<0.6
PATIENT				1.24	39.1	74	0.2
CANINE	HR	AV	PV	BODY WEIGHT	LA	LVIDd	LVIDs
CARDIAC PARAMETERS	(BPM)	VMAX (m/s)	MAX (m/s)	(kg)	2D short axis Base view (cm)	Avg; 2D and m-mode short axis (cm)	Avg; 2D and m-mode short axis (cm)
NORMAL PARAMETER	50-100	0.7-1.7	0.7-1.6				
PATIENT	NM	NM	NM		2.6	2.3	

INTERPRETED BY

R. McKenzie Daniel,
DVM, DABVP
(Canine and Feline)

IMAGING PERFORMED BY

Rebekah Jakum, CVT
ARDMS/RVT

HOSPITAL NAME

Leighton AH

REFERRING VET

Dr. Mriss

INVOICE

15473

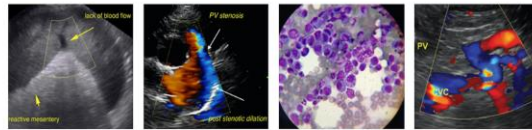
DATE
11/15/22

Cardiac Presentation

The echocardiogram in this patient demonstrated normal **left atrial** size based on 3 separate methods of LA evaluation. The cranial and caudal **mitral** valve leaflets presented normal linear structure, extension in systole, and union in diastole with normal kinesis. The **left ventricle** presented thicknesses with linear contour and was not dilated nor restricted. The **myocardium** presented normal echogenicity without subjective evidence of significant fibrotic or ischemic disease. **Contractility** of the ventricular walls was adequate and in normal range for this patient evidenced by the fractional shortening measurement and subjective evaluation of the different regions of the myocardium. The **left ventricular outflow** tract demonstrated normal laminar flow and subjective structural integrity. The **right atrium** and auricle revealed normal size, structure and content. No evidence of masses was noted. **Tricuspid** valvular assessment demonstrated adequate linear morphology and kinesis. The **right ventricle** was of normal size (1/3 diameter of LV), chordae structure, myocardial echogenicity and thickness. **Pulmonary outflow** tract assessment revealed normal valve structure, laminar flow, and diameter (approx. 1:1 pa/ao ratio). No visible **pericardial** or free pleura fluid was noted. The cranial **mediastinum and pericardial and extra-cardiac regions** were free of masses in the visible window.

Urinary System

The urinary bladder, trigone, cystourethral junction, and visible pelvic urethra to a depth of 2.0 cm exhibited normal thickness and tone. Anechoic urine was present in the lumen with no uroliths or sediment. The ureteral papillae were normal. The ureters were not visible which is normal. No evidence of inflammatory or neoplastic changes was noted.



PATIENT

Winnie Ezhov

The visualized left and right uterine horns exhibited mild prominent size with mild prominent walls. Segmental primarily mild luminal fluid accumulation in the left and right uterine horns was noted. The uterine fluid was primarily anechoic with potential for mild echogenic changes suggestive of potential mild fluid cellularity. No overt uterine neoplastic criteria was noted, which is thought unlikely. The uterus measured 1.4 cm in diameter. No overt pathology was noted in the area of the left and right ovaries.

SPECIES

Canine

Normal size and margination were present in the kidneys. A normal 1:3 cortex / medulla ratio was maintained. The medulla and cortices were uniform in texture with some increased echogenicity and mild loss of corticomedullary symmetry and definition expected for the age of the patient. No evidence of pelvic dilation was present. The left kidney measured 3.9 cm in length. The right kidney measured 4.0 cm in length.

BREED

Miniature Pinscher

SEX

F

Adrenal Glands

The left adrenal gland was uniform in size and contour with a uniformly hypoechoic parenchyma. The left adrenal gland measured 1.6 cm length x 0.5 cm width at the caudal pole. The right adrenal gland was uniform in size and contour with a uniformly hypoechoic parenchyma. The right adrenal gland measured 1.5 cm length x 0.34 cm width at the caudal pole.

AGE

2010

Spleen

The spleen exhibited primarily finely textured parenchyma which was hyperechoic to the liver and renal cortical parenchyma. Mild generalized parenchyma heterogeneity was present without evidence of nodular changes. The capsule was smooth and regular without apparent expansion. The splenic vasculature at the hilus was normal in volume with no evidence of congestion or thrombosis. The parenchymal heterogeneity is likely consistent with benign changes such as extramedullary hematopoiesis or age-related remodeling with minor potential for inflammatory or neoplastic disease.

WEIGHT

14.8

Liver/ Gallbladder

The liver was subjectively normal in size, structure, and contour. The liver parenchyma was mildly nonuniform and hypoechoic to the spleen with a moderate coarse echotexture and subjective mild to benign parenchymal remodeling. The hepatic and portal vasculature were normal in appearance without signs of congestion. The gallbladder was non-distended in size with thin walls and primarily anechoic luminal content. The cystic and common bile ducts were normal.

INTERPRETED BY

R. McKenzie Daniel,
 DVM, DABVP
 (Canine and Feline)

IMAGING PERFORMED BY

Rebekah Jakum, CVT
 ARDMS/RVT

HOSPITAL NAME

Leighton AH

Gastrointestinal

The stomach presented intact wall layering with a normal wall layer ratio. The lumen of the stomach was empty with no signs of ileus, obstruction, or foreign material.

REFERRING VET

Dr. Mriss

The small intestine presented intact wall layering with 1:3 muscularis/mucosa ratio. The lumen of the small intestine was empty with no signs of ileus, obstruction, or foreign material.

INVOICE

15473

Normal visible colon wall layers were present with apparent formed feces in lumen.

DATE

11/15/22



PATIENT *Pancreas*

Winnie Ezhov The parenchyma of the left limb, body, and right limb of the pancreas presented isoechoic to the adjacent omental fat. A normal curvilinear capsule contour of the pancreas was present. The visible pancreatic duct was normal. No signs of active inflammation or neoplastic disease were evident.

SPECIES

Canine

Free Abdomen

No overt lymphadenopathy or peritoneal effusion was present.

BREED

Miniature Pinscher

ULTRASONOGRAPHIC FINDINGS

SEX

F

- Normal echocardiogram
- Mild age-related renal changes
- Prominent uterus exhibiting segmental primarily mild anechoic luminal fluid exhibiting minor fluid echogenic changes - potential emerging endometritis or pyometra
- Minor hepatic parenchymal remodeling - benign

AGE

2010

INTERPRETATION OF THE FINDINGS & FURTHER RECOMMENDATIONS

WEIGHT

14.8

Overtly normal cardiac structure and function without evidence of clinical issues such as left or right chamber enlargement, LV systolic dysfunction, or overt evidence of cor pulmonale / pulmonary hypertension, given lack of RA/RV enlargement or evidence of hepatic congestive criteria. The cardiac presentation was not overtly consistent with primary cardiac disease as an underlying or primary contributing factor to the patient's respiratory abnormalities. Primary upper or lower airway disease or other noncardiogenic cause is likely. No overt indication for cardiac medications, given no evidence of structural or functional cardiomyopathy or overtly clinical pulmonary hypertension. As-needed respiratory therapy is recommended. Radiology review of thoracic radiographs if not done could be considered. No overt cardiac anesthetic contraindications. The following anesthetic protocol may be considered.

INTERPRETED BY

R. McKenzie Daniel,
DVM, DABVP
(Canine and Feline)

Close monitoring for clinical signs consistent with pyometra i.e., fever, vaginal discharge, and/or potential sonographic monitoring vs. prophylactic ovariohysterectomy could be considered.

IMAGING PERFORMED BY

Rebekah Jakum, CVT
ARDMS/RVT

HOSPITAL NAME

Leighton AH

Suggested anesthetic protocol may include opioid or Benzodiazepine pre-med, induction with Propofol or Alfaxalone, and appropriate gas anesthesia with avoidance of alpha 2 agonists.

REFERRING VET

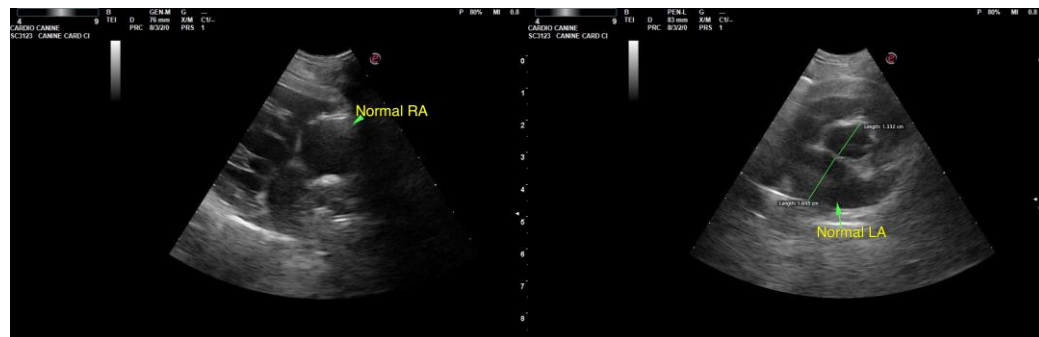Dr. Mriss

INVOICE

15473

DATE

11/15/22





PATIENT

Winnie Ezhov

SPECIES

Canine

BREED

Miniature Pinscher

SEX

F

AGE

2010

WEIGHT

14.8

INTERPRETED BY

R. McKenzie Daniel,
DVM, DABVP
(Canine and Feline)

IMAGING PERFORMED BY

Rebekah Jakum, CVT
ARDMS/RVT

HOSPITAL NAME

Leighton AH

REFERRING VET

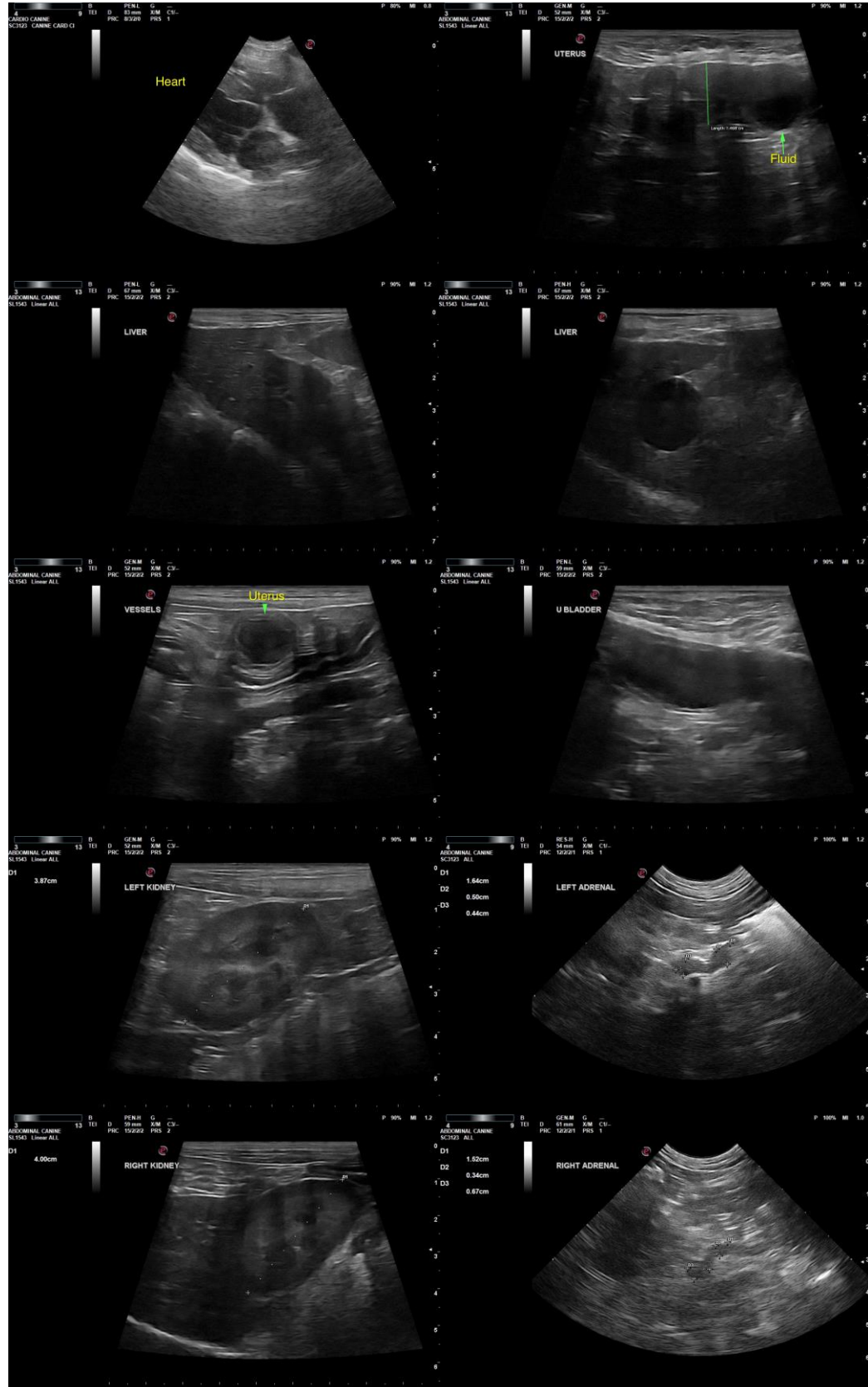
Dr. Mriss

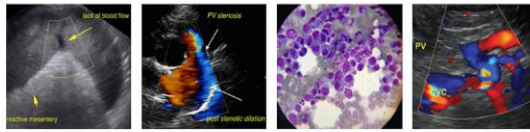
INVOICE

15473

DATE

11/15/22





PATIENT

Winnie Ezhov

The information and recommendations provided are based on the images presented by the referring veterinarian/sonographer. No evaluation can be communicated regarding pathology that was not visible in the image/video clips provided.

SPECIES

Canine

Thank you for this referral. If the clinical or image interpretation does not parallel your findings or if I can be of any further assistance, please contact me.

BREED

Miniature Pinscher

R. McKenzie Daniel, DVM, DABVP (Canine/Feline Practice)
mac.daniel@sonopath.com

SEX

F

AGE

2010

WEIGHT

14.8

INTERPRETED BY

R. McKenzie Daniel,
DVM, DABVP
(Canine and Feline)

**IMAGING
PERFORMED BY**

Rebekah Jakum, CVT
ARDMS/RVT

HOSPITAL NAME

Leighton AH

REFERRING VET

Dr. Mriss

INVOICE

15473

DATE

11/15/22