



PATIENT

Emily Mussen

SPECIES

Canine

BREED

Pug

SEX

FS

AGE

13 years

WEIGHT

19.81 lbs.

INTERPRETED BY

R. McKenzie Daniel,
DVM, DABVP
(Canine and Feline)

IMAGING PERFORMED BY

Jenna Walsh, CVT

HOSPITAL NAME

The Ark VC

REFERRING VET

Dr. Mercer

INVOICE

12616

DATE

11/15/21

PRESENTING CLINICAL SIGNS

Emily has NOT started prednisone yet, owner's are waiting for results from US. Mass already diagnosed as MCT, P had MCT removed from same area previously. Screening for systemic involvement MCT neoplasia.

ULTRASONOGRAPHIC EXAMINATION OF THE ABDOMEN

Urinary System

The urinary bladder, trigone, cystourethral junction, and visible pelvic urethra to a depth of 3.0 cm exhibited normal thickness and tone. Anechoic urine was present in the lumen with no uroliths or sediment. The ureteral papillae were normal. The ureters were not visible which is normal. No evidence of inflammatory or neoplastic changes was noted.

Multiple, mildly prominent to nonhomogeneous medial iliac lymph nodes were present adjacent to the iliac trifurcation. These lymph nodes exhibited primarily and subjectively maintained width: length ratio (<0.5). Subtle evidence of perilymphatic reactivity was present. An example measured 2.4 cm x 0.84 cm.

Normal size and margination were present in the kidneys. A normal 1:3 cortex / medulla ratio was maintained. The medulla and cortices were uniform in texture with some increased echogenicity and loss of corticomedullary symmetry and definition expected for the age of the patient. No evidence of pelvic dilation was present. The left kidney measured 4.5 cm in length. The right kidney measured 4.4 cm in length.

Adrenal Glands

The bilateral adrenal glands were normal in size. Mild parenchyma heterogeneity and mild capsule asymmetry was present without suspicion for overt neoplasia. The left adrenal gland measured 1.9 cm length x 0.41 cm width in the caudal pole. The right adrenal gland measured 1.3 cm length x 0.41 cm width in the caudal pole.

Spleen

The spleen exhibited a finely textured and homogenous parenchyma which was hyperechoic to the liver and renal cortical parenchyma. The capsule was smooth and regular without apparent expansion. The splenic vasculature at the hilus was normal in volume with no evidence of congestion or thrombosis. Acute to chronic inflammatory, neoplastic, or benign parenchyma changes were not noted.

Liver/ Gallbladder

The liver was subjectively normal in size, structure, and contour. The liver parenchyma was mildly nonuniform and hypoechoic to the spleen with a moderate coarse echotexture and subjective mild to benign parenchymal remodeling. The hepatic and portal vasculature were normal in appearance



PATIENT

Emily Mussen

SPECIES

Canine

BREED

Pug

SEX

FS

AGE

13 years

WEIGHT

19.81 lbs.

INTERPRETED BY

R. McKenzie Daniel,
DVM, DABVP
(Canine and Feline)

IMAGING PERFORMED BY

Jenna Walsh, CVT

HOSPITAL NAME

The Ark VC

REFERRING VET

Dr. Mercer

INVOICE

12616

DATE

11/15/21

without signs of congestion. The gallbladder was non-distended in size with thin walls and primarily anechoic luminal content. The cystic and common bile ducts were normal.

Gastrointestinal

The stomach presented intact wall layering with a normal wall layer ratio. The lumen of the stomach was empty with no signs of ileus, obstruction, or foreign material.

The small intestine presented intact wall layering with 1:3 muscularis/mucosa ratio. The lumen of the small intestine was empty with no signs of ileus, obstruction, or foreign material.

Normal visible colon wall layers were present with apparent formed feces in lumen.

Pancreas

The parenchyma of the left limb, body, and right limb of the pancreas presented isoechoic to the adjacent omental fat. A normal curvilinear capsule contour of the pancreas was present. The visible pancreatic duct was normal. No signs of active inflammation or neoplastic disease were evident.

Free Abdomen

No other evidence of additional or concurrent peritoneal lymphadenopathy, masses, or peritoneal effusion was noted.

ULTRASONOGRAPHIC FINDINGS

Primary Findings

- Several mildly prominent yet nonspecific medial iliac lymph nodes
- Mild age-related kidneys
- Sonographically unremarkable spleen
- Mild hepatic parenchymal remodeling - subjectively benign

INTERPRETATION OF THE FINDINGS & FURTHER RECOMMENDATIONS

The mildly prominent yet nonspecific medial iliac lymph nodes may indicate hyperplasia, mild reactive lymphadenitis although, given the patient's history, the potential for early neoplastic or metastatic lymphadenopathy is possible. No overt evidence of hepatosplenic pathology was noted. Ideally, ultrasound-guided FNA of a medial iliac lymph node is warranted for screening cytology. However, given their size, these lymph nodes may be not accessible to FNA assessment. Serial sonographic monitoring of the medial iliac lymph nodes for evidence of progressive increased size or changes in appearance with an initial recheck in 3-4 weeks would be appropriate. Screening hepatosplenic FNA using a 25-gauged needle and assuming normal clotting status could be considered.



PATIENT

Emily Mussen

SPECIES

Canine

BREED

Pug

SEX

FS

AGE

13 years

WEIGHT

19.81 lbs.

INTERPRETED BY

R. McKenzie Daniel,
DVM, DABVP
(Canine and Feline)

IMAGING PERFORMED BY

Jenna Walsh, CVT

HOSPITAL NAME

The Ark VC

REFERRING VET

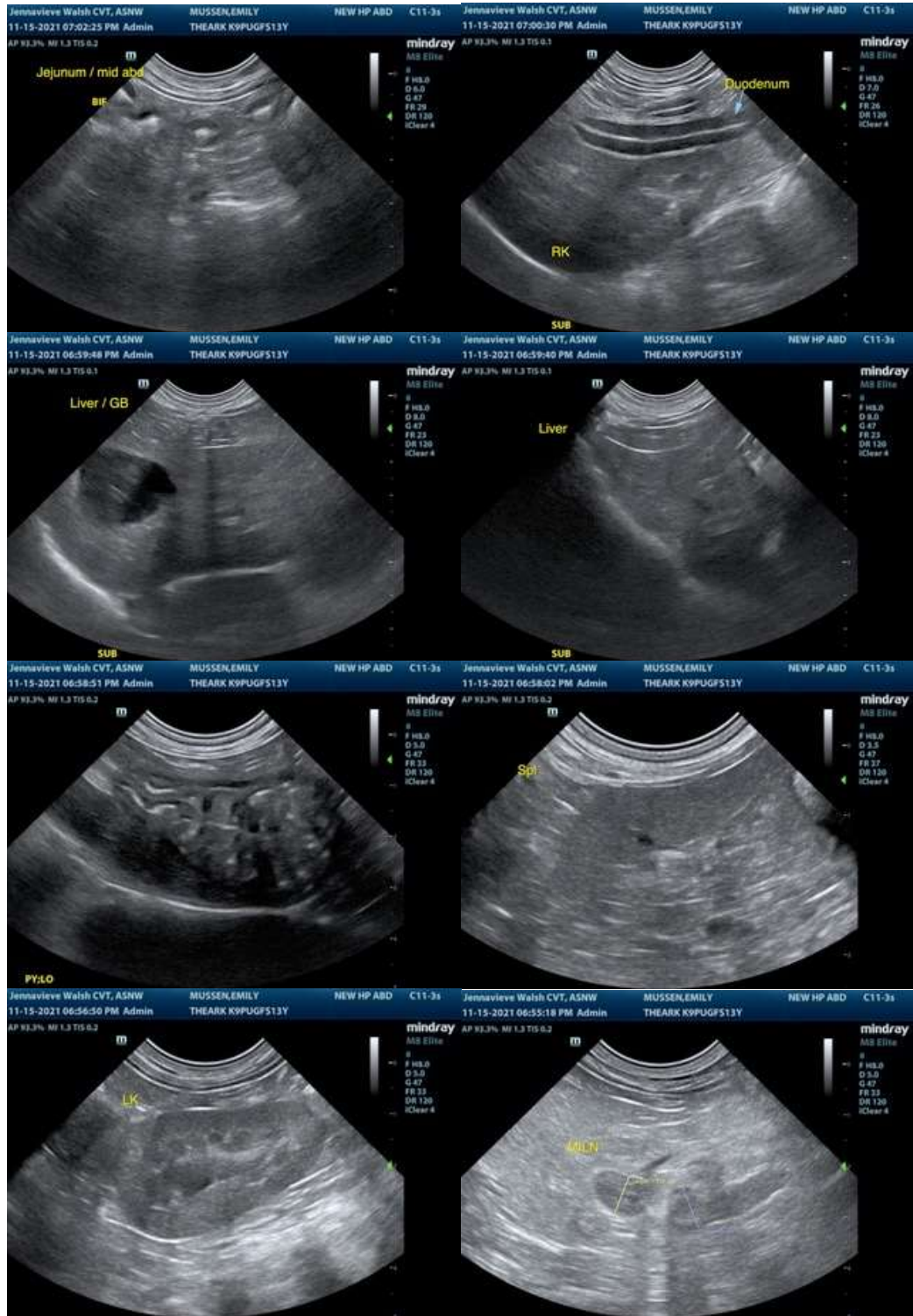
Dr. Mercer

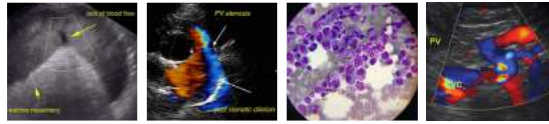
INVOICE

12616

DATE

11/15/21





PATIENT

Emily Mussen

SPECIES

Canine

BREED

Pug

SEX

FS

AGE

13 years

WEIGHT

19.81 lbs.

INTERPRETED BY

R. McKenzie Daniel,
DVM, DABVP
(Canine and Feline)

IMAGING PERFORMED BY

Jenna Walsh, CVT

HOSPITAL NAME

The Ark VC

REFERRING VET

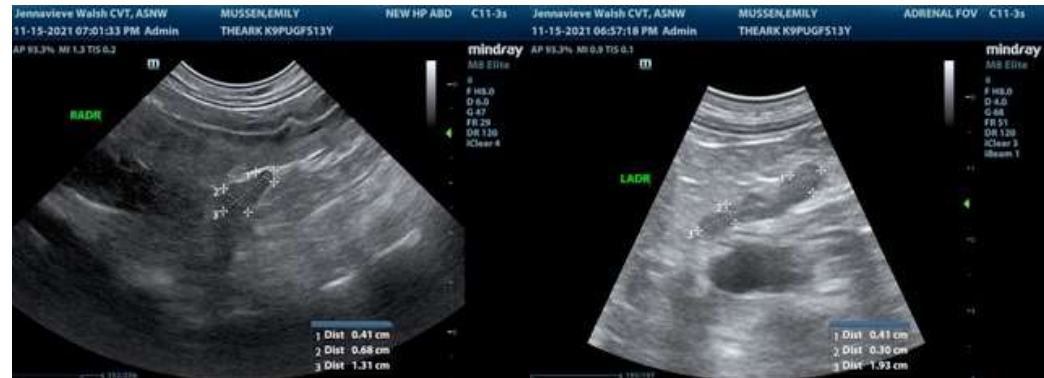Dr. Mercer

INVOICE

12616

DATE

11/15/21



The information and recommendations provided are based on the images presented by the referring veterinarian. No evaluation can be communicated regarding pathology that was not visible in the image/video clips provided.

Thank you for this referral. If the clinical or image interpretation does not parallel your findings or if I can be of any further assistance please contact me.

R. McKenzie Daniel, DVM, DABVP (Canine / Feline Practice)
info@SonoPath.com