



PATIENT

Cinnamon DeFillips

PRESENTING CLINICAL SIGNS

VPC's noted on exam and ECG. Asymptomatic Current meds: Thyrotabs 0.4mg BID
Abnormal PE/Chem/CBC/UA Results: Normal 1/20/21

SPECIES

Canine

ULTRASONOGRAPHIC EXAMINATION OF THE HEART & ABDOMEN

BREED

Boxer

SEX

FS

AGE

11 Years

WEIGHT

63.8 lbs

CANINE CARDIAC PARAMETERS	MR VMAX (m/s)	TR VMAX (m/s)	LA/AO (Boon method)	LA/AO (Heart Base; Swe)	FS (%)	EF (%)	EPSS (cm)
NORMAL PARAMETER	4.5-5.5	<2.7	1.3	<1.6	28-40	40-100	<0.6
PATIENT			1.48	1.41	33.3	63.1	0.18
CANINE CARDIAC PARAMETERS	HR (BPM)	AV VMAX (m/s)	PV MAX (m/s)	BODY WEIGHT (kg)	LA 2D short axis Base view (cm)	LVIDd Avg; 2D and m- mode short axis (cm)	LVIDs Avg; 2D and m-mode short axis (cm)
NORMAL PARAMETER	50-100	0.7-1.7	0.7-1.6	BELOW	BELOW	BELOW	BELOW
PATIENT	115	2.3	1.1		3.66	3.5	

INTERPRETED BY

R. McKenzie Daniel,
DVM, DABVP
(Canine and Feline)

IMAGING PERFORMED BY

Jessica Miller

HOSPITAL NAME

SOVA AH

REFERRING VET

Dr. Ammeraal

INVOICE

48353

DATE

11-15-21

Cardiac Presentation

The echocardiogram in this patient demonstrated normal **left atrial** size based on 3 separate methods of LA evaluation. The cranial and caudal **mitral** valve leaflets presented normal linear structure, extension in systole, and union in diastole with normal kinesis. The **left ventricle** presented thicknesses with linear contour and was not dilated nor restricted. The **myocardium** presented normal echogenicity without subjective evidence of significant fibrotic or ischemic disease. **Contractility** of the ventricular walls was adequate and in normal range for this patient evidenced by the fractional shortening measurement and subjective evaluation of the different regions of the myocardium. The **left ventricular outflow** tract demonstrated normal laminar flow and subjective structural integrity with minor nonspecific elevated LVOT velocity. The **right atrium** and auricle revealed normal size, structure and content. No evidence of masses was noted. **Tricuspid** valvular assessment demonstrated adequate linear morphology and kinesis. The **right ventricle** was of normal size (1/3 diameter of LV), chordae structure, myocardial echogenicity and thickness. **Pulmonary outflow** tract assessment revealed normal valve structure, laminar flow, and diameter (pprox..1:1 pa/ao ratio). No visible **pericardial** or free pleura fluid was noted. The cranial **mediastinum and pericardial and extra-cardiac regions** were free of masses in the visible window. Intermittent to consistent arrhythmia was present.

Urinary System

The urinary bladder, trigone, cystourethral junction, and visible pelvic urethra to a depth of 2.0 cm exhibited normal thickness and tone. Anechoic urine was present in the lumen with no uroliths or sediment. The ureteral papillae were normal. The ureters were not visible which is normal. No evidence of inflammatory or neoplastic changes were noted.

No evidence of pathology in the area of the aortic trifurcation.



PATIENT	Normal size and margination was present in the kidneys. A normal 1:3 cortex / medulla ratio was maintained. The medulla and cortices were uniform in texture with some increased echogenicity and mild loss of corticomedullary symmetry and definition expected for the age of the patient. No evidence of pelvic dilation was present. The left kidney measured 6.7 cm in length. The right kidney measured 6.8 cm in length.
Cinnamon DeFillips	
SPECIES	<i>Adrenal Glands</i>
Canine	The left adrenal gland was uniform in size and contour with a uniformly hypoechoic parenchyma. The left adrenal gland measured 2.6 cm length x 0.54 cm width at the caudal pole. The right adrenal gland was uniform in size and contour with a uniformly hypoechoic parenchyma. The right adrenal gland measured 2.6 cm length x 0.63 cm width at the caudal pole.
BREED	<i>Spleen</i>
Boxer	The spleen exhibited a finely textured and homogenous parenchyma which was hyperechoic to the liver and renal cortical parenchyma. The capsule was smooth and regular without apparent expansion. The splenic vasculature at the hilus was normal in volume with no evidence of congestion or thrombosis. No evidence of inflammatory or neoplastic splenic criteria.
SEX	<i>Liver / Gallbladder</i>
FS	The liver was subjectively normal in size, structure, and contour. The liver parenchyma was mildly nonuniform and hypoechoic to the spleen with a moderate coarse echotexture and subjective mild to benign parenchymal remodeling. The hepatic and portal vasculature were normal in appearance without signs of congestion.
AGE	The gallbladder was non-distended in size with thin walls and primarily anechoic luminal content. The cystic and common bile ducts were normal.
11 Years	
WEIGHT	<i>Gastrointestinal</i>
63.8 lbs	The stomach presented intact wall layering with a normal wall layer ratio. The lumen of the stomach contained mild to moderate echogenic, non-shadowing ingesta/chyme without signs of obstruction or foreign material.
INTERPRETED BY	The small intestine presented intact wall layering with 1:3 muscularis/mucosa ratio. The lumen of the small intestine was empty with no signs of ileus, obstruction or foreign material.
R. McKenzie Daniel, DVM, DABVP (Canine and Feline)	Normal visible colon wall layers were present with apparent formed feces in lumen.
IMAGING PERFORMED BY	<i>Pancreas</i>
Jessica Miller	The parenchyma of the left limb, body and right limb of the pancreas presented isoechoic to the adjacent omental fat. A normal curvilinear capsule contour of the pancreas was present. The visible pancreatic duct was normal. No signs of active inflammation or neoplastic disease was evident.
HOSPITAL NAME	<i>Free Abdomen</i>
SOVA AH	No evidence of intraabdominal masses, lymphadenopathy, or peritoneal effusion was present.
REFERRING VET	
Dr. Ammeraal	
INVOICE	
48353	
DATE	
11-15-21	ULTRASONOGRAPHIC FINDINGS



PATIENT

Cinnamon DeFillips

- Sonographically unremarkable abdomen for age.
- Overtly normal cardiac structure and function with intermittent to consistent arrhythmia.
- Minor elevated LVOT velocity - not considered clinically significant or suggestive of stenotic disease.

SPECIES

Canine

INTERPRETATION OF THE FINDINGS & FURTHER RECOMMENDATIONS

BREED

Boxer

No overt evidence of structural cardiomyopathy or intraabdominal abnormalities as an obvious cause of the VPC's in this patient. Concern for potential arrhythmogenic right ventricular cardiomyopathy given the breed may be warranted. Holter monitor which may be obtained through the SonoPath office for further assessment as well as cardiology consult may be considered. No indication for cardiac medications used to treat structural cardiomyopathy.

SEX

FS

AGE

11 Years

WEIGHT

63.8 lbs

INTERPRETED BY

R. McKenzie Daniel,
DVM, DABVP
(Canine and Feline)

IMAGING PERFORMED BY

Jessica Miller

HOSPITAL NAME

SOVA AH

REFERRING VET

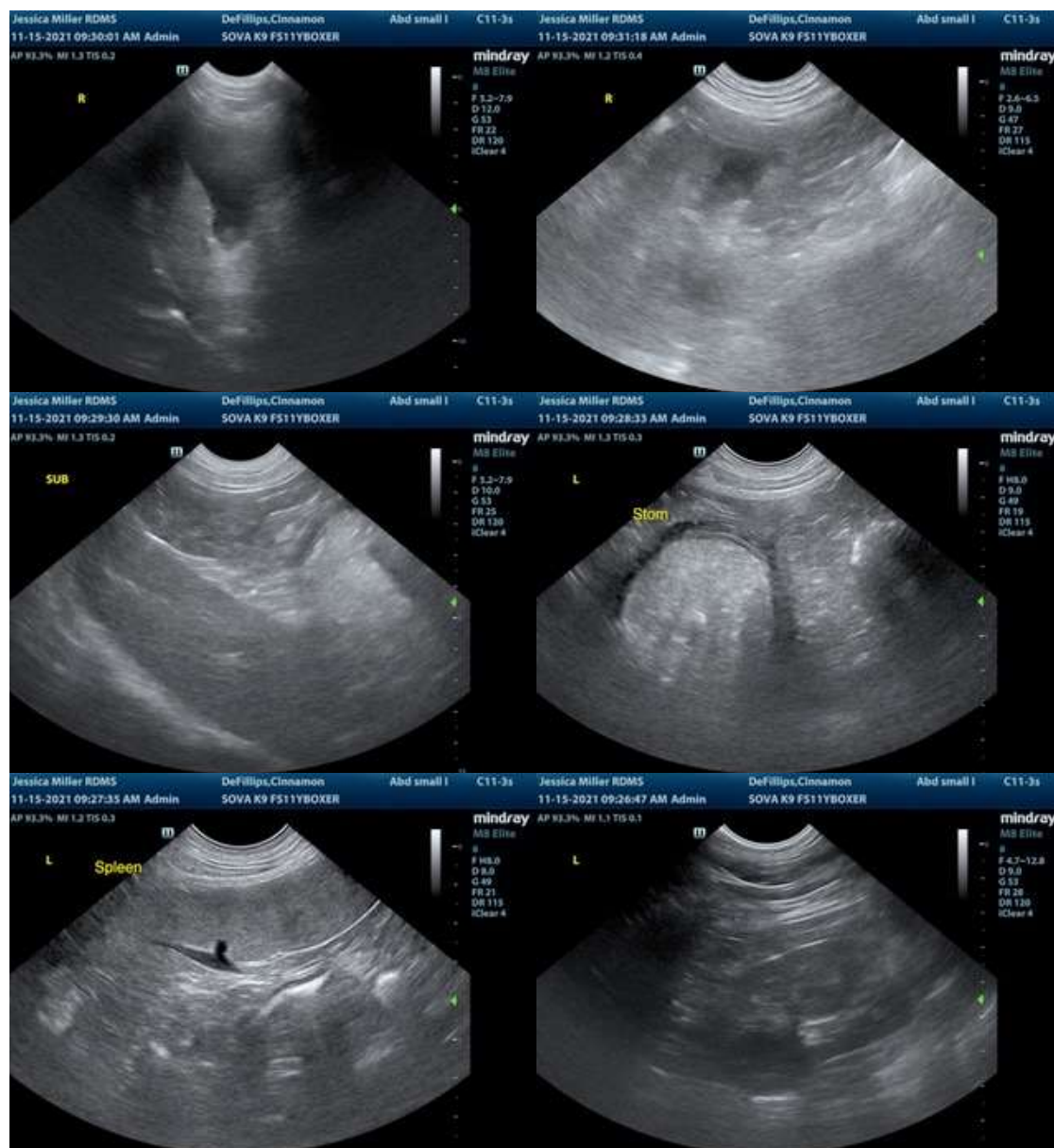
Dr. Ammeraal

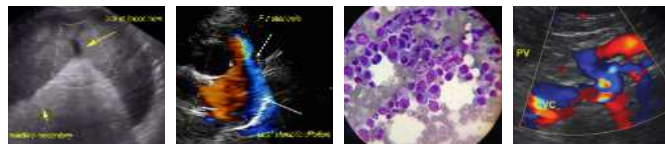
INVOICE

48353

DATE

11-15-21





PATIENT

Cinnamon DeFillips

SPECIES

Canine

BREED

Boxer

SEX

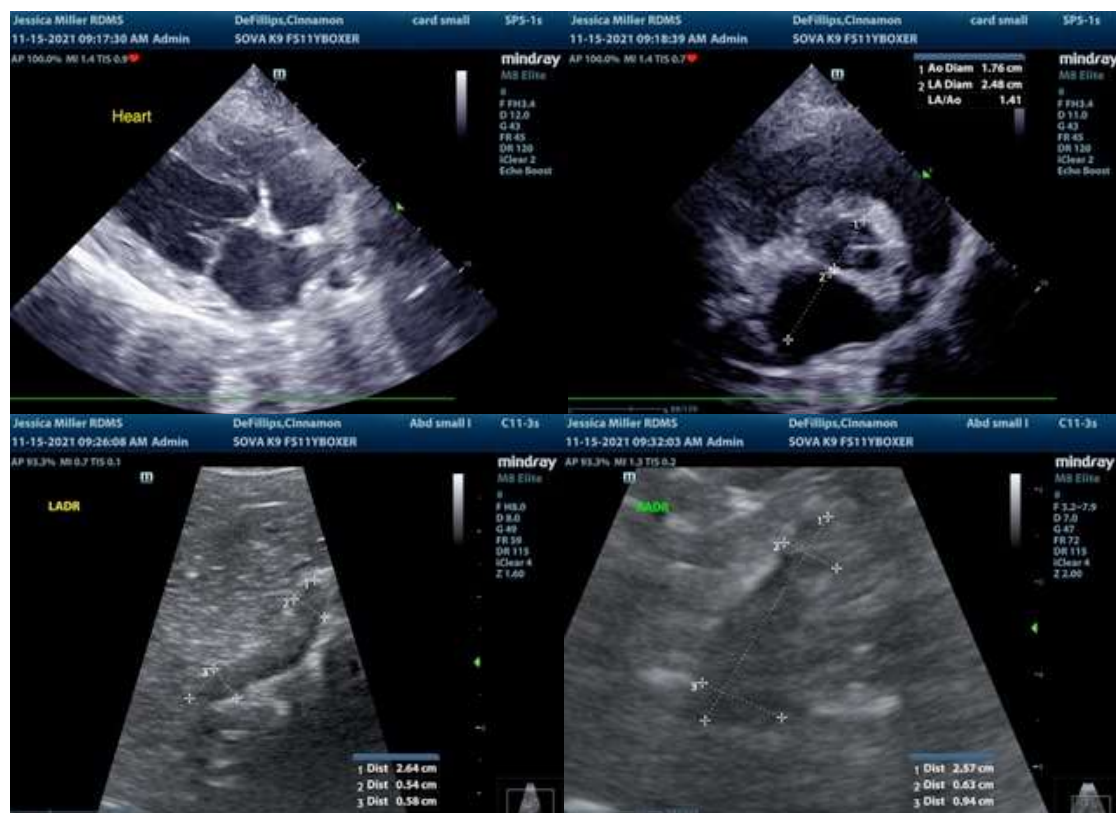
FS

AGE

11 Years

WEIGHT

63.8 lbs



INTERPRETED BY

R. McKenzie Daniel,
DVM, DABVP
(Canine and Feline)

IMAGING PERFORMED BY

Jessica Miller

HOSPITAL NAME

SOVA AH

REFERRING VET

Dr. Ammeraal

INVOICE

48353

DATE

11-15-21

The information and recommendations provided are based on the images presented by the referring veterinarian. No evaluation can be communicated regarding pathology that was not visible in the image/video clips provided.

Thank you for this referral. If the clinical or image interpretation does not parallel your findings or if I can be of any further assistance please contact me.

R. McKenzie Daniel, DVM, DABVP (Canine / Feline Practice)
info@SonoPath.com