

**PATIENT**

Ruby Hagan

**SPECIES**

Canine

**BREED**

Boston Terrier

**SEX**

Female Spayed

**AGE**

2018

**WEIGHT**

15

**INTERPRETED BY**

R. McKenzie Daniel,  
 DVM, DABVP  
 (Canine and Feline)

**IMAGING PERFORMED BY**

Rebekah Jakum, CVT,  
 ARDMS/RVT

**HOSPITAL NAME**

Aloha AH

**REFERRING VET**

Freese

**INVOICE**

12811

**DATE**

11/14/25

**PRESENTING CLINICAL SIGNS**

History: Increased urine specific gravity, proteinuria, hematuria, small liver, DJD, spondylosis

Abnormal PE/Chem/CBC/UA Results: urinalysis specific gravity 1.057, 1+ blood trace protein, UPC/UCC normal

**ULTRASONOGRAPHIC EXAMINATION OF THE ABDOMEN**

**Urinary System**

The urinary bladder, trigone, cystourethral junction, and visible pelvic urethra to a depth of 2.0 cm exhibited normal thickness and tone. Anechoic urine was present in the lumen with no uroliths or sediment. The ureteral papillae were normal. The ureters were not visible which is normal. No evidence of inflammatory or neoplastic changes were noted.

Normal size and margination were present in the kidneys. A normal 1:3 cortex / medulla ratio and normal corticomedullary definition were maintained. The echogenicity of the cortex was similar to or slightly less than normal liver parenchyma while the medulla echogenicity was hypoechoic to the cortex with no evidence of pelvic dilation. Focal to minor medullary mineral noted. The left kidney measured 4.4 cm in length. The right kidney measured 4.6 cm in length.

**Adrenal Glands**

The left adrenal gland was uniform in size and contour with a uniformly hypoechoic parenchyma. The left adrenal gland measured 0.42 cm width at the caudal pole. The right adrenal gland was uniform in size and contour with a uniformly hypoechoic parenchyma. The right adrenal gland measured 0.38 cm width at the caudal pole.

**Spleen**

The spleen exhibited a finely textured and homogenous parenchyma which was hyperechoic to the liver and renal cortical parenchyma. The capsule was smooth and regular without apparent expansion. The splenic vasculature at the hilus was normal in volume with no evidence of congestion or thrombosis. Acute to chronic inflammatory, neoplastic, or benign parenchyma changes were not noted.

**Liver**

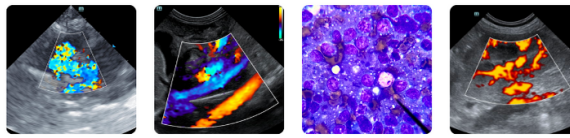
The liver was subjectively normal in size, structure, and contour with adequate vascular volume. The liver parenchyma was uniform and hypoechoic to the spleen with a mild coarse echotexture. The hepatic and portal vasculature were normal in appearance without signs of congestion. The gallbladder was non-distended in size with thin walls and primarily anechoic luminal content. The cystic and common bile ducts were normal.

**Gastrointestinal**

The stomach presented intact wall layering with a normal wall layer ratio. The lumen of the stomach was empty with no signs of ileus, obstruction or foreign material.

The small intestine presented intact wall layering with 1:3 muscularis/mucosa ratio. The lumen of the small intestine was empty with no signs of ileus, obstruction or foreign material.

Normal visible colon wall layers were present with apparent formed feces in lumen.



**PATIENT**

Ruby Hagan

**SPECIES**

Canine

**BREED**

Boston Terrier

**SEX**

Female Spayed

**AGE**

2018

**WEIGHT**

15

**INTERPRETED BY**

R. McKenzie Daniel,  
 DVM, DABVP  
 (Canine and Feline)

**IMAGING PERFORMED BY**

Rebekah Jakum, CVT,  
 ARDMS/RVT

**HOSPITAL NAME**

Aloha AH

**REFERRING VET**

Freese

**INVOICE**

12811

**DATE**

11/14/25

**Pancreas**

The parenchyma of the left limb, body and right limb of the pancreas presented isoechoic to the adjacent omental fat. A normal curvilinear capsule contour of the pancreas was present. The visible pancreatic duct was normal. No signs of active inflammation or neoplastic disease was evident.

**Free Abdomen**

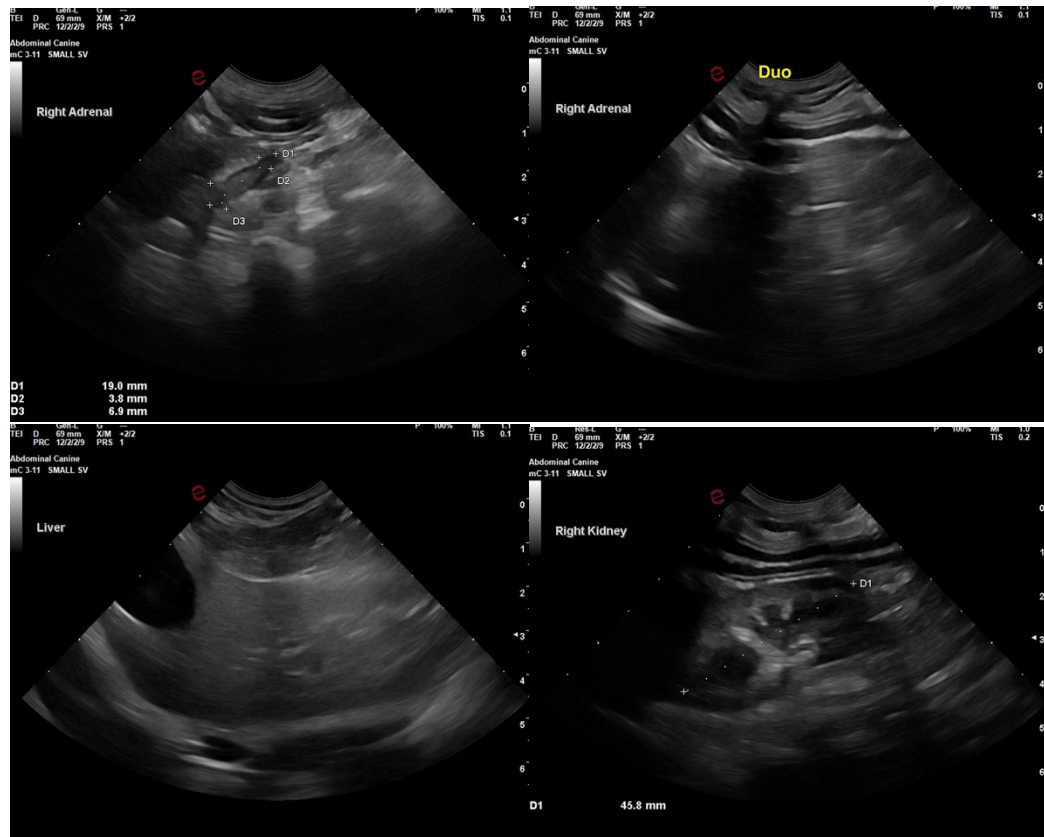
No overt lymphadenopathy or peritoneal effusion was present.

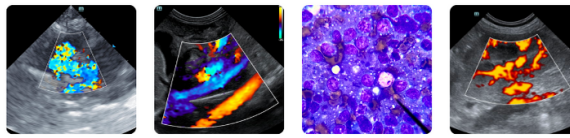
**ULTRASONOGRAPHIC FINDINGS**

- Normal kidneys with focal to minor medullary mineral
- Normal urinary bladder
- Normal volume liver

**INTERPRETATION OF THE FINDINGS & FURTHER RECOMMENDATIONS**

No evidence of significant visceral, specifically hepatic or urinary tract pathology. Given previous diagnostics, continued monitoring of urinalysis is recommended.





**PATIENT**

Ruby Hagan

**SPECIES**

Canine

**BREED**

Boston Terrier

**SEX**

Female Spayed

**AGE**

2018

**WEIGHT**

15

**INTERPRETED BY**

R. McKenzie Daniel,  
 DVM, DABVP  
 (Canine and Feline)

**IMAGING PERFORMED BY**

Rebekah Jakum, CVT,  
 ARDMS/RVT

**HOSPITAL NAME**

Aloha AH

**REFERRING VET**

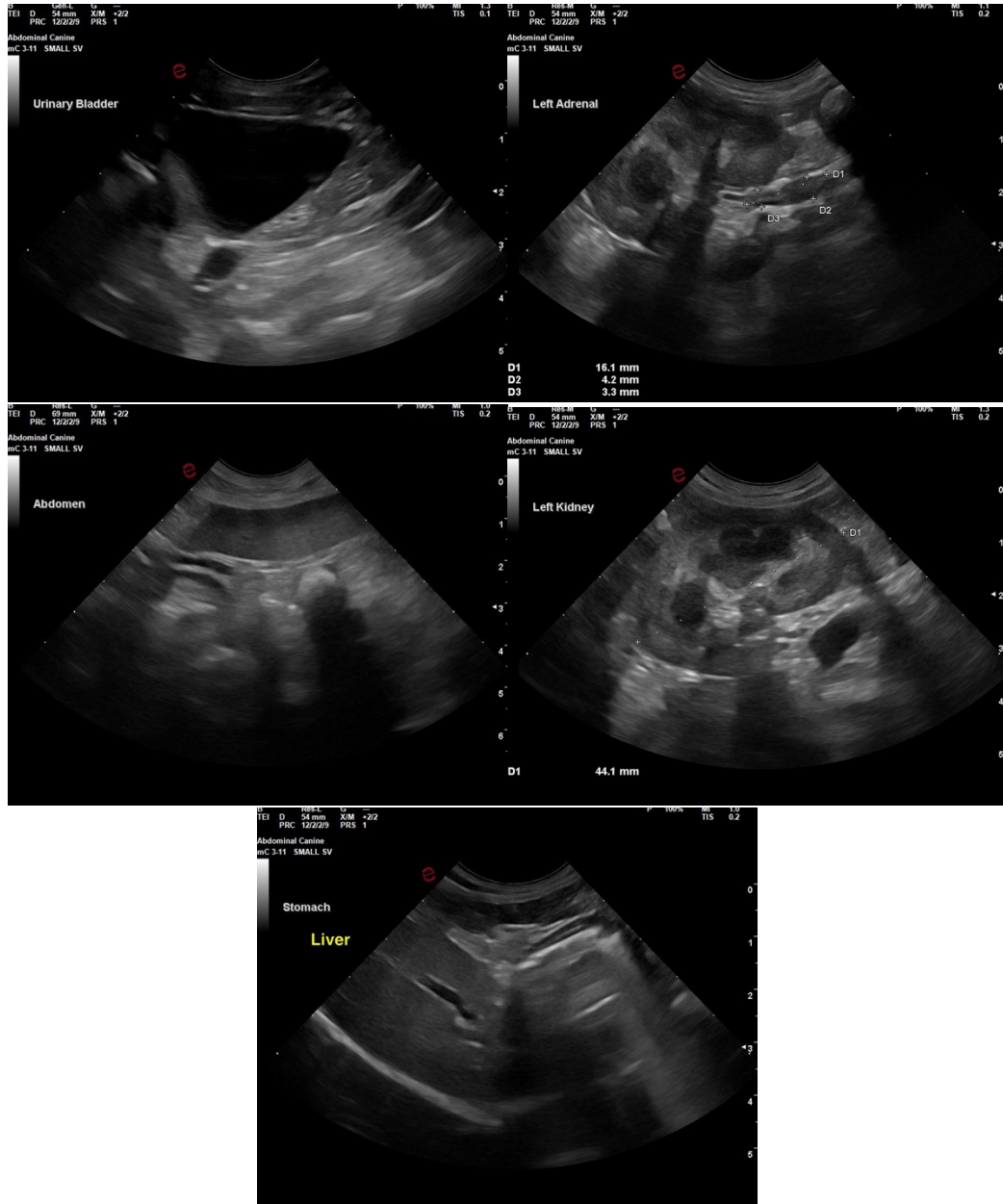
Freese

**INVOICE**

12811

**DATE**

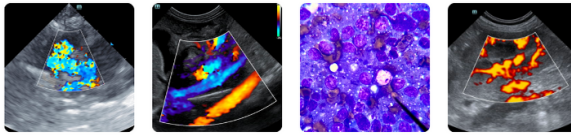
11/14/25



The information and recommendations provided are based on the images presented by the referring veterinarian/sonographer. No evaluation can be communicated regarding pathology that was not visible in the image/video clips provided.

Thank you for this referral. If the clinical or image interpretation does not parallel your findings or if I can be of any further assistance, please contact me.

R. McKenzie Daniel, DVM, DABVP (Canine / Feline Practice)



**PATIENT**

[info@sonopath.com](mailto:info@sonopath.com)

Ruby Hagan

**SPECIES**

Canine

**BREED**

Boston Terrier

**SEX**

Female Spayed

**AGE**

2018

**WEIGHT**

15

**INTERPRETED BY**

R. McKenzie Daniel,  
DVM, DABVP  
(Canine and Feline)

**IMAGING  
PERFORMED BY**

Rebekah Jakum, CVT,  
ARDMS/RVT

**HOSPITAL NAME**

Aloha AH

**REFERRING VET**

Freese

**INVOICE**

12811

**DATE**

11/14/25