



PATIENT

Max DeVito

SPECIES

Canine

BREED

Miniature Poodle

SEX

Male Neutered

AGE

11 yrs

WEIGHT

14.8

INTERPRETED BY

R. McKenzie Daniel,
DVM, DABVP
(Canine and Feline)

IMAGING PERFORMED BY

Dr. Carlos Abdul-Chani

HOSPITAL NAME

Byram AH

REFERRING VET

Dr. Carlos Abdul-Chani

INVOICE

12795

DATE

11/13/25

PRESENTING CLINICAL SIGNS

History: Diarrhea, hypoalbuminemia

Abnormal PE/Chem/CBC/UA Results: CBC = Normal; Albumin = 1.6 g/dl Rest of panel is normal.

Abnormal U/A Findings: Pending Urine Specific Gravity: 1.050

ULTRASONOGRAPHIC EXAMINATION OF THE ABDOMEN

Urinary System

The urinary bladder, trigone, cystourethral junction, and visible pelvic urethra exhibited normal thickness and tone. Anechoic urine was present in the lumen with no uroliths or sediment. The ureteral papillae were normal. The ureters were not visible which is normal. No evidence of inflammatory or neoplastic changes were noted.

The residual prostate was free of pathology.

Normal size and margination was present in the kidneys. A normal 1:3 cortex / medulla ratio was maintained. The medulla and cortices were uniform in texture with some increased echogenicity and mild loss of corticomedullary symmetry and definition expected for the age of the patient. No evidence of pelvic dilation was present. Pinpoint to minor medullary mineral was present. The left kidney measured 4.6 cm in length. The right kidney measured 4.6 cm in length.

Adrenal Glands

The bilateral adrenal glands were normal in size. Mild parenchyma heterogeneity and mild capsule asymmetry was present without suspicion for overt neoplasia. The left adrenal gland measured 0.51 cm width in the caudal pole. The right adrenal gland measured 0.50 cm.

Spleen

The spleen exhibited a finely textured and homogenous parenchyma which was hyperechoic to the liver and renal cortical parenchyma. The capsule was smooth and regular without apparent expansion. The splenic vasculature at the hilus was normal in volume with no evidence of congestion or thrombosis. Acute to chronic inflammatory, neoplastic, or benign parenchyma changes were not noted.

Liver

The liver was subjectively normal in size, structure, and contour. The liver parenchyma was uniform and hypoechoic to the spleen with a mild coarse echotexture. The hepatic and portal vasculature were normal in appearance without signs of congestion. The gallbladder was non distended in size with mild, non-dependent, non-organized, echogenic, nonmineralized biliary sludge. No evidence of gallbladder wall edema present. The cystic duct and common bile ducts were normal without evidence of dilation.

Gastrointestinal

The stomach presented intact wall layering with a normal wall layer ratio. The lumen of the stomach contained mild to moderate, variably echogenic, non-shadowing ingesta exhibiting mildly progressive distal acoustic shadowing most consistent with food echogenicity.



PATIENT

Max DeVito

SPECIES

Canine

BREED

Miniature Poodle

SEX

Male Neutered

AGE

11 yrs

WEIGHT

14.8

INTERPRETED BY

R. McKenzie Daniel,
DVM, DABVP
(Canine and Feline)

IMAGING PERFORMED BY

Dr. Carlos Abdul-Chani

HOSPITAL NAME

Byram AH

REFERRING VET

Dr. Carlos Abdul-Chani

INVOICE

12795

DATE

11/13/25

The small intestine presented intact prominent wall layering owing to subjective prominent intestinal mucosa. Mild increased generalized mucosa echogenicity. Small intestine wall measured 0.41 cm. The lumen of the small intestine was empty with no signs of ileus, obstruction or foreign material.

Normal visible colon wall layers were present with apparent soft feces in lumen.

Pancreas

The parenchyma of the left limb, body and right limb of the pancreas presented isoechoic to the adjacent omental fat. A normal curvilinear capsule contour of the pancreas was present. The visible pancreatic duct was normal. No signs of active inflammation or neoplastic disease was evident.

Free Abdomen

Generalized mild increased omental echogenicity with mild volume peritoneal effusion. Intermittent, mildly prominent, non-homogeneous mesenteric lymph nodes with an example measuring 1.0 cm in diameter.

ULTRASONOGRAPHIC FINDINGS

- PLE intestine pattern
- Mild, progressively shadowing gastric ingesta suggestive of food echogenicity
- Associated mild volume peritoneal effusion and mild omental hyperechogenicity
- Age-related renal changes with mild medullary mineral
- Sonographically unremarkable normal volume liver
- Mild gallbladder debris (non-mucocele)

INTERPRETATION OF THE FINDINGS & FURTHER RECOMMENDATIONS

Correlation with pending urinalysis to ensure no evidence of proteinuria and a contributing factor is recommended. IBD or other inflammatory enteropathy, lymphangiectasia or potential infiltrative intestinal disease, all potentials. A GI panel to include PLI/TLI/Cobalamin/Folate and screening fecal analysis, if not done, is recommended. Definitive diagnosis would require intestinal biopsies for histopathology yet contraindicated given albumin level less than 2.0. Empirical therapy for protein losing enteropathy with clinical and as needed sonographic monitoring is recommended.

Part or all of this protocol may be considered based on your clinical impression of the patient:

OBJECTIVE: keep albumin levels > 2 g/dl, avoid thromboembolism and cavitory effusions, monitor concurrent PLN (Wheaton Terrier PLE/PLN) and liver disease:

Plasma 10 mL / kilogram IV over 4 hours

Or **Human albumin** 2 ml/kg/h over 10 hours. Total daily volume 20.l/kg/day

And Colloids/Hetastarch

10 to 20 mL per kilogram per day and dogs

10 to 15 mL per kilogram per day cats

(Can bolus first 1/3 of dose over 15 minutes)

& maintain on LRS maintenance otherwise.

Famotidine 1 mg/kg Iv Im po dc Sid /bid

Sucralfate 0.5-1 g po TID dogs, 0.5 g bid cats in slurry Or **Misoprostol** 1-5 ug/kg po TID

Diet: Highly digestible high-quality protein, low fiber, low fat diet (< 15% of dry matter). Hydrolyzed protein or novel protein. Purina HA or Royal Canine HP or similar.



PATIENT

Max DeVito

SPECIES

Canine

BREED

Miniature Poodle

SEX

Male Neutered

AGE

11 yrs

WEIGHT

14.8

INTERPRETED BY

R. McKenzie Daniel,
DVM, DABVP
(Canine and Feline)

IMAGING PERFORMED BY

Dr. Carlos Abdul-Chani

HOSPITAL NAME

Byram AH

REFERRING VET

Dr. Carlos Abdul-Chani

INVOICE

12795

DATE

11/13/25

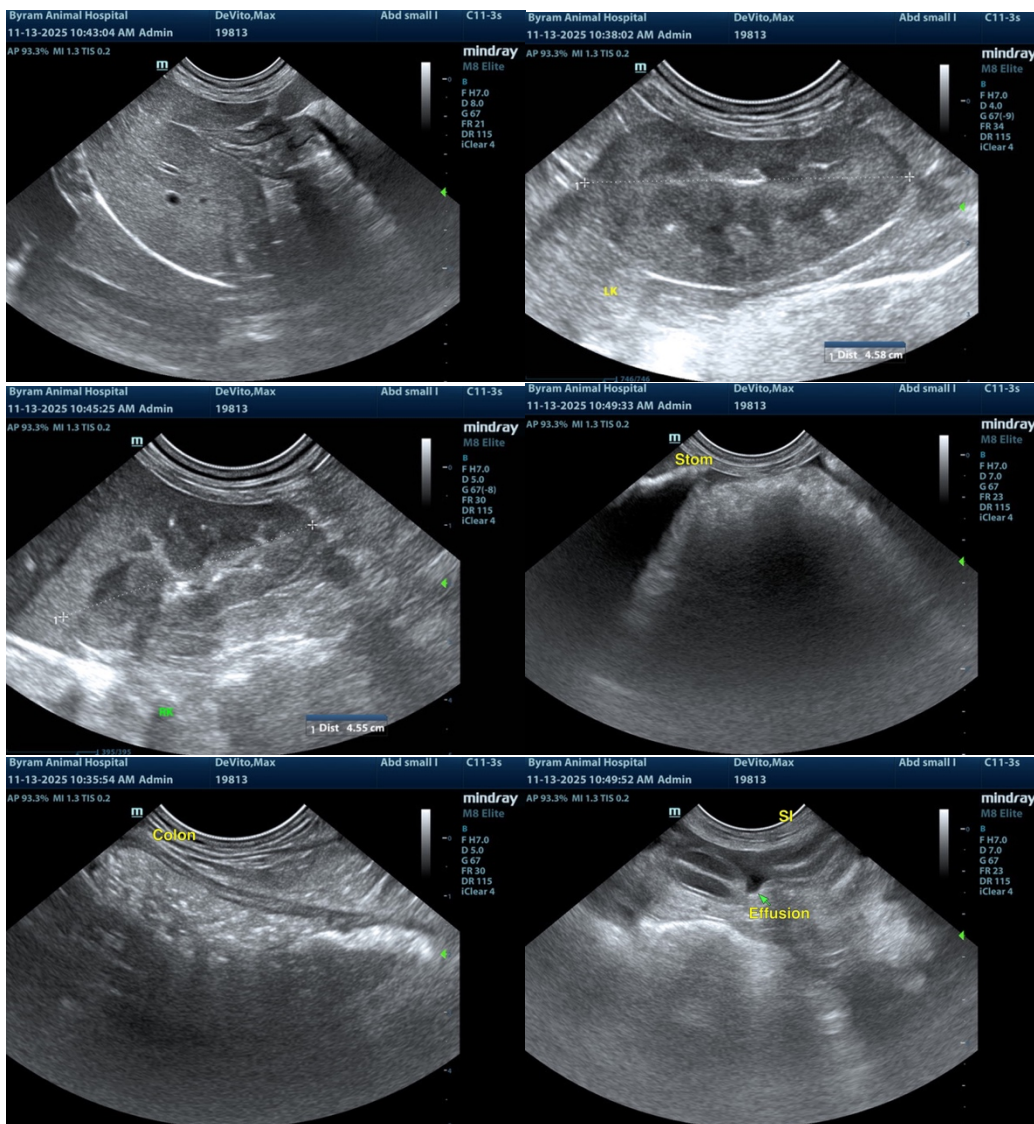
Prednisone or prednisolone 2 mg/kg bid x 3-5 days then 2 mg/kg sid. **Chlorambucil** in refractive severe IBD/alimentary lymphoma cases (monitor cbc for rare bone marrow suppression) 4 mg/m² Q 24-48 hours.

Cobalamin (B12) 250-1500 ug/dog weekly x 6 weeks.

Calcium supplementation if necessary.

Aspirin 0.5-1 mg/kg/day or **Clopidrel (Plavix)** 1-5 mg/kg/day.

High colony count probiotic, i.e. Provoiable or similar.





PATIENT

Max DeVito

SPECIES

Canine

BREED

Miniature Poodle

SEX

Male Neutered

AGE

11 yrs

WEIGHT

14.8

INTERPRETED BY

R. McKenzie Daniel,
DVM, DABVP
(Canine and Feline)

IMAGING PERFORMED BY

Dr. Carlos Abdul-Chani

HOSPITAL NAME

Byram AH

REFERRING VET

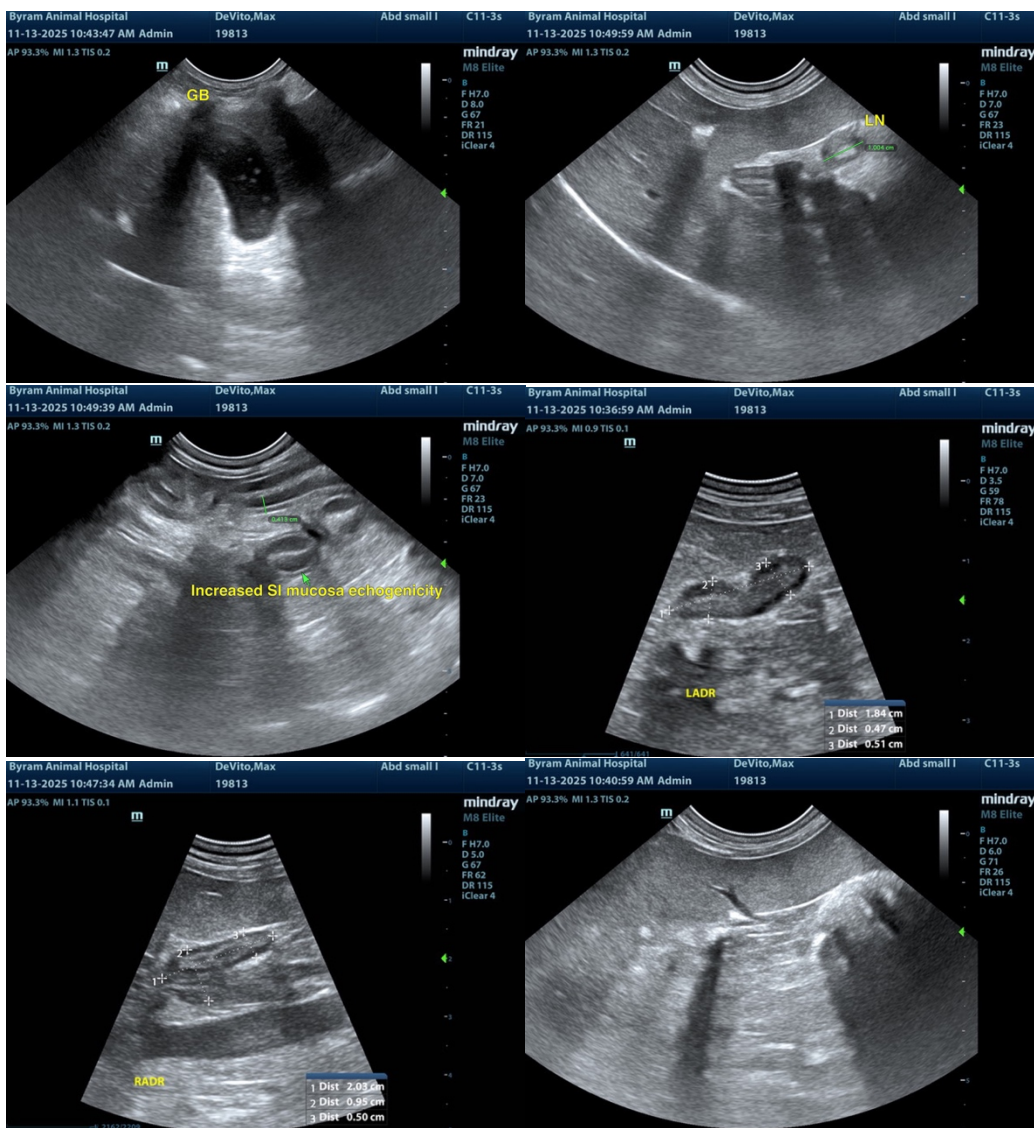
Dr. Carlos Abdul-Chani

INVOICE

12795

DATE

11/13/25



The information and recommendations provided are based on the images presented by the referring veterinarian/sonographer. No evaluation can be communicated regarding pathology that was not visible in the image/video clips provided.

Thank you for this referral. If the clinical or image interpretation does not parallel your findings or if I can be of any further assistance, please contact me.

R. McKenzie Daniel, DVM, DABVP (Canine / Feline Practice)

info@sonopath.com