

PATIENT PRESENTING CLINICAL SIGNS

Salvador Wherley
History: Vomiting, lethargy, right lung consolidation vs effusion, decreased appetite, tachypnea
Medication: Lasix 12.5 BID

SPECIES
WBC 6.8 w/normal differential, Hematocrit 45%

Feline
Unremarkable limited chemistry panel

BREED ULTRASONOGRAPHIC EXAMINATION OF THE CHEST

Domestic Shorthair
Subjective evaluation of the heart revealed overtly normal cardiac structure and function without evidence of left or right heart chamber enlargement or systolic dysfunction. Potential for very minor pericardial free fluid present although not definitive. If present, this did not appear to be affecting cardiac function.

SEX
Neutered Male
Sonographic evaluation of the right thorax revealed sectorial mild nonhomogeneous yet primarily echogenic lung tissue. Focal discreet hypoechoic to nonhomogeneous nodular lesion within the echogenic lung was present measuring 1.5 cm in diameter. Mild to moderately sized pocket of anechoic free fluid present in the subjective caudal lung and adjacent to the diaphragm with probable cranial liver visualized in several video clips. The free fluid did not appear to be within the cranial abdominal cavity.

AGE
7 years
Sonographic evaluation of the left lung revealed normal curvilinear lung surface without overt evidence of concurrent left thoracic pathology.

WEIGHT ULTRASONOGRAPHIC FINDINGS

- 20 Pounds
- Right sided primarily homogeneous to echogenic lung with suspect focal discreet consolidation.
 - Right likely caudal thoracic fluid pocket / pleural effusion.
 - Overtly normal cardiac structure and function, potential for minor pericardial effusion although not considered clinically significant if present.

INTERPRETED BY

R. McKenzie Daniel,
DVM, DABVP
(Canine and Feline)

INTERPRETATION OF THE FINDINGS & FURTHER RECOMMENDATIONS

IMAGING PERFORMED BY

Rebekah Jakum, CVT
ARDMS/RVT

Although sampling is required for further definition, primary concern for right sided pneumonia with focal consolidation (infectious, suppurative, pyogranulomatous, or other). Other etiologies including neoplasia are possible yet thought less likely at this time.

HOSPITAL NAME

Annville-Cleona VA

Assuming normal clotting status, ultrasound guided FNA of the abnormal lung and sampling of the fluid for cytology and culture and sensitivity warranted. Empirical therapy for pneumonia (respiratory support, antibiotics, coupage) would be appropriate with monitoring of clinical response and thoracic radiographs.

REFERRING VET

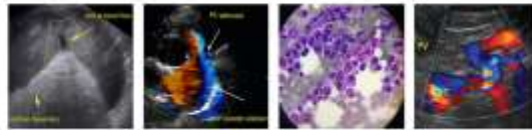
Dr. Bardsley

INVOICE

48306

DATE

11.12.2021



PATIENT

Salvador Wherley

SPECIES

Feline

BREED

Domestic Shorthair

SEX

Neutered Male

AGE

7 years

WEIGHT

20 Pounds

INTERPRETED BY

R. McKenzie Daniel,
DVM, DABVP
(Canine and Feline)

IMAGING PERFORMED BY

Rebekah Jakum, CVT
ARDMS/RVT

HOSPITAL NAME

Annville-Cleona VA

REFERRING VET

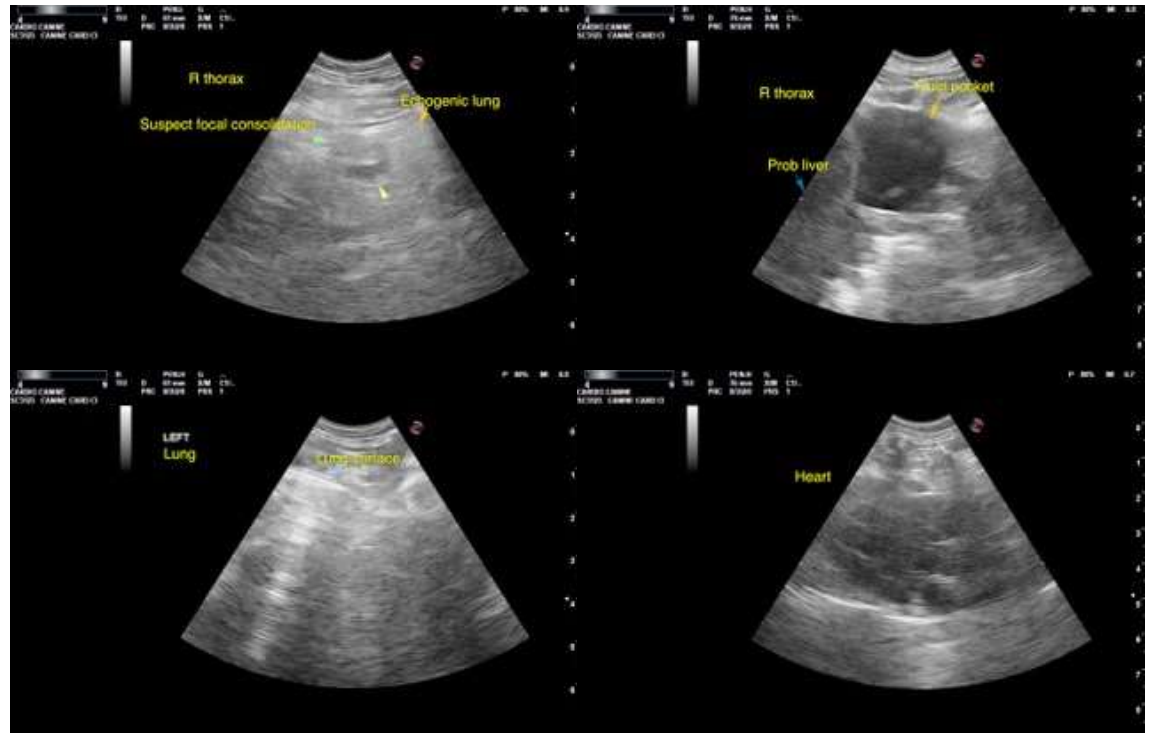
Dr. Bardsley

INVOICE

48306

DATE

11.12.2021



The information and recommendations provided are based on the images presented by the referring veterinarian. No evaluation can be communicated regarding pathology that was not visible in the image/video clips provided.

Thank you for this referral. If the clinical or image interpretation does not parallel your findings or if I can be of any further assistance please contact me.

R. McKenzie Daniel, DVM, DABVP (Canine/Feline Practice)
mac.daniel@sonopath.com