



## PATIENT

Cora Alexander

## SPECIES

Canine

## BREED

Labrador Retriever

## SEX

Spayed Female

## AGE

9 Years 4 Months

## WEIGHT

47.2 pounds

## INTERPRETED BY

R. McKenzie Daniel,  
DVM, DABVP

## IMAGING PERFORMED BY

Dr. Gabriel Ferrer  
DVM

## HOSPITAL NAME

Pulse Pet Ultrasound  
Services

## REFERRING VET

Dra. Laura S. Solis

## INVOICE

12201

## DATE

11/11/25

## PRESENTING CLINICAL SIGNS

Pt presented as a referral for an abdominal ultrasound for vomiting. PT has a history of vomiting for 1 week and has not improve with medications. PT was hospitalized with IV fluids on Emergency clinic, but still vomiting and depressed.

Abnormal PE/Chem/CBC/UA Results: Radiograph and BW attached as supporting documents.

## ULTRASONOGRAPHIC EXAMINATION OF THE ABDOMEN

### Urinary System

The urinary bladder, trigone, cystourethral junction, and visible pelvic urethra exhibited normal thickness and tone. Anechoic urine was present in the lumen with no uroliths or sediment. The ureteral papillae were normal. The ureters were not visible which is normal. No evidence of inflammatory or neoplastic change were noted.

Normal size and margination was present in the kidneys. A normal 1:3 cortex / medulla ratio and normal corticomedullary definition were maintained. The echogenicity of the cortex was similar to or slightly less than normal liver parenchyma while the medulla echogenicity was hypoechoic to the cortex with no evidence of pelvic dilation. The left kidney measured 5.5 cm in length. The right kidney measured 6.0 cm in length.

### Adrenal Glands

The left adrenal gland was uniform in size and contour with a uniformly hypoechoic parenchyma. The left adrenal gland measured 0.59 cm width at the caudal pole. The right adrenal gland was uniform in size and contour with a uniformly hypoechoic parenchyma. The right adrenal gland measured 0.72 cm width at the caudal pole.

### Spleen

The spleen exhibited a finely textured and homogenous parenchyma which was hyperechoic to the liver and renal cortical parenchyma. The capsule was smooth and regular without apparent expansion. The splenic vasculature at the hilus was normal in volume with no evidence of congestion or thrombosis. Acute to chronic inflammatory, neoplastic, or benign parenchyma changes were not noted.

### Liver

The liver was subjectively normal in size, structure, and contour. The liver parenchyma was uniform and hypoechoic to the spleen with a mild coarse echotexture. The hepatic and portal vasculature were normal in appearance without signs of congestion. The gallbladder was non-distended in size with thin walls and primarily anechoic luminal content. The cystic and common bile ducts were normal.

### Gastrointestinal

The stomach was significantly distended with retained anechoic fluid extending into the pyloric outflow. No obvious evidence of obstruction to pyloric outflow or shadowing gastric content.

The small intestine presented with overall intact wall layering and maintained wall layer ratio. A strongly shadowing jejunal lumen echo was present measuring approximately 2.0 cm in diameter in the



## PATIENT

Cora Alexander

## SPECIES

Canine

## BREED

Labrador Retriever

## SEX

Spayed Female

## AGE

9 Years 4 Months

## WEIGHT

47.2 pounds

## INTERPRETED BY

R. McKenzie Daniel,  
DVM, DABVP

## IMAGING PERFORMED BY

Dr. Gabriel Ferrer  
DVM

## HOSPITAL NAME

Pulse Pet Ultrasound  
Services

## REFERRING VET

Dra. Laura S. Solis

## INVOICE

12201

## DATE

11/11/25

subjective mid abdomen jejunal segments. Fluid dilated obstructive small intestinal pattern proximal with empty small intestine distal to the approximate level of the colon.

Normal visible colon wall layers were present with apparent formed feces in lumen.

### *Pancreas*

The parenchyma of the left limb, body and right limb of the pancreas presented isoechoic to the adjacent omental fat. A normal curvilinear capsule contour of the pancreas was present. The visible pancreatic duct was normal. No signs of active inflammation or neoplastic disease was evident.

### *Free Abdomen*

No visualized significant omental lymphadenopathy or peritoneal effusion was present. Generalized normal omental echogenicity with mild peri jejunal hyperechoic omentum in the area of the foreign body.

## ULTRASONOGRAPHIC FINDINGS

- Jejunal foreign body with proximal gastrointestinal obstructive pattern, empty small intestine distal.
- Mild associated peri-intestinal reactive omentum- no evidence of peritonitis.

## INTERPRETATION OF THE FINDINGS & FURTHER RECOMMENDATIONS

Exploratory laparotomy with gross inspection of the gastrointestinal tract and expectation toward enterotomy is recommended. Subjective mild associated inflammatory jejunal changes in the area of the foreign body yet overall, no overt sonographic evidence of concurrent gastrointestinal mural pathology or additional obstructive criteria.



## PATIENT

Cora Alexander

## SPECIES

Canine

## BREED

Labrador Retriever

## SEX

Spayed Female

## AGE

9 Years 4 Months

## WEIGHT

47.2 pounds

## INTERPRETED BY

R. McKenzie Daniel,  
DVM, DABVP

## IMAGING PERFORMED BY

Dr. Gabriel Ferrer  
DVM

## HOSPITAL NAME

Pulse Pet Ultrasound  
Services

## REFERRING VET

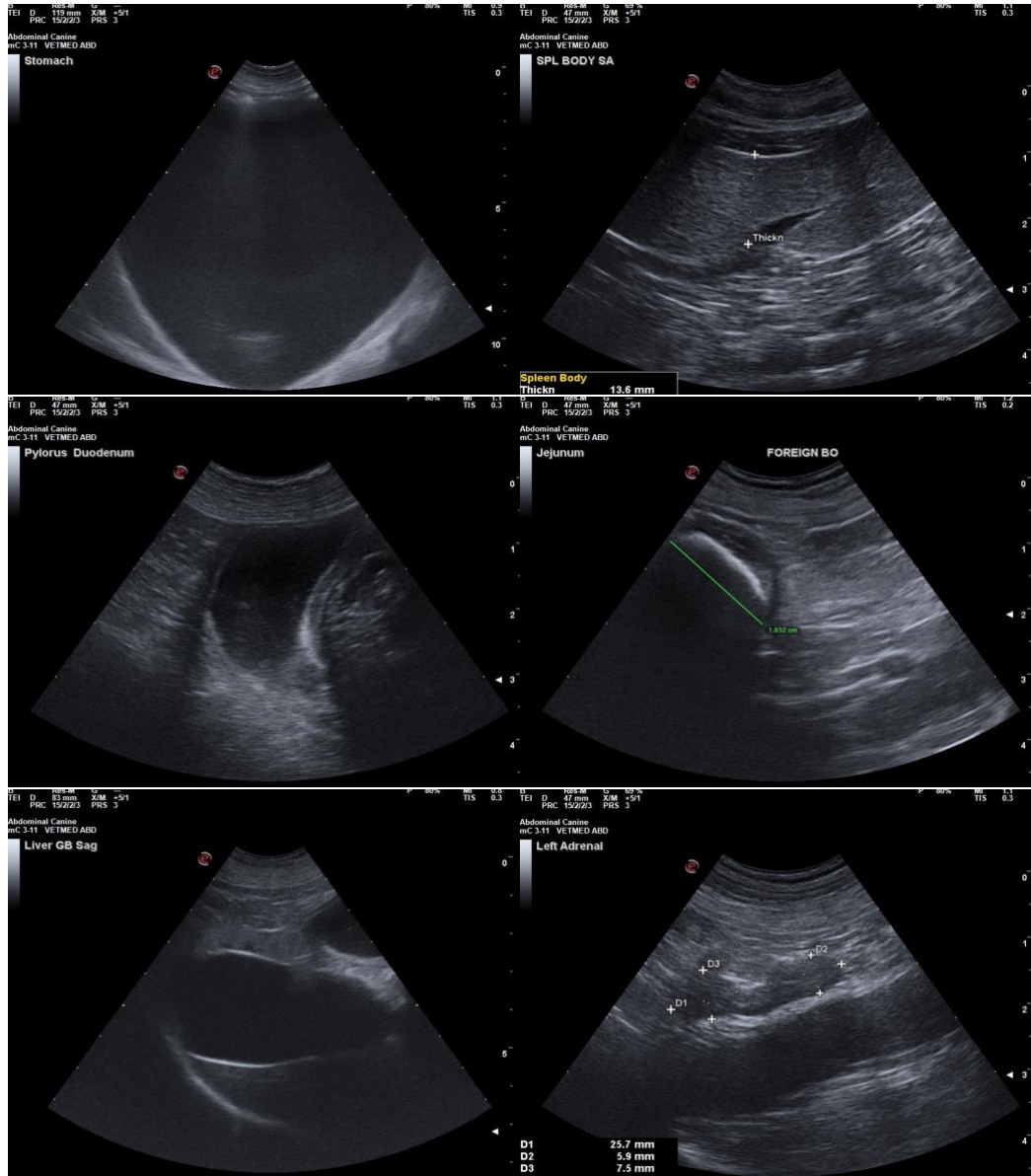
Dra. Laura S. Solis

## INVOICE

12201

## DATE

11/11/25





## PATIENT

Cora Alexander

## SPECIES

Canine

## BREED

Labrador Retriever

## SEX

Spayed Female

## AGE

9 Years 4 Months

## WEIGHT

47.2 pounds

## INTERPRETED BY

R. McKenzie Daniel,  
DVM, DABVP

## IMAGING PERFORMED BY

Dr. Gabriel Ferrer  
DVM

## HOSPITAL NAME

Pulse Pet Ultrasound  
Services

## REFERRING VET

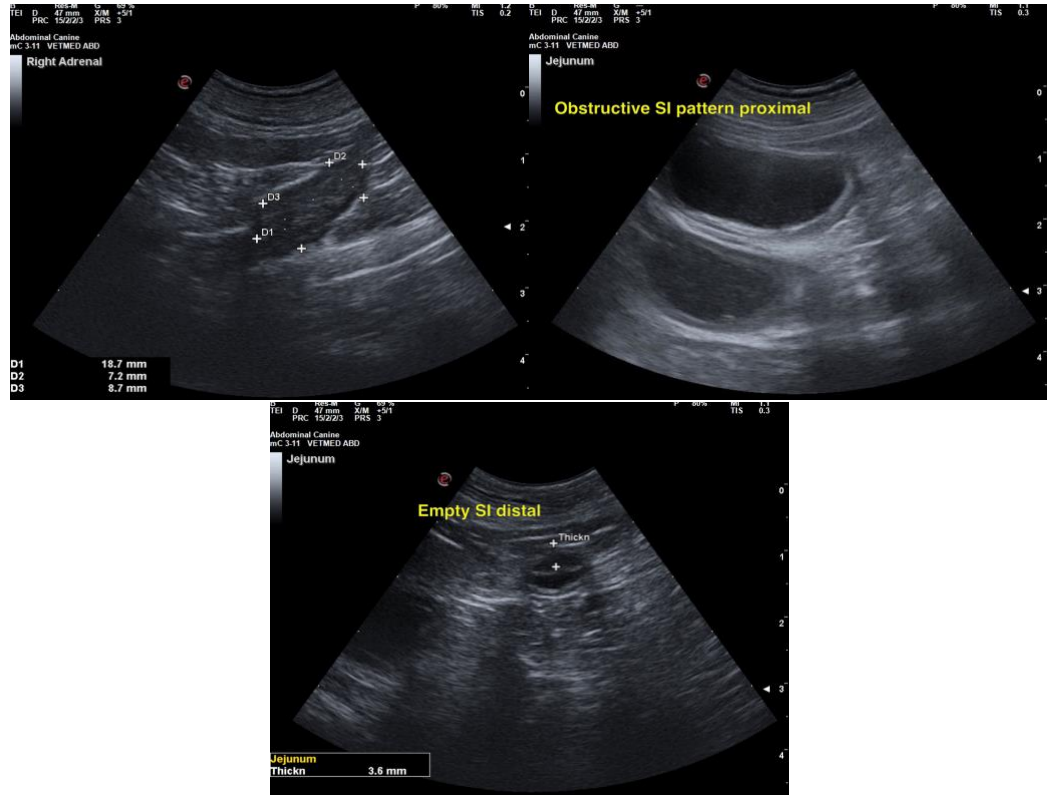
Dra. Laura S. Solis

## INVOICE

12201

## DATE

11/11/25



The information and recommendations provided are based on the images presented by the referring veterinarian/sonographer. No evaluation can be communicated regarding pathology that was not visible in the image/video clips provided.

Thank you for this referral. If the clinical or image interpretation does not parallel your findings or if I can be of any further assistance, please contact me.

R. McKenzie Daniel, DVM, DABVP (Canine / Feline Practice)

[info@SonoPath.com](mailto:info@SonoPath.com)