



PATIENT

Coal Kelleman

SPECIES

Canine

BREED

Yorkie/Chihuahua

SEX

MN

AGE

9 y, 10 mos

WEIGHT

12.8 lbs.

INTERPRETED BY

R. McKenzie Daniel,
DVM, DABVP
(Canine and Feline)

IMAGING PERFORMED BY

Shari Reffi, CVT

HOSPITAL NAME

Smithfield AH

REFERRING VET

Dr. Boe

INVOICE

10321

DATE

11/11/25

PRESENTING CLINICAL SIGNS

Grade IV/VI heart murmur, dry coughing. Prev. liver elevations. Administered Torb/Midaz for scan.

ULTRASONOGRAPHIC EXAMINATION OF THE HEART & ABDOMEN

CANINE CARDIAC PARAMETERS	MR VMAX (m/s)	TR VMAX (m/s)	LA/AO (M-Mode)	LA/AO (Heart Base; Swe)	FS (%)	EF (%)	EPSS (cm)
NORMAL PARAMETER	4.5-5.5	<2.7	1.3	Up to 1.6	28-40	40-100	<0.6
PATIENT	5.2			1.55	38	71	0.2
CANINE CARDIAC PARAMETERS	HR (BPM)	AV VMAX (m/s)	PV MAX (m/s)	BODY WEIGHT (kg)	LAD LA MAX 4 Chamber	LVIDd Avg; 2D and m-mode short axis (cm)	LVIDs Avg; 2D and m-mode short axis (cm)
NORMAL PARAMETER	50-100	0.7-1.7	0.7-1.6				
PATIENT	196	1.5	1.0		2.7	2.5	

Cardiac Presentation

The left atrium exhibited borderline increased dimension on 2 LA measurement methods. No evidence of interatrial septal deviation. The cranial and caudal **mitral** valve leaflets presented thickening consistent with endocardiosis. Doppler revealed moderate eccentric insufficiency (MR velocity 5.2 m/s). The **left ventricle** presented normal thicknesses with normal to borderline increased LV dimension. The **myocardium** presented normal echogenicity without subjective evidence of significant fibrotic or ischemic disease. **Contractility** of the ventricular walls was adequate and in normal range for this patient evidenced by the fractional shortening measurement and subjective evaluation of the different regions of the myocardium. The **left ventricular outflow** tract demonstrated normal laminar flow and subjective structural integrity. The **right atrium** and auricle revealed normal size, structure and content. No evidence of masses was noted or chamber overload. **Tricuspid** valvular assessment demonstrated adequate linear morphology. The **right ventricle** was of normal size (1/3 diameter of LV), chordae structure, myocardial echogenicity and thickness. **Pulmonic** tract assessment revealed normal valve structure, laminar flow, and diameter (approx. 1:1 pa/ao ratio). No visible **pericardial** or free pleura fluid was noted. No echographically detectable evidence of cardiac / pericardial tumors was visible.



PATIENT

Coal Kelleman

SPECIES

Canine

BREED

Yorkie/Chihuahua

SEX

MN

AGE

9 y, 10 mos

WEIGHT

12.8 lbs.

INTERPRETED BY

R. McKenzie Daniel,
 DVM, DABVP
 (Canine and Feline)

IMAGING PERFORMED BY

Shari Reffi, CVT

HOSPITAL NAME

Smithfield AH

REFERRING VET

Dr. Boe

INVOICE

10321

DATE

11/11/25

Urinary System

The urinary bladder, trigone, cystourethral junction, and visible pelvic urethra to a depth of 2.0 cm exhibited normal thickness and tone. Primarily anechoic urine was present in the lumen. Mild, nondependent, particulate sediment was present without evidence of calculus formation. The ureteral papillae were normal. The ureters were not visible which is normal. No evidence of inflammatory or neoplastic mural changes were noted.

The area of the residual prostate appeared normal and free of pathology.

No evidence of pathology in the area of the aortic trifurcation.

Normal size and margination were present in the kidneys. A normal 1:3 cortex / medulla ratio was maintained. The medulla and cortices were uniform in texture with some increased echogenicity and mild loss of corticomedullary symmetry and definition expected for the age of the patient. No evidence of pelvic dilation was present. Small cortical left kidney cyst was noted. The left kidney measured 3.9 cm in length. The right kidney measured 4.1 cm in length.

Adrenal Glands

The left adrenal gland was uniform in size and contour with a uniformly hypoechoic parenchyma. The left adrenal gland measured 0.56 cm width at the caudal pole. The right adrenal gland was uniform in size and contour with a uniformly hypoechoic parenchyma. The right adrenal gland measured 0.53 cm width at the caudal pole.

Spleen

The spleen exhibited a finely textured and homogenous parenchyma which was hyperechoic to the liver and renal cortical parenchyma. The capsule was smooth and regular without apparent expansion. The splenic vasculature at the hilus was normal in volume with no evidence of congestion or thrombosis. Acute to chronic inflammatory, neoplastic, or benign parenchyma changes were not noted.

Liver/ Gallbladder

The liver presented borderline to mildly enlarged in size. The parenchyma of the liver was subjectively normal in echogenicity compared to the spleen and renal cortices. The liver parenchyma was uniform with a mildly coarse echotexture. The capsule of the liver was symmetrically rounded to mildly swollen in margination. The hepatic and portal vasculature were normal in appearance without signs of congestion. The gallbladder was non-distended in size containing primarily anechoic content with mild, nonorganized gallbladder debris.

Gastrointestinal

The stomach presented intact wall layering with a normal wall layer ratio. The lumen of the stomach was empty without evidence of retained ingesta, fluid, or foreign material.

The small intestine presented intact wall layering with 1:3 muscularis/mucosa ratio. The lumen of the small intestine was empty with no signs of ileus, obstruction, or foreign material.



PATIENT

Normal visible colon wall layers were present with apparent formed feces in lumen.

Coal Kelleman

Pancreas

SPECIES

The parenchyma of the left limb, body, and right limb of the pancreas presented isoechoic to the adjacent omental fat. A normal curvilinear capsule contour of the pancreas was present. The visible pancreatic duct was normal. No signs of active inflammation or neoplastic disease were evident.

Canine

BREED

Free Abdomen

Yorkie/Chihuahua

No overt lymphadenopathy or peritoneal effusion was present.

SEX

MN

AGE

9 y, 10 mos

WEIGHT

12.8 lbs.

ULTRASONOGRAPHIC FINDINGS

- Chronic mitral valve disease (emerging ACVIM B2)
- Benign hepatopathy
- Mild nonorganized gallbladder debris (non-mucocele)
- Age-related renal changes
- Normal bilateral adrenal glands
- Mild urine sediment

INTERPRETED BY

R. McKenzie Daniel,
 DVM, DABVP
 (Canine and Feline)

INTERPRETATION OF THE FINDINGS & FURTHER RECOMMENDATIONS

IMAGING

PERFORMED BY

The borderline increased LA / LV dimension indicates that the current and future risk of complications secondary to MR is mildly elevated yet overall the left heart appears to be stable. There are no additional clinical issues such as pulmonary hypertension, indicating that the coughing in this patient is likely noncardiogenic in origin. Respiratory support is indicated.

Shari Reffi, CVT

HOSPITAL NAME

Smithfield AH

With only borderline increased left chamber size, there is no obvious indication for cardiac medications, yet prognosis is variable and sonographic, as well as clinical, monitoring is advised. Recheck echocardiogram is suggested in 6 months, sooner if clinical signs, i.e., elevated resting respiration rate, are noted. Anesthetic risk is considered low.

REFERRING VET

Dr. Boe

Correlation with pending lab work and urinalysis is recommended. Hepatosupportive medications may prove beneficial.

INVOICE

10321

Suggested anesthetic protocol may include opioid or Benzodiazepine pre-med, induction with Propofol or Alfaxalone, and appropriate gas anesthesia with avoidance of alpha 2 agonists.

DATE

11/11/25



PATIENT

Coal Kelleman

SPECIES

Canine

BREED

Yorkie/Chihuahua

SEX

MN

AGE

9 y, 10 mos

WEIGHT

12.8 lbs.

INTERPRETED BY

R. McKenzie Daniel,
 DVM, DABVP
 (Canine and Feline)

IMAGING PERFORMED BY

Shari Reffi, CVT

HOSPITAL NAME

Smithfield AH

REFERRING VET

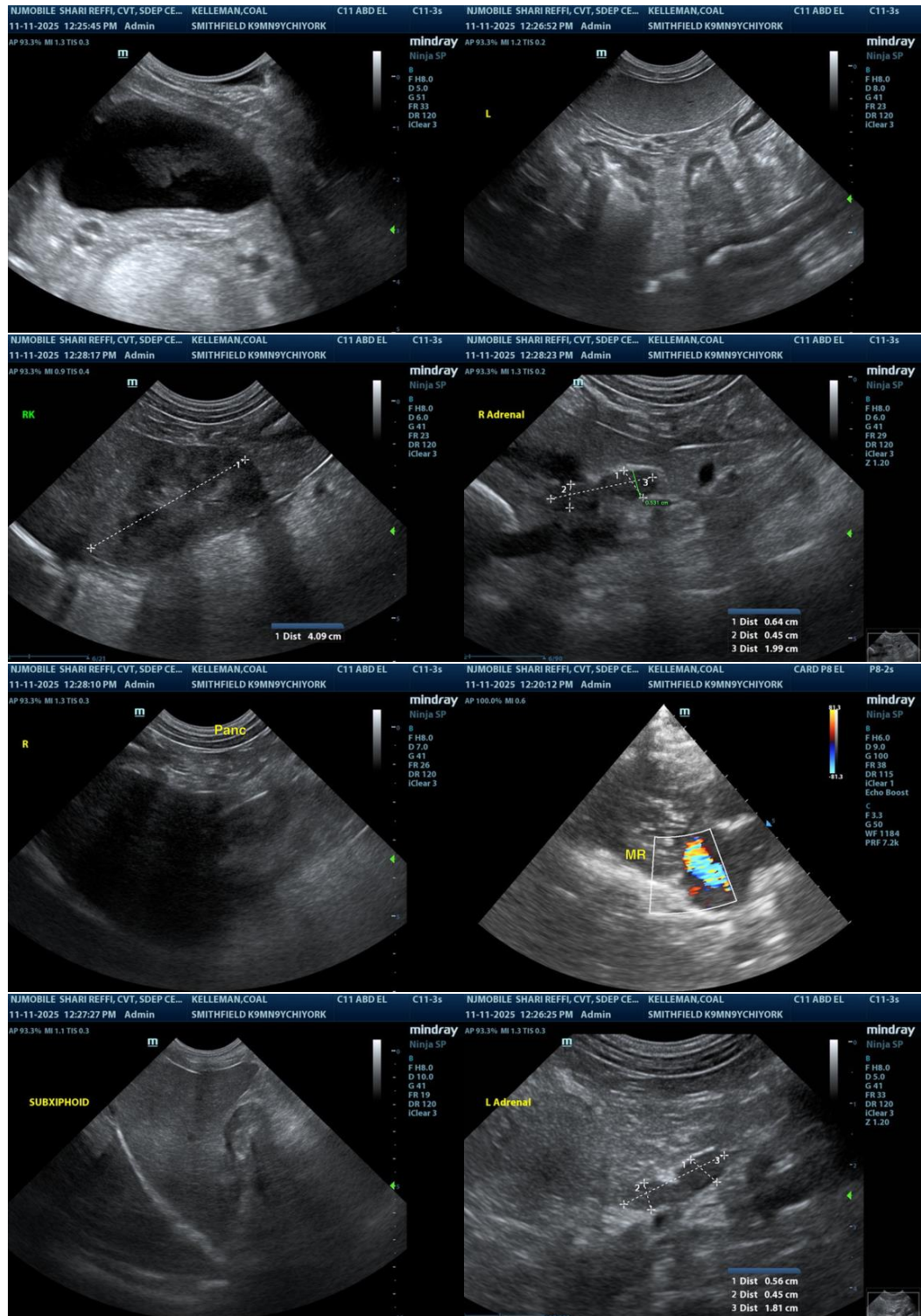
Dr. Boe

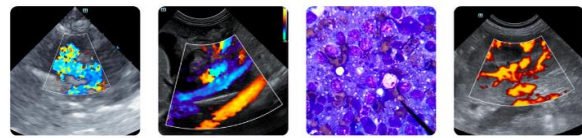
INVOICE

10321

DATE

11/11/25





PATIENT

Coal Kelleman

SPECIES

Canine

BREED

Yorkie/Chihuahua

SEX

MN

AGE

9 y, 10 mos

WEIGHT

12.8 lbs.

INTERPRETED BY

R. McKenzie Daniel,
 DVM, DABVP
 (Canine and Feline)

IMAGING PERFORMED BY

Shari Reffi, CVT

HOSPITAL NAME

Smithfield AH

REFERRING VET

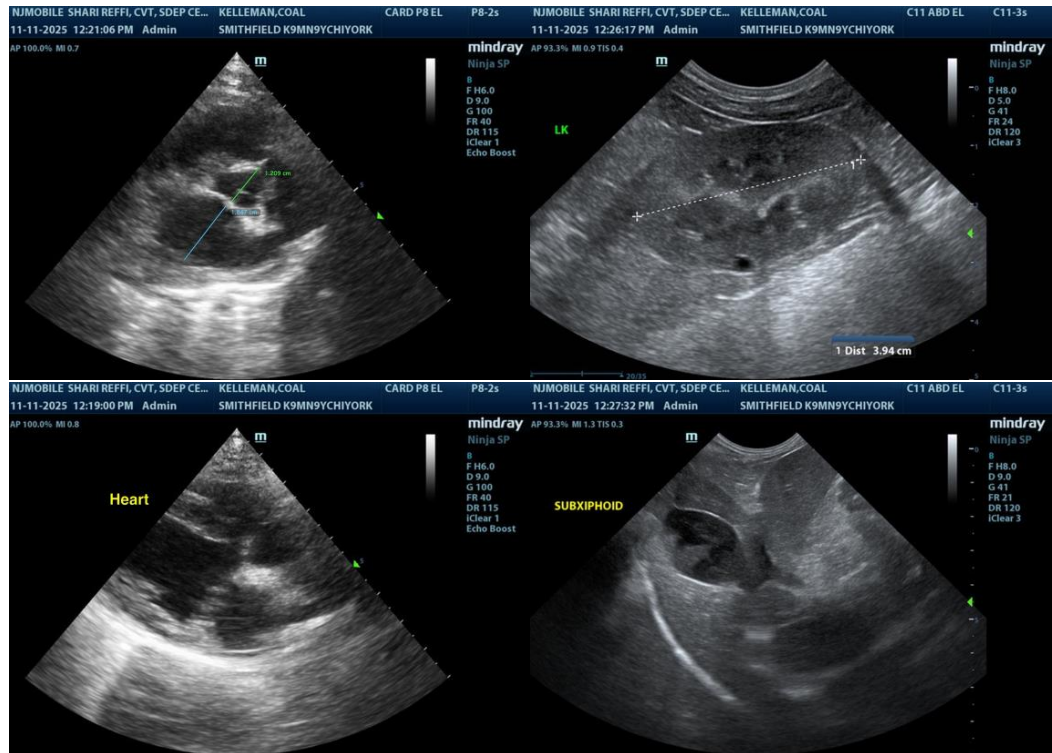
Dr. Boe

INVOICE

10321

DATE

11/11/25



The information and recommendations provided are based on the images presented by the referring veterinarian/sonographer. No evaluation can be communicated regarding pathology that was not visible in the image/video clips provided.

Thank you for this referral. If the clinical or image interpretation does not parallel your findings or if I can be of any further assistance, please contact me.

R. McKenzie Daniel, DVM, DABVP (Canine/Feline Practice)
info@sonopath.com