



PATIENT

Harley Boles

SPECIES

Canine

BREED

German Shorthair
Pointer

SEX

Spayed Female

AGE

1

WEIGHT

52

INTERPRETED BY

R. McKenzie Daniel,
DVM, DABVP

IMAGING PERFORMED BY

Jenn

HOSPITAL NAME

Rockaway Animal
Hospital

REFERRING VET

Dr. Harrs

INVOICE

12166

DATE

11/10/25

PRESENTING CLINICAL SIGNS

possible ate rubber stopper from chair not visible on rads and not produced when vomiting induced

ULTRASONOGRAPHIC EXAMINATION OF THE ABDOMEN

Urinary System

The urinary bladder, trigone, cystourethral junction, and visible pelvic urethra exhibited normal thickness and tone. Anechoic urine was present in the lumen with no uroliths or sediment. The ureteral papillae were normal. The ureters were not visible which is normal. No evidence of inflammatory or neoplastic change were noted.

Normal size and margination was present in the kidneys. A normal 1:3 cortex / medulla ratio and normal corticomedullary definition were maintained. The echogenicity of the cortex was similar to or slightly less than normal liver parenchyma while the medulla echogenicity was hypoechoic to the cortex with no evidence of pelvic dilation.

Adrenal Glands

The left adrenal gland was uniform in size and contour with a uniformly hypoechoic parenchyma. The left adrenal gland measured 0.47 cm width at the caudal pole. The right adrenal gland was uniform in size and contour with a uniformly hypoechoic parenchyma. The right adrenal gland measured 0.49 cm width at the caudal pole.

Spleen

The spleen exhibited a finely textured and homogenous parenchyma which was hyperechoic to the liver and renal cortical parenchyma. The capsule was smooth and regular without apparent expansion. The splenic vasculature at the hilus was normal in volume with no evidence of congestion or thrombosis. Acute to chronic inflammatory, neoplastic, or benign parenchyma changes were not noted.

Liver

The liver was subjectively normal in size, structure, and contour. The liver parenchyma was uniform and hypoechoic to the spleen with a mild coarse echotexture. The hepatic and portal vasculature were normal in appearance without signs of congestion. The gallbladder was non-distended in size with thin walls and primarily anechoic luminal content. The cystic and common bile ducts were normal.

Gastrointestinal

The stomach presented intact wall layering with a normal wall layer ratio. The lumen of the stomach was empty with mild lumen gas and subjective minor nonshadowing ingesta. No evidence of shadowing or obstructive gastric contents.

The small intestine presented intact wall layering with 1:3 muscularis/mucosa ratio. The lumen of the small intestine was empty with mild segmental gas. No evidence of shadowing content or obstructive pattern.

Normal visible colon wall layers were present with apparent formed feces in lumen.

Pancreas



PATIENT

Harley Boles

The parenchyma of the left limb, body and right limb of the pancreas presented isoechoic to the adjacent omental fat. A normal curvilinear capsule contour of the pancreas was present. The visible pancreatic duct was normal. No signs of active inflammation or neoplastic disease was evident.

SPECIES

Canine

Free Abdomen

No overt lymphadenopathy or peritoneal effusion was present.

BREED

German Shorthair
Pointer

ULTRASONOGRAPHIC FINDINGS

- Sonographically unremarkable empty gastrointestinal tract.

SEX

Spayed Female

INTERPRETATION OF THE FINDINGS & FURTHER RECOMMENDATIONS

No evidence of definitive gastrointestinal obstructive pattern or nonobstructive foreign body. Gastrointestinal support with clinical monitoring and sonographic reassessment if gastrointestinal signs arise, is recommended.

AGE

1

WEIGHT

52

INTERPRETED BY

R. McKenzie Daniel,
DVM, DABVP

IMAGING PERFORMED BY

Jenn

HOSPITAL NAME

Rockaway Animal
Hospital

REFERRING VET

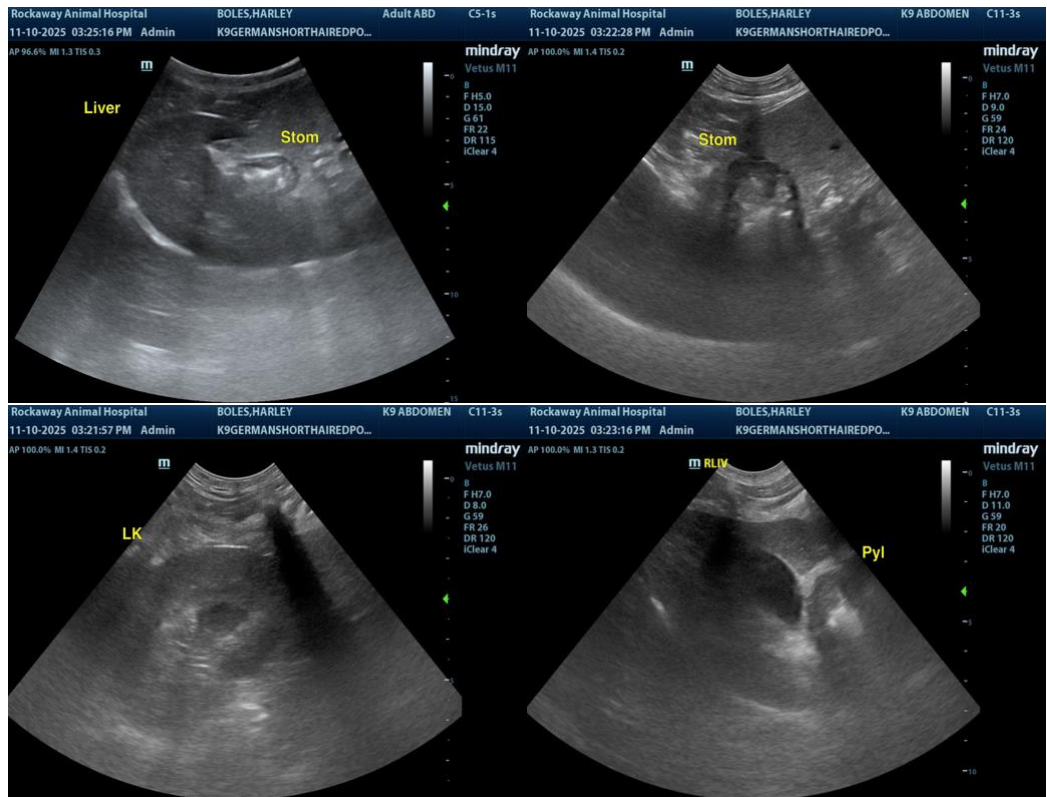
Dr. Harrs

INVOICE

12166

DATE

11/10/25





PATIENT

Harley Boles

SPECIES

Canine

BREED

German Shorthair
Pointer

SEX

Spayed Female

AGE

1

WEIGHT

52

INTERPRETED BY

R. McKenzie Daniel,
DVM, DABVP

IMAGING PERFORMED BY

Jenn

HOSPITAL NAME

Rockaway Animal
Hospital

REFERRING VET

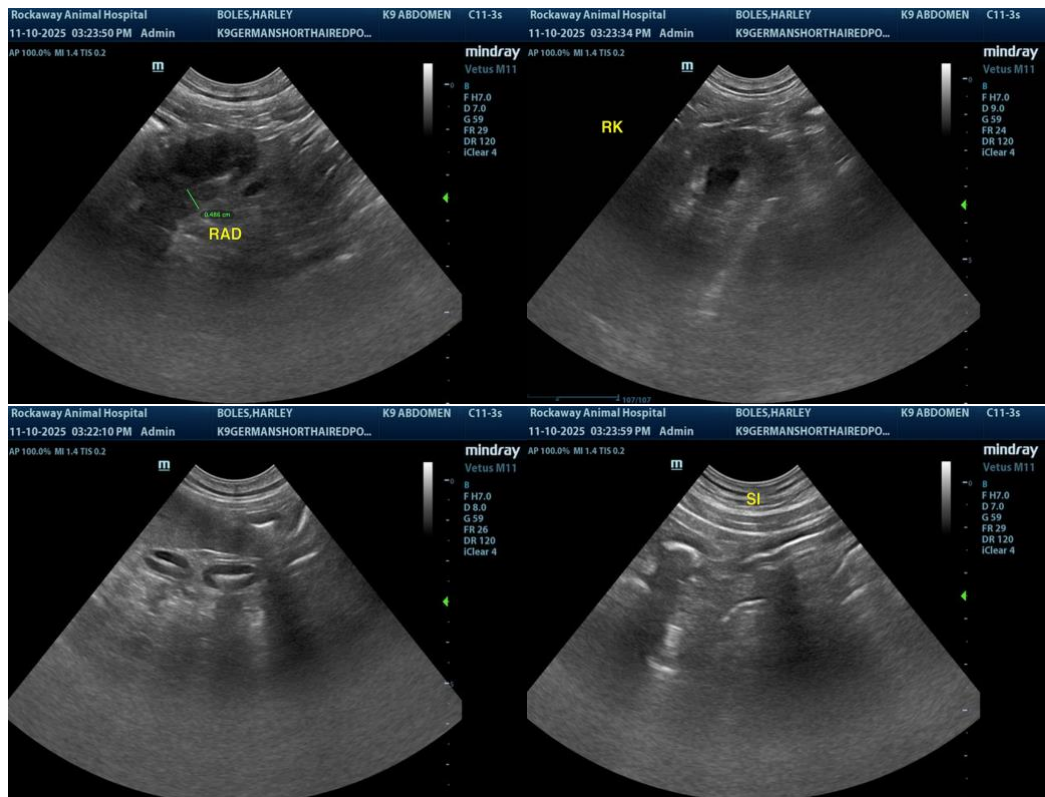
Dr. Harrs

INVOICE

12166

DATE

11/10/25



The information and recommendations provided are based on the images presented by the referring veterinarian/sonographer. No evaluation can be communicated regarding pathology that was not visible in the image/video clips provided.

Thank you for this referral. If the clinical or image interpretation does not parallel your findings or if I can be of any further assistance, please contact me.

R. McKenzie Daniel, DVM, DABVP (Canine / Feline Practice)

info@SonoPath.com