SonoPath
Clinical Sonography & Telecytology

EDUCATIONAL TELECONSULTATION SERVICES™

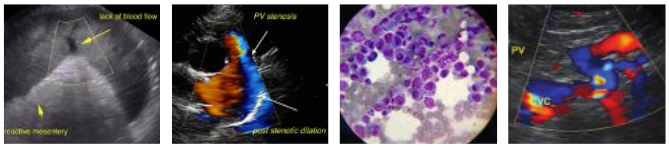

SonoPath.com™
1-800-838-4268 info@sonopath.com

PATIENT
Willow Birkett

SPECIES
Canine

BREED
Havanese Mix

SEX
Spayed Female

AGE
4 Years

WEIGHT
8 kg

INTERPRETED BY
R. McKenzie Daniel, DVM, DABVP (Canine and Feline)

IMAGING PERFORMED BY
Dave Stasiuk RDMS, RDCS

HOSPITAL NAME
Resolution VU, LTD

REFERRING VET
Alpine 24/7

INVOICE
17933

DATE
11/10/22

PRESENTING CLINICAL SIGNS

History: Anorexia. Lethargy. Elevated ALT, Amylase, Lipase. Spec cPL pending. Very tender right abdomen.

ULTRASONOGRAPHIC EXAMINATION OF THE ABDOMEN

Urinary System

The urinary bladder, trigone, cystourethral junction, and visible pelvic urethra to a depth of – cm exhibited normal thickness and tone. Anechoic urine was present in the lumen with no uroliths or sediment. The ureteral papillae were normal. The ureters were not visible which is normal. No evidence of inflammatory or neoplastic changes were noted.

The kidneys were normal in size and margination with adequate corticomedullary border demarcation with 1:3 cortex to medulla ratio. Two moderately sized thinly walled cysts were present in the left kidney, containing anechoic fluid. An example of left kidney cyst measured 2.2 cm in diameter. Concurrent small cortical cyst was present in the right kidney. The left kidney measured 5.0 cm in length. The right kidney measured 5.2 cm in length.

Adrenal Glands

The left adrenal gland was uniform in size and contour with a uniformly hypoechoic parenchyma. The left adrenal gland measured 0.40 cm width at the caudal pole and 0.43 cm width at the cranial pole.

The right adrenal gland was uniform in size and contour with a uniformly hypoechoic parenchyma. The right adrenal gland measured 0.37 cm width at the caudal pole.

Spleen

The spleen exhibited a finely textured and homogenous parenchyma which was hyperechoic to the liver and renal cortical parenchyma. The capsule was smooth and regular without apparent expansion. The splenic vasculature at the hilus was normal in volume with no evidence of congestion or thrombosis. Acute to chronic inflammatory, neoplastic, or benign parenchyma changes were not noted.

Liver

The liver presented enlarged in size. The parenchyma of the liver was subjectively normal in echogenicity compared to the spleen and renal cortices. The liver parenchyma was uniform with a mildly coarse echotexture. The capsule of the liver was symmetrically rounded to mildly swollen in margination. The hepatic and portal vasculature were normal in appearance without signs of congestion.

The gallbladder was non-distended in size, containing primarily anechoic content with mild nondependent mildly echogenic nonorganized luminal debris. The common bile ducts was not definitely visualized yet without evidence of posthepatic obstructive criteria.

Gastrointestinal

The stomach presented intact yet mildly prominent wall layering. The lumen of the stomach contained a mild amount of retained nonshadowing ingesta/chyme.

The duodenum presented intact yet mildly prominent wall layering. No evidence of duodenal corrugation or ileus. The jejunum and ileum to the level of the colon were sonographically normal.

Normal visible colon wall layers were present with apparent formed feces in lumen.

SonoPath
Clinical Sonography & Telecytology
EDUCATIONAL TELECONSULTATION SERVICES™

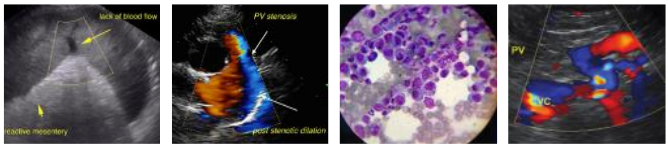

SonoPath.com™
1-800-838-4268 info@sonopath.com

PATIENT

Willow Birkett

SPECIES

Canine

BREED

Havanese Mix

SEX

Spayed Female

AGE

4 Years

WEIGHT

8 kg

INTERPRETED BY

R. McKenzie Daniel, DVM, DABVP (Canine and Feline)

IMAGING PERFORMED BY

Dave Stasiuk RDMS, RDCS

HOSPITAL NAME

Resolution VU, LTD

REFERRING VET

Alpine 24/7

INVOICE

17933

DATE

11/10/22

Pancreas

Diffuse enlargement of the pancreas base and right pancreatic limb with ill-defined, hypoechoic to heterogeneous parenchyma and asymmetrical contour was present. Regional peripancreatic nonuniform hyperechoic mesentery was noted around the pancreas base and right pancreatic limb.

Free Abdomen

Mild volume primarily anechoic peripancreatic and perihepatic free fluid were present, primarily in the right cranial abdomen. No overt lymphadenopathy.

ULTRASONOGRAPHIC FINDINGS

Primary Findings

- Acute pancreatitis with regional peritonitis
- Benign hepatopathy- reactive or possible concurrent primary versus secondary inflammatory hepatopathy is possible
- Nondistended gallbladder with mild luminal debris (non-mucocele)
- Mild gastroduodenitis pattern with mild gastric hypomotility
- Mild volume peripancreatic/perihepatic free fluid

Secondary Findings

- Bilateral renal cysts, more prominent in the left kidney

INTERPRETATION OF THE FINDINGS & FURTHER RECOMMENDATIONS

Hospitalization with aggressive therapy for active pancreatitis, including hepatogastrointestinal support is recommended. Minor potential for pancreatic neoplastic criteria, which may present in similar sonographic manner as active inflammation is considered an unlikely differential diagnosis. Recheck sonogram may be considered in 3-5 days pending clinical response to therapy for further assessment of the pancreas or sooner if progressive clinical signs or evidence of increasing hepatic enzyme elevations/cholestasis are noted.

SonoPath

Clinical Sonography & Telecytology

EDUCATIONAL TELECONSULTATION SERVICES™

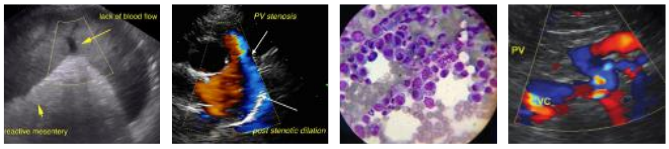

SonoPath.com™

1-800-838-4268 info@sonopath.com

PATIENT

Willow Birkett

SPECIES

Canine

BREED

Havanese Mix

SEX

Spayed Female

AGE

4 Years

WEIGHT

8 kg

INTERPRETED BY

R. McKenzie Daniel, DVM, DABVP (Canine and Feline)

IMAGING PERFORMED BY

Dave Stasiuk RDMS, RDCS

HOSPITAL NAME

Resolution VU, LTD

REFERRING VET

Alpine 24/7

INVOICE

17933

DATE

11/10/22

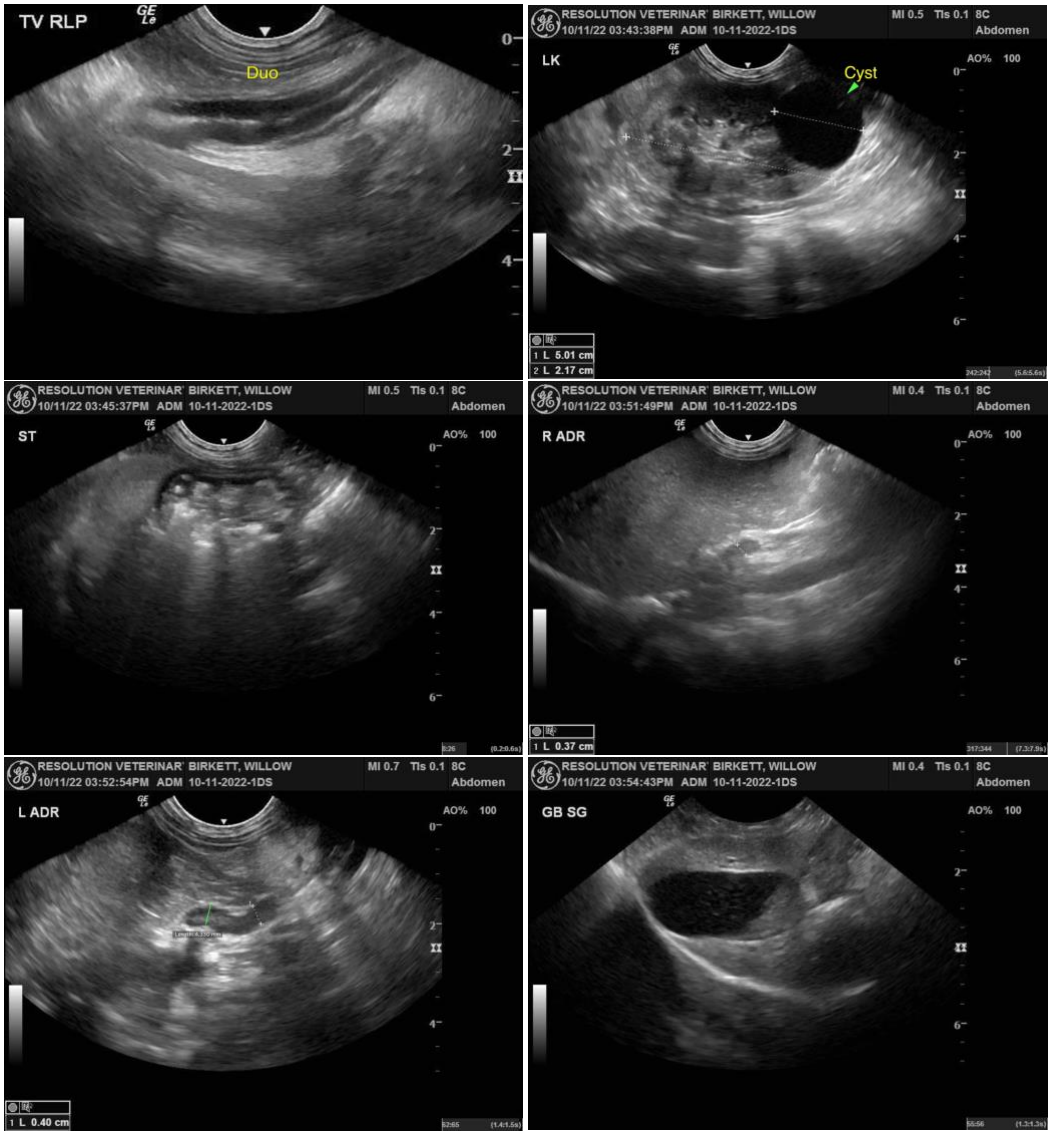

SonoPath

Clinical Sonography & Telecytology

EDUCATIONAL TELECONSULTATION SERVICES™

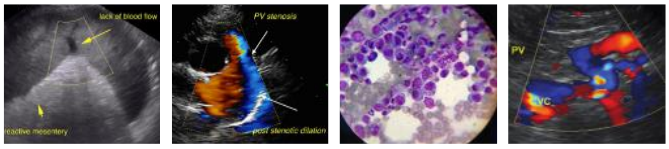

SonoPath.com™
1-800-838-4268 info@sonopath.com

PATIENT

Willow Birkett

SPECIES

Canine

BREED

Havanese Mix

SEX

Spayed Female

AGE

4 Years

WEIGHT

8 kg

INTERPRETED BY

R. McKenzie Daniel, DVM, DABVP (Canine and Feline)

IMAGING PERFORMED BY

Dave Stasiuk RDMS, RDCS

HOSPITAL NAME

Resolution VU, LTD

REFERRING VET

Alpine 24/7

INVOICE

17933

DATE

11/10/22

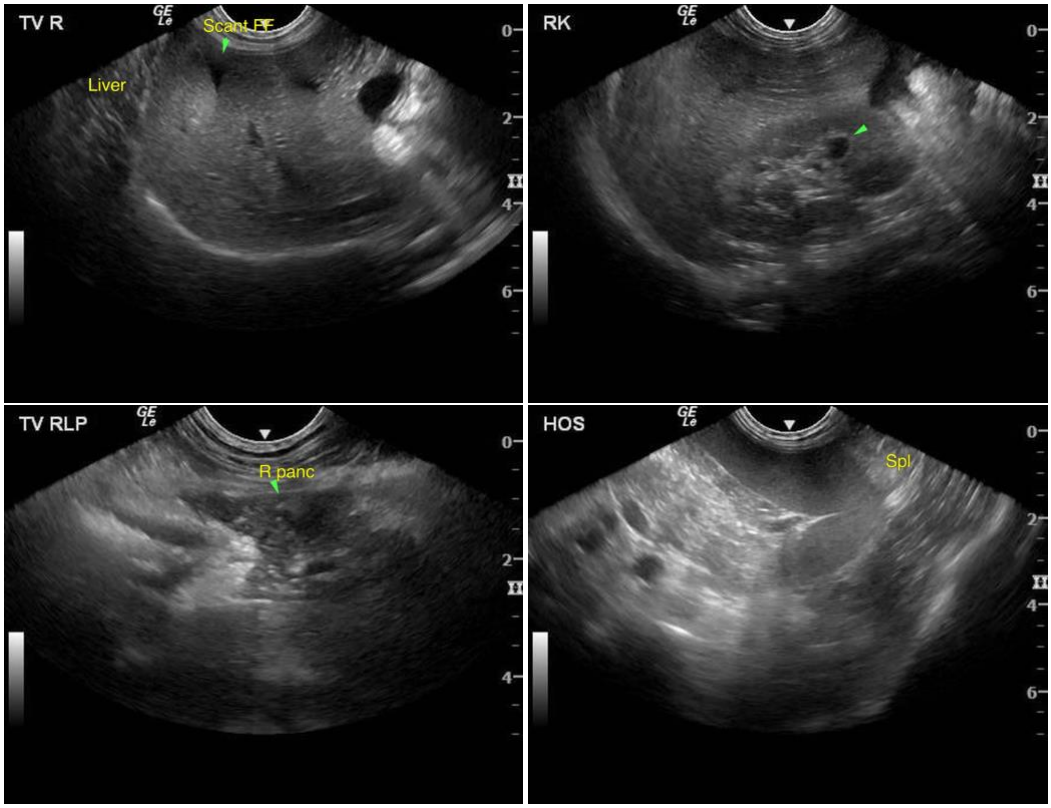

The information and recommendations provided are based on the images presented by the referring veterinarian. No evaluation can be communicated regarding pathology that was not visible in the image/video clips provided.

Thank you for this referral. If the clinical or image interpretation does not parallel your findings or if I can be of any further assistance please contact me.

R. McKenzie Daniel, DVM, DABVP (Canine / Feline Practice)
info@SonoPath.com