



PATIENT PRESENTING CLINICAL SIGNS

Remy Frantz Hematuria, urinary crystals.

SPECIES Unremarkable CBC/Chemistry Panel

Canine Urinalysis- pH 7.5, Specific gravity 1.049, 1+protein, 1+blood with RBCs

BREED ULTRASONOGRAPHIC EXAMINATION OF THE ABDOMEN

Lab Mix *Urinary System*

SEX The urinary bladder, trigone, cystourethral junction, and visible pelvic urethra to a depth of 4.0 cm exhibited normal thickness and tone. Anechoic urine was present in the lumen with no uroliths or sediment. The ureteral papillae were normal. The ureters were not visible which is normal. No evidence of inflammatory or neoplastic changes was noted.

MN The residual prostate was symmetrically normal in size with uniform parenchyma and slight coarse echotexture measuring 1.4 cm in diameter.

AGE The area of the aortic trifurcation was free of pathology.

2016 Normal size and margination were present in the kidneys. A normal 1:3 cortex / medulla ratio and normal corticomodullary definition were maintained. The echogenicity of the cortex was similar to or slightly less than normal liver parenchyma while the medulla echogenicity was hypoechoic to the cortex with no evidence of pelvic dilation. The left kidney measured 7.2 cm in length. The right kidney measured 7.1 cm in length.

WEIGHT

102

INTERPRETED BY

R. McKenzie Daniel,
DVM, DABVP
(Canine and Feline)

Adrenal Glands

The left adrenal gland was uniform in size and contour with a uniformly hypoechoic parenchyma. The left adrenal gland measured 2.4 cm length x 0.56 cm width at the caudal pole. The right adrenal gland was uniform in size and contour with a uniformly hypoechoic parenchyma. The right adrenal gland measured 2.9 cm length x 0.55 cm width at the caudal pole.

IMAGING PERFORMED BY

Rebekah Jakum, CVT
ARDMS/RVT

Spleen

The spleen exhibited a finely textured and homogenous parenchyma which was hyperechoic to the liver and renal cortical parenchyma. The capsule was smooth and regular without apparent expansion. The splenic vasculature at the hilus was normal in volume with no evidence of congestion or thrombosis. Acute to chronic inflammatory, neoplastic, or benign parenchyma changes were not noted.

HOSPITAL NAME

Mill Pond VC

REFERRING VET

Dr. Thayer

Liver/ Gallbladder

The liver was subjectively normal in size, structure, and contour. The liver parenchyma was uniform and hypoechoic to the spleen with a mild coarse echotexture. The hepatic and portal vasculature were normal in appearance without signs of congestion. The gallbladder was non-distended in size with thin walls and primarily anechoic luminal content. The cystic and common bile ducts were normal.

INVOICE

15457

DATE

11/10/22



PATIENT *Gastrointestinal*

Remy Frantz The stomach presented intact wall layering with a normal wall layer ratio. The lumen of the stomach was empty with no signs of ileus, obstruction, or foreign material.

SPECIES The small intestine presented intact wall layering with 1:3 muscularis/mucosa ratio. The lumen of the small intestine was empty with no signs of ileus, obstruction, or foreign material.

Canine Normal visible colon wall layers were present with apparent formed feces in lumen.

BREED *Pancreas*

Lab Mix The parenchyma of the left limb, body, and right limb of the pancreas presented isoechoic to the adjacent omental fat. A normal curvilinear capsule contour of the pancreas was present. The visible pancreatic duct was normal. No signs of active inflammation or neoplastic disease were evident.

SEX

MN *Free Abdomen*

No overt lymphadenopathy or peritoneal effusion was present.

AGE **ULTRASONOGRAPHIC FINDINGS**

- Sonographically unremarkable urinary bladder, residual prostate, and visible proximal urethra
- Normal bilateral kidneys - no evidence of pyelonephritis

WEIGHT **INTERPRETATION OF THE FINDINGS & FURTHER RECOMMENDATIONS**

102 Overall, sonographically normal abdomen without evidence of visceral, specifically upper or lower urinary tract pathology as an obvious cause of the patient's hematuria. Urine C/S on a sterile urine sample is recommended to assess for underlying infection if not done. If no evidence of inflammatory sediment, a baseline UPC level could also be considered as additional renal staging given the mild proteinuria. Urinary diet may be considered if persistent or significant crystal urea.

INTERPRETED BY

R. McKenzie Daniel,
DVM, DABVP
(Canine and Feline)

IMAGING

PERFORMED BY
Rebekah Jakum, CVT
ARDMS/RVT

HOSPITAL NAME

Mill Pond VC

REFERRING VET

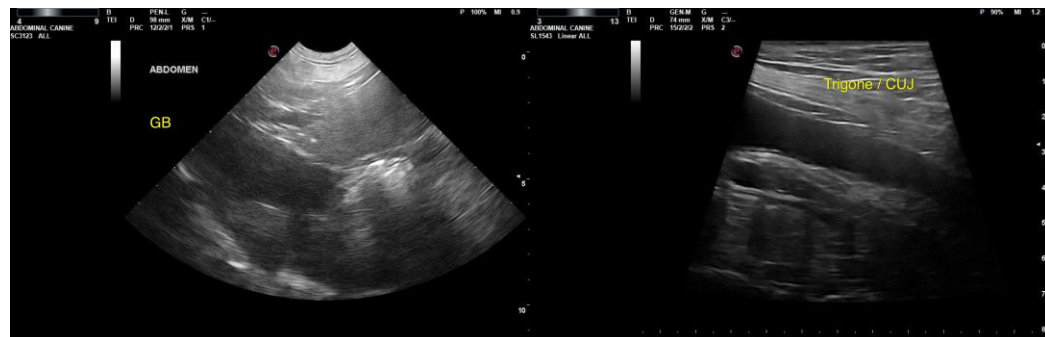Dr. Thayer

INVOICE

15457

DATE

11/10/22





PATIENT

Remy Frantz

SPECIES

Canine

BREED

Lab Mix

SEX

MN

AGE

2016

WEIGHT

102

INTERPRETED BY

R. McKenzie Daniel,
DVM, DABVP
(Canine and Feline)

**IMAGING
PERFORMED BY**

Rebekah Jakum, CVT
ARDMS/RVT

HOSPITAL NAME

Mill Pond VC

REFERRING VET

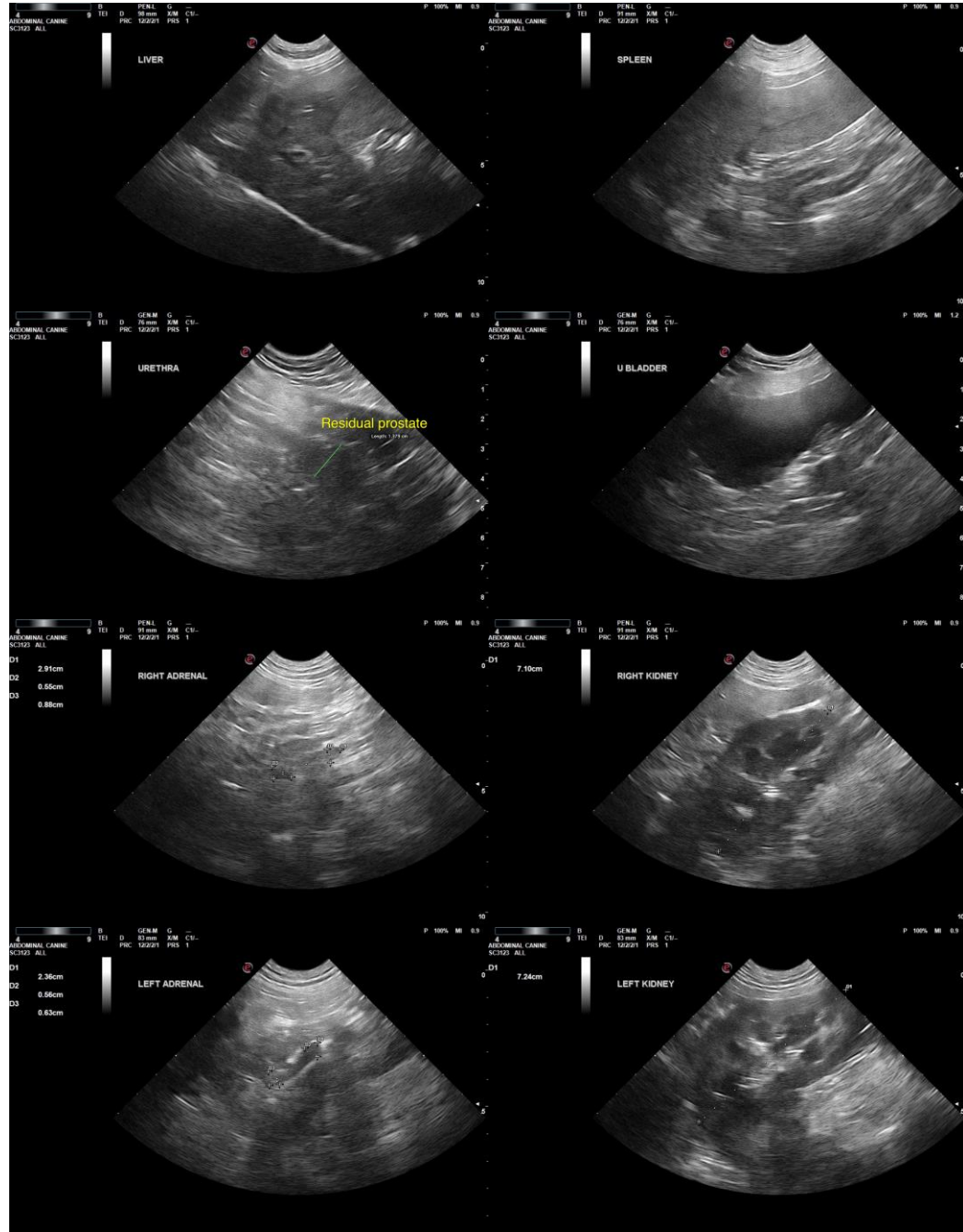
Dr. Thayer

INVOICE

15457

DATE

11/10/22



The information and recommendations provided are based on the images presented by the referring veterinarian/sonographer. No evaluation can be communicated regarding pathology that was not visible in the image/video clips provided.

Thank you for this referral. If the clinical or image interpretation does not parallel your findings or if I can be of any further assistance, please contact me.

R. McKenzie Daniel, DVM, DABVP (Canine/Feline Practitioner)
mac.daniel@sonopath.com