



PATIENT

Penny Ronan

SPECIES

Canine

BREED

Beagle

SEX

FS

AGE

12 y

WEIGHT

28 lbs.

INTERPRETED BY

R. McKenzie Daniel, DVM,
 DABVP (Canine and Feline)

IMAGING PERFORMED BY

Pamela Harrigan, RDMS

HOSPITAL NAME

Norfolk County
 Veterinary Service

REFERRING VET

Aurora Richards, DVM

INVOICE

15464

DATE

11/10/22

PRESENTING CLINICAL SIGNS

Patient presented ADR. Normal bloodwork except low platelets and positive for Anaplasmosis. Started Doxycycline and Prednisone. Platelets rebounded and then at weaning dose had dropped again so unlikely tick related. Likely ITP (r/o underlying neoplasia). Current meds and doses: Prednisone at immunosuppressive dose. Cyclosporine. Doxycycline.

ULTRASONOGRAPHIC EXAMINATION OF THE ABDOMEN

Urinary System

The urinary bladder, trigone, cystourethral junction, and visible pelvic urethra to a depth of 3.0 cm exhibited normal thickness and tone. Anechoic urine was present in the lumen with focal dependent luminal mineral. The ureteral papillae were normal. The ureters were not visible which is normal. No evidence of inflammatory or neoplastic changes was noted.

The area of the aortic trifurcation was free of pathology.

Normal size and margination were present in the kidneys. A normal 1:3 cortex / medulla ratio was maintained. The medulla and cortices were uniform in texture with some increased echogenicity and mild loss of corticomedullary symmetry and definition expected for the age of the patient. No evidence of pelvic dilation was present. Right kidney focal areas of medullary mineral were noted. The left kidney measured 5.4 cm in length. The right kidney measured 5.1 cm in length.

Adrenal Glands

The left adrenal gland was uniform in size and contour with a uniformly hypoechoic parenchyma. The left adrenal gland measured 0.37 cm width at the caudal pole and 0.36 cm width at the cranial pole. The right adrenal gland was uniform in size and contour with a uniformly hypoechoic parenchyma. The right adrenal gland measured 0.36 cm width at the caudal pole.

Spleen

The spleen was normal in size exhibiting mild asymmetrical medial capsule margination and potential for focal areas of benign medial capsule fibrosis. The splenic vasculature at the hilus was normal in volume with no evidence of congestion or thrombosis. The parenchymal heterogeneity is likely consistent with benign changes such as extramedullary hematopoiesis or age-related remodeling with minor potential for inflammatory or neoplastic disease.

Liver/ Gallbladder

The liver presented enlarged in size. The parenchyma of the liver was subjectively normal in echogenicity compared to the spleen and renal cortices. The liver parenchyma was uniform with a mildly coarse echotexture. A solitary nondisruptive mildly hyperechoic intraparenchymal nodule was present in the mid-caudal liver measuring 1.1 cm in diameter. The capsule of the liver was symmetrically rounded to mildly swollen in margination. The hepatic and portal vasculature were normal in appearance without signs of congestion. The gallbladder was non-distended in size



PATIENT

Penny Ronan

containing mild nondependent variably echogenic to focally hyperechoic nonorganized mobile debris. The cystic and common bile ducts were normal.

SPECIES

Canine

Gastrointestinal

The stomach presented intact wall layering with a normal wall layer ratio. The lumen of the stomach was empty with no signs of ileus, obstruction, or foreign material.

BREED

Beagle

The small intestine presented intact wall layering with 1:3 muscularis/mucosa ratio. The lumen of the small intestine was empty with no signs of ileus, obstruction, or foreign material.

Normal visible colon wall layers were present with apparent formed feces in lumen.

SEX

FS

Pancreas

The parenchyma of the left limb, body, and right limb of the pancreas presented isoechoic to the adjacent omental fat. A normal curvilinear capsule contour of the pancreas was present. The visible pancreatic duct was normal. No signs of active inflammation or neoplastic disease were evident.

AGE

12 y

Free Abdomen

No omental masses, lymphadenopathy, or evidence of peritoneal free fluid were noted.

WEIGHT

28 lbs.

ULTRASONOGRAPHIC FINDINGS

- Hepatomegaly with solitary benign intraparenchymal nodule - nodule consistent with solitary nodular hyperplasia or benign lipogranuloma
- Mild gallbladder debris (non-mucocele)
- Age-related spleen - no evidence of neoplastic criteria
- Mild chronic renal changes with focal minor right kidney medullary mineral
- Focal dependent urinary bladder mineral

INTERPRETED BY

R. McKenzie Daniel, DVM,
DABVP (Canine and Feline)

**IMAGING
PERFORMED BY**

Pamela Harrigan, RDCS

INTERPRETATION OF THE FINDINGS & FURTHER RECOMMENDATIONS

This patient may be passing small amounts of mineral from the right kidney into the urinary bladder. Further renal staging to include urine C/S and protein: creatinine ratio on sterile urine sample may be considered. No evidence of intraabdominal neoplastic criteria as a primary cause or contributing factor to suspected ITP. Assessment of hepatic enzyme levels +/- hepatosupportive medications i.e., Denamarin and Ursodiol may be considered if clinically indicated.

HOSPITAL NAME

Norfolk County
Veterinary Service

REFERRING VET

Aurora Richards, DVM

INVOICE

15464

DATE

11/10/22



PATIENT

Penny Ronan

SPECIES

Canine

BREED

Beagle

SEX

FS

AGE

12 y

WEIGHT

28 lbs.

INTERPRETED BY

R. McKenzie Daniel, DVM,
 DABVP (Canine and Feline)

IMAGING PERFORMED BY

Pamela Harrigan, RDCS

HOSPITAL NAME

Norfolk County
 Veterinary Service

REFERRING VET

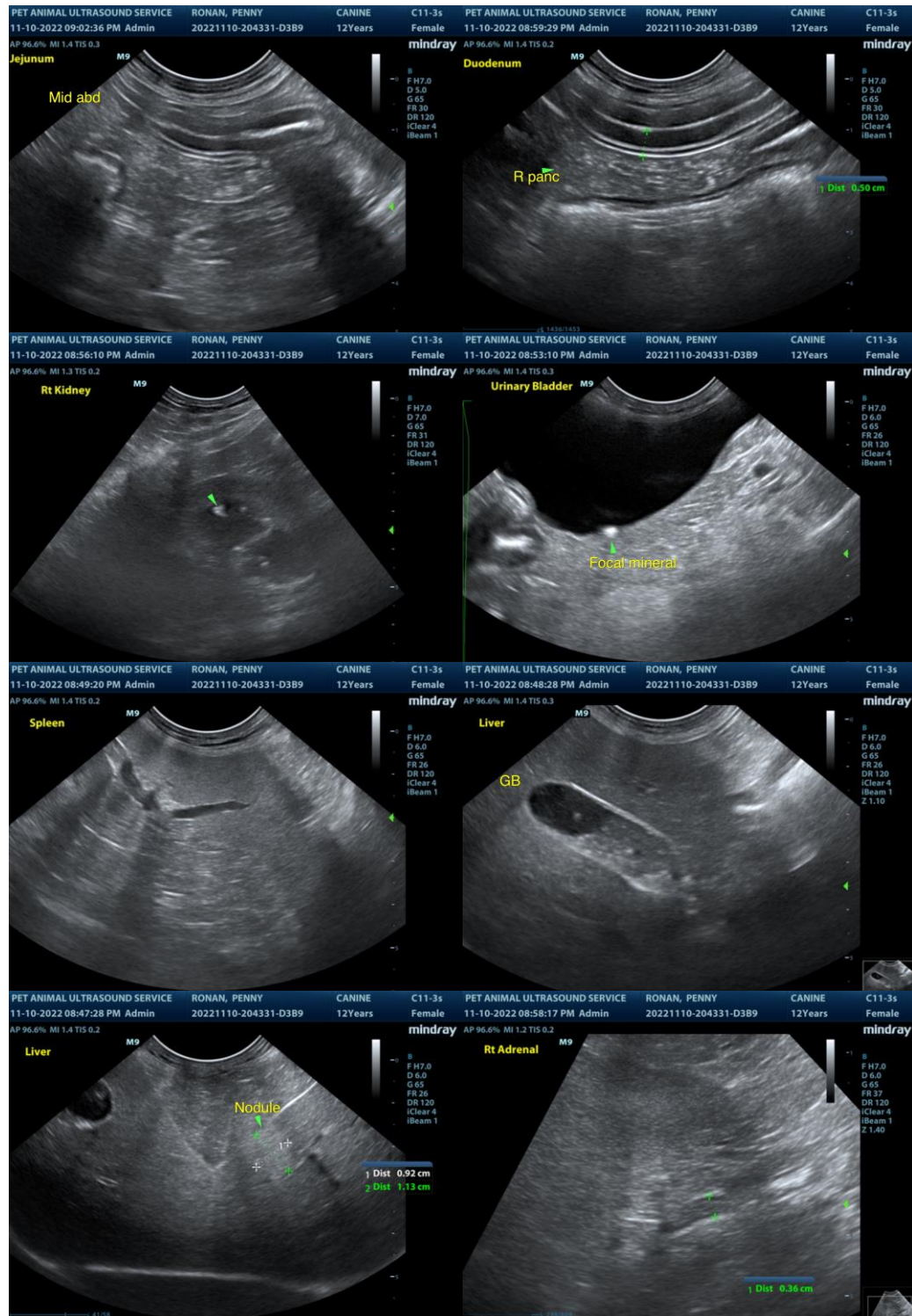
Aurora Richards, DVM

INVOICE

15464

DATE

11/10/22





PATIENT

Penny Ronan

SPECIES

Canine

BREED

Beagle

SEX

FS

AGE

12 y

WEIGHT

28 lbs.

INTERPRETED BY

R. McKenzie Daniel, DVM,
 DABVP (Canine and Feline)

**IMAGING
 PERFORMED BY**

Pamela Harrigan, RDCS

HOSPITAL NAME

Norfolk County
 Veterinary Service

REFERRING VET

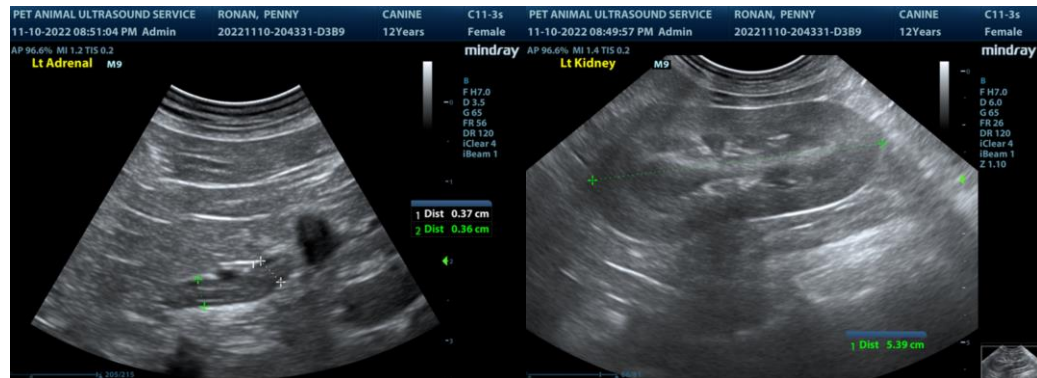
Aurora Richards, DVM

INVOICE

15464

DATE

11/10/22



The information and recommendations provided are based on the images presented by the referring veterinarian/sonographer. No evaluation can be communicated regarding pathology that was not visible in the image/video clips provided.

Thank you for this referral. If the clinical or image interpretation does not parallel your findings or if I can be of any further assistance please contact me.

R. McKenzie Daniel, DVM, DABVP (Canine / Feline Practice)
info@SonoPath.com