



PATIENT

Nibbles Fox

SPECIES

Canine

BREED

Havanese

SEX

FS

AGE

15 years

WEIGHT

16.3 lbs.

INTERPRETED BY

R. McKenzie Daniel, DVM,
 DABVP (Canine and Feline)

**IMAGING
 PERFORMED BY**

Pamela Harrigan, RDMS

HOSPITAL NAME

Norfolk County
 Veterinary Service

REFERRING VET

Amelia Ragon, DVM

INVOICE

15462

DATE

11/10/22

PRESENTING CLINICAL SIGNS

Diagnosed with TCC (pos. BRAF) and splenic mass which FNA sample showed likely as a sarcoma on AUS 9/15/22 (R. McKenzie Daniel, DVM, DABVP). Owner wants to assess progression of cancer. Patient is clinically doing well at home. * Study limited to spleen and urinary bladder.

ULTRASONOGRAPHIC EXAMINATION OF THE SPLEEN AND URINARY BLADDER

Urinary System

Previously noted sessile based, small, nonhomogeneous mass was present in the mid-dorsal urinary bladder wall extending mildly into the urinary bladder lumen measuring 1.4 cm x 0.92 cm. No other evidence of urinary bladder mural lesions or neoplastic criteria. Anechoic urine was present in the lumen with no sediment or calculi. The urethra exhibited normal structure and tone to a depth of 2.0 cm.

Previously noted focal, nonhomogeneous to nodular medial iliac lymph node was present dorsal to the urinary bladder measuring 2.7 cm x 0.51 cm.

Spleen

Previously noted, expansive, nonhomogeneous, hypoechoic splenic mass with associated asymmetrical splenic capsule distortion was present in the subjective mid to cranial spleen measuring approximately 3.0 cm in diameter. The splenic parenchyma not involved with the mass exhibited primarily maintained finely textured homogeneous parenchyma. Potential, although not definitive, concurrent nondisruptive hypoechoic parenchymal nodule directly adjacent to the splenic mass was noted, measuring 0.7 cm in diameter. Normal splenic vascularity was present. Potential focal extension of the mass into the adjacent splenic parenchyma is possible. No evidence of perisplenic or peritoneal free fluid.

ULTRASONOGRAPHIC FINDINGS

- Static sessile based dorsal urinary bladder mass
- Overall static splenic mass, potential extension into regional splenic parenchyma vs. adjacent nondisruptive similar appearing nodule
- Mildly progressive yet similar appearing nonhomogeneous focally nodular medial iliac lymphadenopathy

INTERPRETATION OF THE FINDINGS & FURTHER RECOMMENDATIONS

Overall static pathology compared to the previous ultrasound with evidence of mild increased medial iliac lymphadenopathy. Continued sonographic monitoring based on the clinical impression of the patient or oncology recommendations is suggested.



PATIENT

Nibbles Fox

SPECIES

Canine

BREED

Havanese

SEX

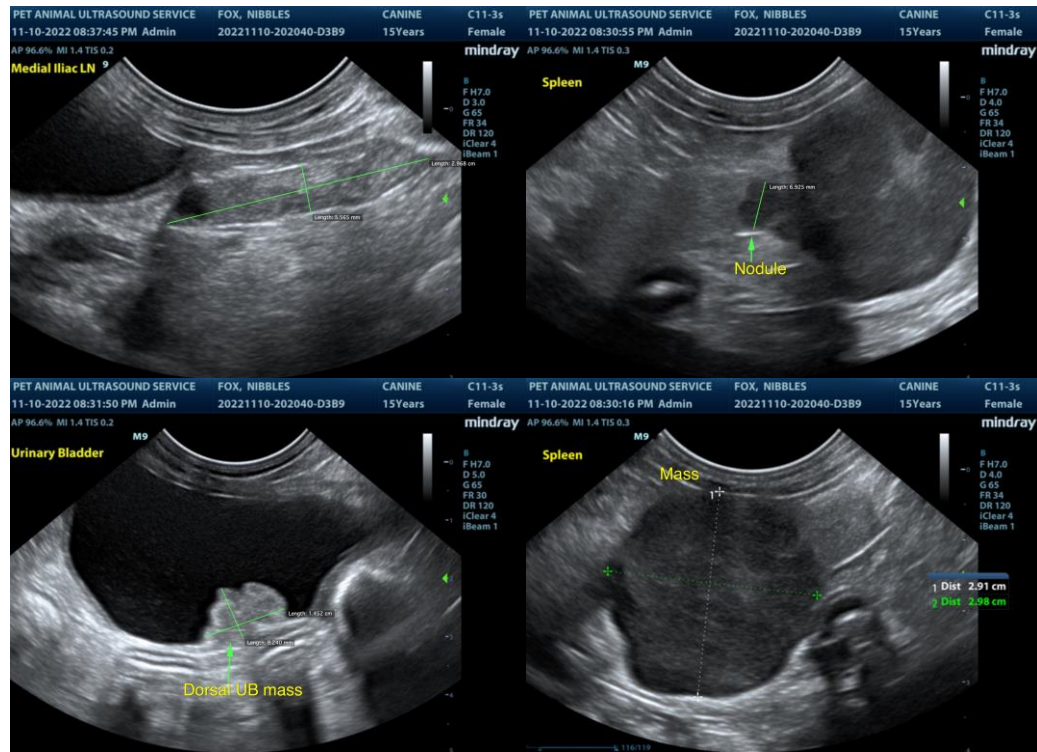
FS

AGE

15 years

WEIGHT

16.3 lbs.



INTERPRETED BY
 R. McKenzie Daniel, DVM,
 DABVP (Canine and Feline)

IMAGING PERFORMED BY
 Pamela Harrigan, RDCS

The information and recommendations provided are based on the images presented by the referring veterinarian/sonographer. No evaluation can be communicated regarding pathology that was not visible in the image/video clips provided.

Thank you for this referral. If the clinical or image interpretation does not parallel your findings or if I can be of any further assistance please contact me.

HOSPITAL NAME

Norfolk County
 Veterinary Service

REFERRING VET

Amelia Ragon, DVM

R. McKenzie Daniel, DVM, DABVP (Canine / Feline Practice)
info@SonoPath.com

INVOICE

15462

DATE

11/10/22