



**PATIENT**

Mia Kane

**SPECIES**

Canine

**BREED**

Bichon Frise

**SEX**

Female Intact

**AGE**

6 months

**WEIGHT**

2.8 kg

**INTERPRETED BY**

R. McKenzie Daniel,  
DVM, DABVP  
(Canine and Feline)

**IMAGING PERFORMED BY**

Dr. Sarah Barthelemy

**HOSPITAL NAME**

Sunridge Vet Clinic

**REFERRING VET**

Dr. Duncan

**INVOICE**

15316

**DATE**

11/1/22

**PRESENTING CLINICAL SIGNS**

Mild ALT elevation on pre-spay labs. No clinical signs.

Abnormal PE/Chem/CBC/UA Results: Mild ALT elevation 165. Post bile acids 81. Pre was normal.

**ULTRASONOGRAPHIC EXAMINATION OF THE ABDOMEN**

**Urinary System**

The urinary bladder, trigone, cystourethral junction, and visible pelvic urethra to a depth of 1.0 cm exhibited normal thickness and tone. Anechoic urine was present in the lumen with no sediment or calculi. The ureteral papillae were normal. The ureters were not visible which is normal. No evidence of inflammatory or neoplastic changes was noted.

The area of the aortic trifurcation was free of pathology.

Normal size and margination were present in the kidneys. A normal 1:3 cortex / medulla ratio and normal corticomedullary definition were maintained. The echogenicity of the cortex was similar to or slightly less than normal liver parenchyma while the medulla echogenicity was hypoechoic to the cortex with no evidence of pelvic dilation. Pinpoint hyperechoic medullary foci, which may indicate pinpoint areas of medullary mineral, were present. No evidence of renal macro calculi or renomegaly. The left kidney measured 3.1 cm in length. The right kidney measured 3.1 cm in length.

**Adrenal Glands**

The left adrenal gland was uniform in size and contour with a uniformly hypoechoic parenchyma. The left adrenal gland measured 0.29 cm width at the caudal pole and 0.28 cm width at the cranial pole. The right adrenal gland was uniform in size and contour with a uniformly hypoechoic parenchyma. The right adrenal gland measured 0.21 cm width at the caudal pole and 0.24 cm width at the cranial pole.

**Spleen**

The spleen exhibited a finely textured and homogenous parenchyma which was hyperechoic to the liver and renal cortical parenchyma. The capsule was smooth and regular without apparent expansion. The splenic vasculature at the hilus was normal in volume with no evidence of congestion or thrombosis. Acute to chronic inflammatory, neoplastic, or benign parenchyma changes were not noted.

**Liver/ Gallbladder**

The liver exhibited normal to possible borderline subjective subnormal overall size, maintained symmetrical capsule contour, and uniform normal parenchyma echogenicity. Subjective adequate hepatic vascular volume was noted. The visualized portal vein appeared to exhibit normal volume compared to the adjacent caudal vena cava with approximate 1:1 portal vein /caudal vena cava ratio. Suspect normal portal vein branching is noted. The gallbladder was non-distended in size with thin walls and primarily anechoic luminal content. The cystic and common bile ducts were normal.

**Gastrointestinal**

The stomach presented intact wall layering with a normal wall layer ratio. The lumen of the stomach was empty with no signs of ileus, obstruction, or foreign material.



**PATIENT**

Mia Kane

**SPECIES**

Canine

**BREED**

Bichon Frise

**SEX**

Female Intact

**AGE**

6 months

**WEIGHT**

2.8 kg

**INTERPRETED BY**

R. McKenzie Daniel,  
DVM, DABVP  
(Canine and Feline)

**IMAGING PERFORMED BY**

Dr. Sarah Barthelemy

**HOSPITAL NAME**

Sunridge Vet Clinic

**REFERRING VET**

Dr. Duncan

**INVOICE**

15316

**DATE**

11/1/22

The small intestine presented intact wall layering with 1:3 muscularis/mucosa ratio. The lumen of the small intestine was empty with no signs of ileus, obstruction, or foreign material.

Normal visible colon wall layers were present with apparent formed feces in lumen.

**Pancreas**

The parenchyma of the left limb, body, and right limb of the pancreas presented isoechoic to the adjacent omental fat. A normal curvilinear capsule contour of the pancreas was present. The visible pancreatic duct was normal. No signs of active inflammation or neoplastic disease were evident.

**Free Abdomen**

No overt lymphadenopathy or peritoneal effusion was present.

**ULTRASONOGRAPHIC FINDINGS**

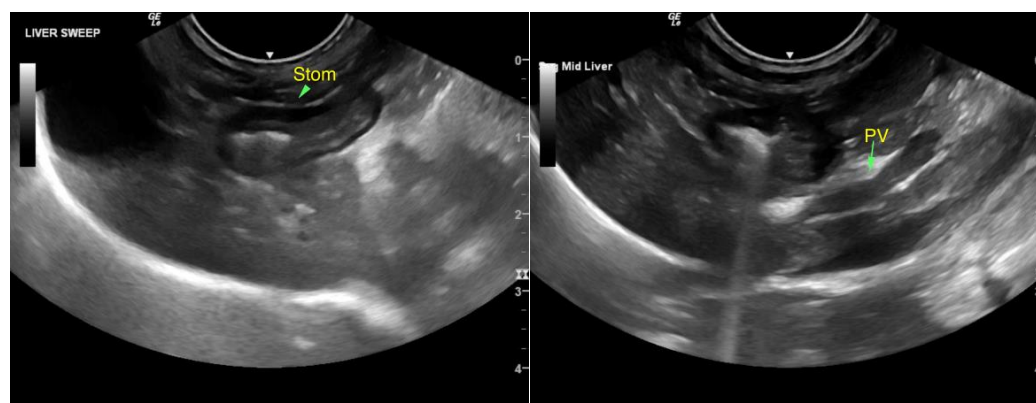
- Low-grade hepatopathy - suspect low-grade inflammatory hepatopathy with potential for

**INTERPRETATION OF THE FINDINGS & FURTHER RECOMMENDATIONS**

No overt evidence of definitive macroscopic portosystemic shunt, which is considered a less likely differential diagnosis given hepatic presentation and lack of commonly seen secondary abnormalities such as renal or cystic mineral / calculi.

Assuming normal clotting status, screening FNA hepatic cytology could be considered to assess for potential inflammatory cell type, if present. Core surgical biopsy is likely required for further definition as to whether portal hypoplasia / microvascular dysplasia is present. Hepatic functionality is likely adequate assuming normal albumin, glucose, BUN, and cholesterol levels. A clinical trial of some or all of the following could be considered if clinically indicated.

**Royal Canin Hepatic Support diet or Hills L/D, Metronidazole** (7.5 mg/kg PO bid) over the next 14 days, **Lactulose** (Oral: 3.1-3.7 g/5 ml lactulose in a syrup base) long term to target 2-3 soft stools/day, with a **high-quality protein supplement** of minor amount of **yogurt** or **cheddar cheese**. Monitor bile acids, with attention paid to dropping albumin, BUN or cholesterol. SAME and nutraceuticals as needed. **Ursodiol** (10-15 mg/kg p.o. q24h) can be considered as hepatoprotectant and to enhance bile flow. **Zinc** serum level keep between 200—500 ug/dl. If deficient then Tx zinc acetate 1-3 mg/kg/day. Gastrointestinal protectants are recommended if the patient is anorexic.





**PATIENT**

Mia Kane

**SPECIES**

Canine

**BREED**

Bichon Frise

**SEX**

Female Intact

**AGE**

6 months

**WEIGHT**

2.8 kg

**INTERPRETED BY**

R. McKenzie Daniel,  
DVM, DABVP  
(Canine and Feline)

**IMAGING PERFORMED BY**

Dr. Sarah Barthelemy

**HOSPITAL NAME**

Sunridge Vet Clinic

**REFERRING VET**

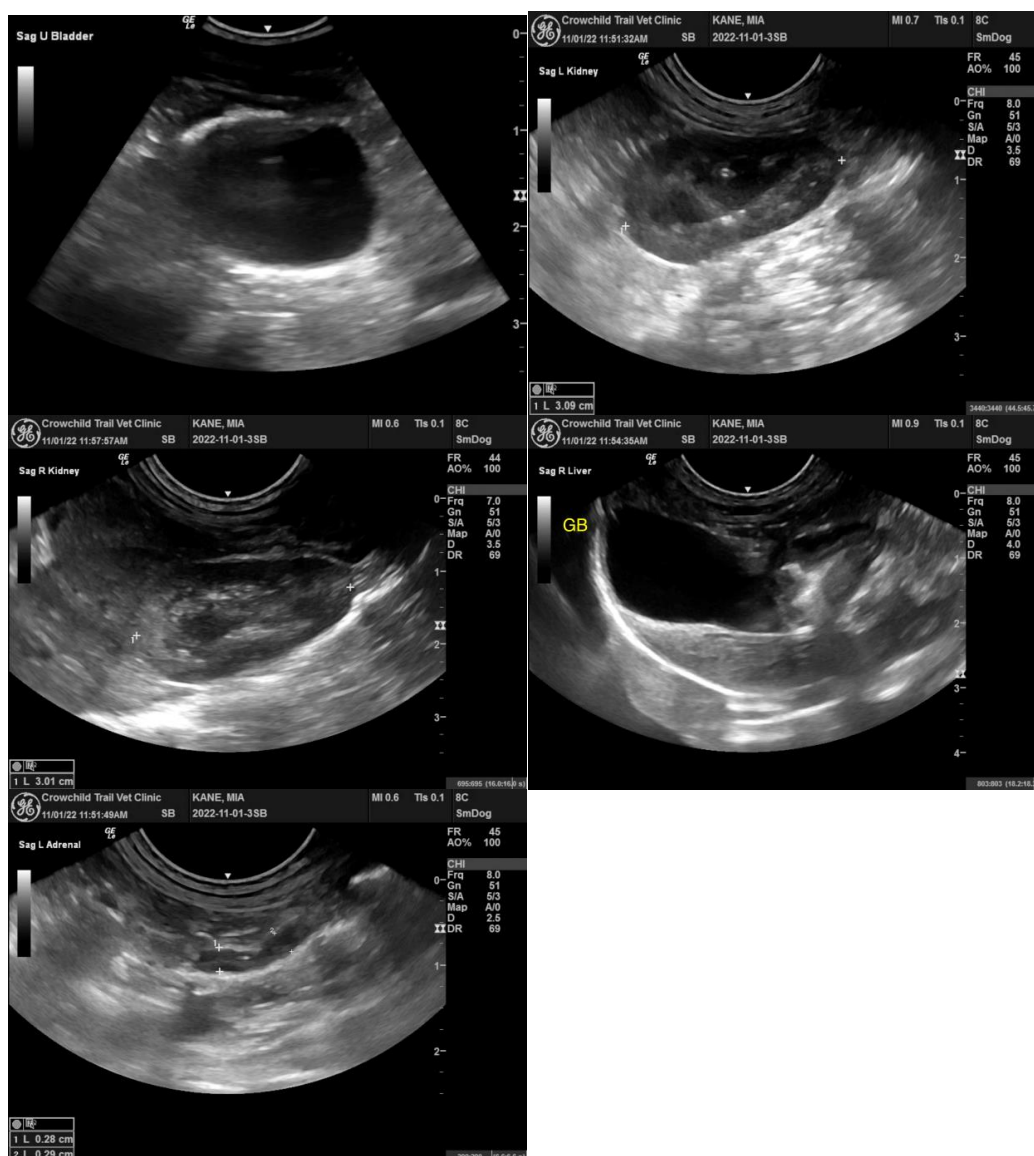
Dr. Duncan

**INVOICE**

15316

**DATE**

11/1/22



**The information and recommendations provided are based on the images presented by the referring veterinarian/sonographer. No evaluation can be communicated regarding pathology that was not visible in the image/video clips provided.**

Thank you for this referral. If the clinical or image interpretation does not parallel your findings or if I can be of any further assistance please contact me.

**R. McKenzie Daniel, DVM, DABVP (Canine / Feline Practice)**  
info@SonoPath.com