



## PATIENT

Jasper Fincher

## SPECIES

Feline

## BREED

DSH

## SEX

MN

## AGE

6 years

## WEIGHT

9.76 lbs.

## INTERPRETED BY

R. McKenzie Daniel,  
DVM, DABVP  
(Canine and Feline)

## IMAGING PERFORMED BY

Dr. Mavis  
McCormick-Rantze

## HOSPITAL NAME

Lanier AH

## REFERRING VET

Dr. Mavis  
McCormick-Rantze

## INVOICE

12501

## DATE

11/1/21

## PRESENTING CLINICAL SIGNS

Patient presented for annual exam and bloodwork.

Abnormal PE/Chem/CBC/UA Results: On PE normal; cbc/chem wnl/nsf but Pro BNP 498. Doing a baseline Echo.

## ULTRASONOGRAPHIC EXAMINATION OF THE HEART

FELINE CARDIAC PARAMETERS	BODY WEIGHT (kg)	HR (BPM)	IVSd (cm)	LVIDd (cm)	LVWd (cm)	FS (%)	EF (%)
NORMAL PARAMETER	-----	150-240	0.3-0.6	1.0-2.1	0.25-0.6	35-67	80-100
PATIENT		NM	0.38	1.38	0.36	60	94.1
FELINE CARDIAC PARAMETERS	LA/AO (Boon)	LA/AO HEART BASE (Sisson)	LA 2D 4-chamber long axis AS to FW (Sisson) (cm)	LVOT VEL. (m/s)	RVOT VEL. (m/s)	IVRT (m/)	
NORMAL PARAMETER	<1.5	0.88-1.79	0.7-1.7	<1.6	<1.3	40-60	
PATIENT		1.5	1.3	NM	NM	NM	
Adapted from June Boon, Veterinary Echocardiography, 1998 Sisson D et al. JVIM 1991; 5: 232, Jacobs et al. Am J Vet Res 1985; 46:1705							

## Cardiac Presentation

The echocardiogram in this patient demonstrated normal **left atrial** size based on 3 separate LA measurements. The cranial and caudal **mitral** valve leaflets presented normal linear structure and kinetics. The **left ventricle** presented normal thicknesses with linear contour and was not dilated nor restricted. The **myocardium** presented normal echogenicity without subjective evidence of significant fibrotic or ischemic disease. **Contractility** of the ventricular walls was adequate and in normal range for this patient evidenced by the fractional shortening measurement and subjective evaluation of the different regions and angles of the myocardium. The **left ventricular outflow** tract demonstrated normal laminar flow and subjective structural integrity. The **right atrium** and auricle revealed normal size, structure and content. No evidence of masses was noted or chamber overload. **Tricuspid** valvular assessment demonstrated adequate linear morphology and kinetics. The **right ventricle** was of normal size (1/3 diameter of LV), chordae structure, myocardial echogenicity and thickness. **Pulmonic** tract assessment revealed normal valve structure, laminar flow, and diameter (approx. 1:1 pa/ao ratio). No visible **pericardial** or free pleura fluid was noted or extra cardiac pathology in the visible planes. The cranial **mediastinum and pericardial regions** were free of masses in the visible window.



**PATIENT**

Jasper Fincher

**SPECIES**

Feline

**BREED**

DSH

**SEX**

MN

**AGE**

6 years

**WEIGHT**

9.76 lbs.

**INTERPRETED BY**

R. McKenzie Daniel,  
DVM, DABVP  
(Canine and Feline)

**IMAGING PERFORMED BY**

Dr. Mavis  
McCormick-Rantze

**HOSPITAL NAME**

Lanier AH

**REFERRING VET**

Dr. Mavis  
McCormick-Rantze

**INVOICE**

12501

**DATE**

11/1/21

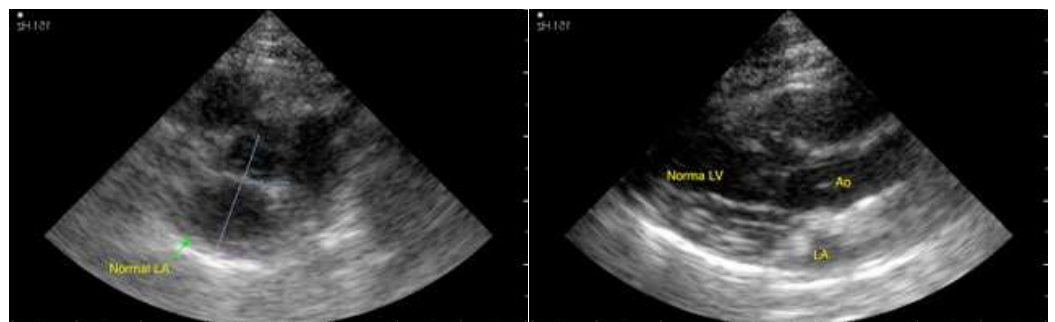
**ULTRASONOGRAPHIC FINDINGS**

**Primary Findings**

- Normal echocardiogram

**INTERPRETATION OF THE FINDINGS & FURTHER RECOMMENDATIONS**

Overtly normal cardiac structure and function. No evidence of cardiomyopathy. Recheck echocardiogram as needed based on the clinical impression of the patient if increasing BNP levels are noted or if a murmur develops.



**The information and recommendations provided are based on the images presented by the referring veterinarian. No evaluation can be communicated regarding pathology that was not visible in the image/video clips provided.**

Thank you for this referral. If the clinical or image interpretation does not parallel your findings or if I can be of any further assistance please contact me.

**R. McKenzie Daniel, DVM, DABVP (Canine / Feline Practice)**  
info@SonoPath.com