



PATIENT

Truman Caputo

SPECIES

Canine

BREED

Golden Retriever

SEX

Intact Male

AGE

2008

WEIGHT

103.2

INTERPRETED BY

R. McKenzie Daniel,
DVM, DABVP
(Canine and Feline)

**IMAGING
PERFORMED BY**

Amanda Crook -
SDEP Certified
Clinical Sonographer

HOSPITAL NAME

Rivers Edge PMC

REFERRING VET

Dr. Cora Hollomon

INVOICE

12384

DATE

10/7/21

PRESENTING CLINICAL SIGNS

P presented for seizure like activity on 10/5 with pale mm's and distended abdomen. Took home gabapentin, entyce and yunnan bai yao until abdominal ultrasound was performed today.

Abnormal PE/Chem/CBC/UA Results: No labwork and no radiographs performed at this time.

ULTRASONOGRAPHIC EXAMINATION OF THE ABDOMEN

Urinary System

The urinary bladder, trigone, and cystourethral junction exhibited normal thickness and tone. Anechoic urine was present in the lumen with no uroliths or sediment. The ureteral papillae were normal. The ureters were not visible which is normal. No evidence of inflammatory or neoplastic changes was noted.

The prostate was enlarged in size with intact, symmetrical capsule contour. The margins of the gland were intact and able to be differentiated from the surrounding tissue. The prostatic parenchyma was mildly echogenic to heteroechoic without parenchymal mineralization. The prostate measured 4.6 cm x 4.5 cm.

The area of the aortic trifurcation was free of pathology.

Normal size and margination were present in the kidneys. A normal 1:3 cortex / medulla ratio was maintained. The medulla and cortices were uniform in texture with some increased echogenicity and mild loss of corticomedullary symmetry and definition expected for the age of the patient. No evidence of pelvic dilation was present. The left kidney measured 9.4 cm in length. The right kidney measured 9.0 cm in length.

Adrenal Glands

The bilateral adrenal glands were normal in size. Mild parenchyma heterogeneity and mild capsule asymmetry was present without suspicion for overt neoplasia. The left adrenal gland measured 2.7 cm length x 0.65 cm width in the caudal pole. The right adrenal gland measured 3.1 cm x 0.49 cm width in the caudal pole.

Spleen

The spleen exhibited generalized enlargement with nonuniform parenchyma echotexture and echogenicity. A mildly expansive, nonhomogeneous to cavitated mass was present in the mid to caudal spleen, measuring approximately 6.0 cm x 6.0 cm.

Liver/ Gallbladder

The liver exhibited generalized enlargement with nonuniform to focally nodular parenchyma and moderate coarse echotexture. Asymmetrical hepatic contour in the ventral and caudal liver margins was present. An example of a liver nodule measured 2.0 cm in diameter. The gallbladder was non-distended in size with mild gallbladder debris. The cystic and common bile ducts were normal.

Gastrointestinal

The stomach presented intact wall layering with a normal wall layer ratio. The lumen of the stomach was empty with no signs of ileus, obstruction, or foreign material.



PATIENT

Truman Caputo

The small intestine presented intact wall layering with 1:3 muscularis/mucosa ratio. The lumen of the small intestine was empty with no signs of ileus, obstruction, or foreign material.

SPECIES

Canine

Normal visible colon wall layers were present with apparent formed feces in lumen.

BREED

Golden Retriever

Pancreas

The parenchyma of the left limb, body, and right limb of the pancreas presented isoechoic to the adjacent omental fat. A normal curvilinear capsule contour of the pancreas was present. The visible pancreatic duct was normal. No signs of active inflammation or neoplastic disease were evident.

SEX

Intact Male

Free Abdomen

No overt lymphadenopathy or peritoneal effusion was present.

AGE

2008

Regional perihepatic and perisplenic reactive mesentery along with mild to moderate free fluid were present.

WEIGHT

103.2

Rapid view of the heart revealed no overt evidence of pericardial masses or definitive pericardial effusion.

ULTRASONOGRAPHIC FINDINGS

Primary Findings

- Benign prostatic hyperplasia
- Infiltrative hepatosplenic neoplasia pattern with moderately expansive nonhomogeneous to cavitated splenic mass and intermittent hepatic nodules
- Perihepatic and perisplenic reactive mesentery
- Peritoneal free fluid - confirmed hemoabdomen

Secondary Findings

- Bilateral mild chronic renal changes

INTERPRETED BY

R. McKenzie Daniel,
DVM, DABVP
(Canine and Feline)

INTERPRETATION OF THE FINDINGS & FURTHER RECOMMENDATIONS

Unfortunately, the appearance of the liver and spleen are consistent with multicentric neoplasia, sarcoma, round cell or other. The potential for regional perihepatic and perisplenic omental seeding is also of concern yet not definitive.

IMAGING PERFORMED BY

Amanda Crook -
SDEP Certified
Clinical Sonographer

HOSPITAL NAME

Rivers Edge PMC

REFERRING VET

Dr. Cora Hollomon

INVOICE

12384

However, unfortunately, surgical options appear to be precluded in this case. A poor prognosis is warranted.

DATE

10/7/21



PATIENT

Truman Caputo

SPECIES

Canine

BREED

Golden Retriever

SEX

Intact Male

AGE

2008

WEIGHT

103.2

INTERPRETED BY

R. McKenzie Daniel,
DVM, DABVP
(Canine and Feline)

IMAGING PERFORMED BY

Amanda Crook -
SDEP Certified
Clinical Sonographer

HOSPITAL NAME

Rivers Edge PMC

REFERRING VET

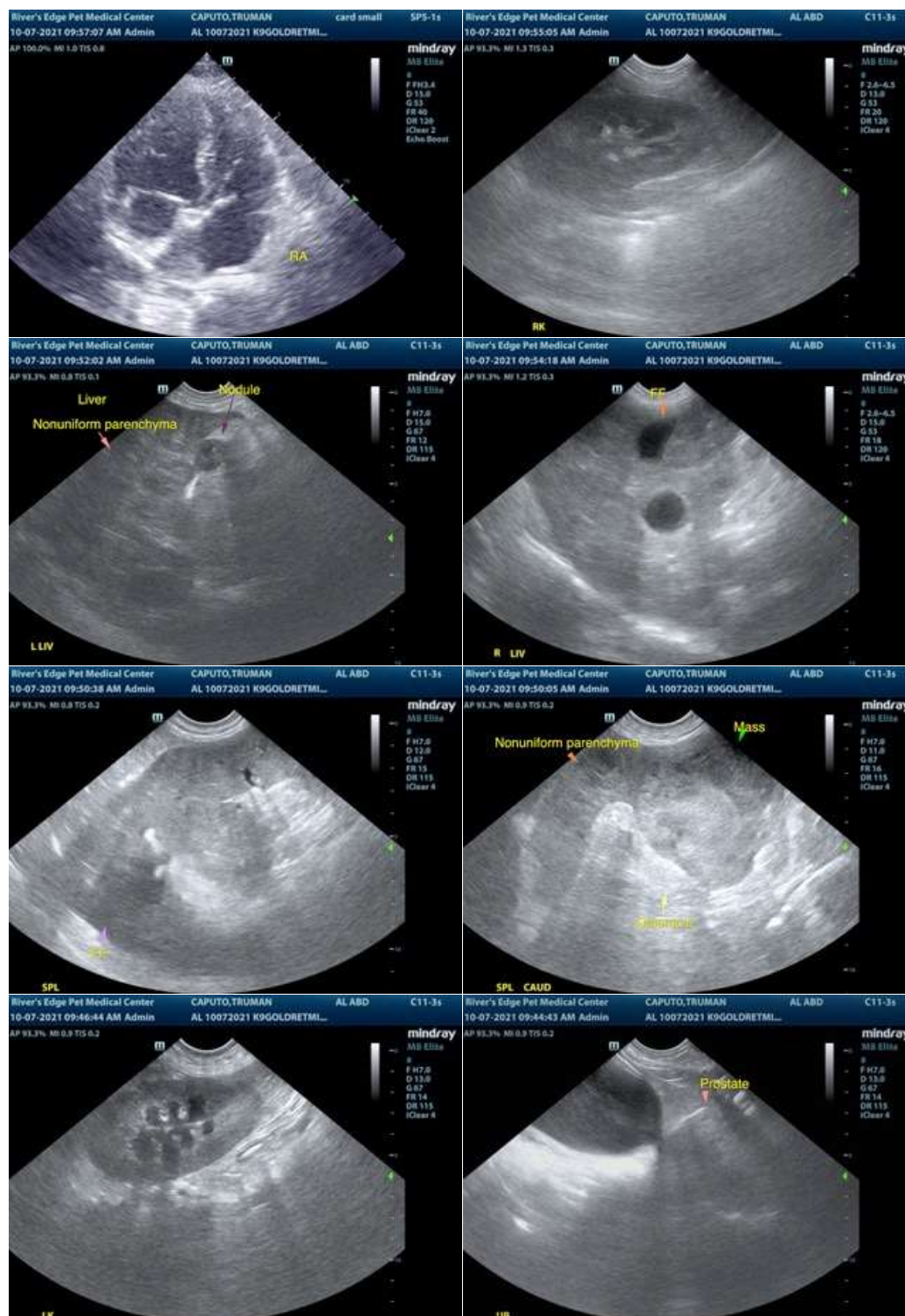
Dr. Cora Hollomon

INVOICE

12384

DATE

10/7/21





PATIENT

Truman Caputo

SPECIES

Canine

BREED

Golden Retriever

SEX

Intact Male

AGE

2008

WEIGHT

103.2

INTERPRETED BY

R. McKenzie Daniel,
DVM, DABVP
(Canine and Feline)

**IMAGING
PERFORMED BY**

Amanda Crook -
SDEP Certified
Clinical Sonographer

HOSPITAL NAME

Rivers Edge PMC

REFERRING VET

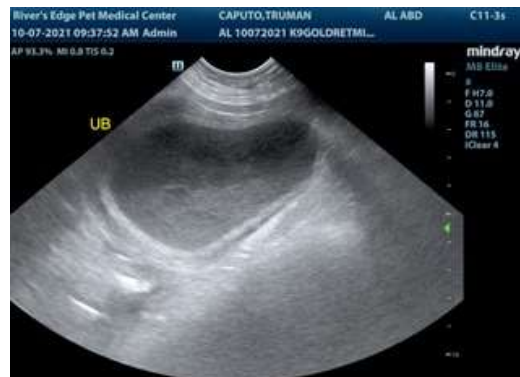
Dr. Cora Hollomon

INVOICE

12384

DATE

10/7/21



The information and recommendations provided are based on the images presented by the referring veterinarian. No evaluation can be communicated regarding pathology that was not visible in the image/video clips provided.

Thank you for this referral. If the clinical or image interpretation does not parallel your findings or if I can be of any further assistance please contact me.

R. McKenzie Daniel, DVM, DABVP (Canine / Feline Practice)
info@SonoPath.com