



PATIENT

Riley Marquardt

SPECIES

Canine

BREED

Tibetan Terrier

SEX

Neutered Male

AGE

11 years

WEIGHT

37 lbs.

INTERPRETED BY

R. McKenzie Daniel,
DVM, DABVP
(Canine and Feline)

IMAGING PERFORMED BY

Kelly Vazquez

HOSPITAL NAME

New Bridge VH

REFERRING VET

Dr. Glennon

INVOICE

12376

DATE

10/7/21

PRESENTING CLINICAL SIGNS

Hepatopathy, possible IMHA/ITP.

Abnormal PE/Chem/CBC/UA Results: RBC 3.92, HCT 27.5%, HGB 8.2, MCH 20.9, reticulocytes 294, reticulocytes hemoglobin 20.9, WBC 19.5, neutrophils 15093, monocytes 2691, platelets 65.

ULTRASONOGRAPHIC EXAMINATION OF THE ABDOMEN

Urinary System

The urinary bladder, trigone, cystourethral junction, and visible pelvic urethra to a depth of 4.0 cm exhibited normal thickness and tone. Anechoic urine was present in the lumen with no uroliths or sediment. The ureteral papillae were normal. The ureters were not visible which is normal. No evidence of inflammatory or neoplastic changes was noted.

The residual prostate was symmetrically normal in size with uniform parenchyma and slight coarse echotexture measuring 0.96 cm in diameter.

The area of the aortic trifurcation was free of pathology.

Normal size was present in the kidneys. Both kidneys exhibited a maintained 1:3 cortex / medulla ratio with marked, primarily uniform increased cortex echogenicity with enhanced corticomedullary border demarcation. A subtle hypoechoic halo was noted around the cortex periphery. No overt evidence of left or right retroperitonitis. The left kidney measured 5.5 cm in length. The right kidney measured 6.3 cm in length.

Adrenal Glands

The left adrenal gland was instinctually visualized. The left adrenal gland measured 0.44 cm width at the caudal pole. The right adrenal gland was uniform in size and contour with a uniformly hypoechoic parenchyma. The right adrenal gland measured 2.3 cm length x 0.51 cm width at the caudal pole.

Spleen

The spleen exhibited overall decreased splenic parenchyma echogenicity with multifocal pinpoint hyperechoic parenchyma foci. The capsule was smooth and regular without apparent expansion. The splenic vasculature at the hilus was normal in volume with no evidence of congestion or thrombosis. The parenchymal heterogeneity is likely consistent with benign changes such as extramedullary hematopoiesis or age-related remodeling with minor potential for inflammatory or neoplastic disease.

Liver/ Gallbladder

The liver exhibited generalized enlargement with nonhomogeneous to subtly nodular parenchyma and moderate coarse echotexture. The gallbladder was non-distended in size with mild gallbladder debris. The cystic and common bile ducts were normal.

Gastrointestinal

The stomach presented intact wall layering with a normal wall layer ratio. The lumen of the stomach contained mild to moderate, retained echogenic fluid, hyperechoic ingesta and chyme. Mild prominent



PATIENT	rugal folds were present, yet intact gastric wall layering was noted. The gastric body wall width measured 0.40 cm.
Riley Marquardt	
SPECIES	The small intestine presented intact wall layering with 1:3 muscularis/mucosa ratio. The lumen of the small intestine was empty with no signs of ileus, obstruction, or foreign material. The duodenum wall width measured 0.32 cm.
Canine	
BREED	Normal visible colon wall layers were present with apparent formed feces in lumen.
Tibetan Terrier	
SEX	Pancreas The pancreas was normal in size and contour with isoechoic to heterogeneous parenchyma compared to adjacent omentum. No signs of active inflammation or neoplasia.
Neutered Male	
AGE	Free Abdomen Several, prominent, nonhomogeneous to cystic hepatic lymph nodes were present. An example measured 3.2 cm x 1.8 cm.
11 years	
WEIGHT	Focal, midabdominal mesenteric lymph node was present. The lymph node was homogenous, mildly hypoechoic, and smoothly margined. A normal width: length ratio was maintained (<0.5). Evidence of perilymphatic inflammation was evident. The lymph node size was 2.5 cm x 1.2cm.
37 lbs.	
INTERPRETED BY	ULTRASONOGRAPHIC FINDINGS
R. McKenzie Daniel, DVM, DABVP (Canine and Feline)	Primary Findings
IMAGING PERFORMED BY	<ul style="list-style-type: none"> • Bilateral marked increased renal cortex echogenicity with subtle hypoechoic halo around cortex periphery - acute to chronic nonspecific nephritis (interstitial nephritis, glomerulonephritis, etc.), neoplasia i.e., lymphoma, toxic Insult i.e., ethylene glycol if clinically applicable, or other • Decreased splenic parenchyma echogenicity with multifocal pinpoint hyperechoic foci - suspect pinpoint areas of microinfarction, fibrosis, or mineralization, potential for splenic neoplasia • Hepatopathy with nonhomogeneous to nodular parenchyma - vacuolar hepatitis, chronic active hepatitis, cholangiohepatitis, fibrosis, with areas of nodular to regenerative hyperplasia, hematopoiesis, or other hepatopathy, potential for hepatic neoplasia is possible • Cystic, hepatic, and focal midabdominal mesenteric lymphadenopathy - chronic lymphoid hyperplasia, lymphadenitis, or neoplastic lymphadenopathy possible
Kelly Vazquez	
HOSPITAL NAME	INTERPRETATION OF THE FINDINGS & FURTHER RECOMMENDATIONS
New Bridge VH	Further renal staging to include urine C/S and protein: creatinine ratio on sterile urine sample may be considered. Assuming normal clotting status, renal cortical FNA, as well as hepatosplenic FNA using a 25-gauge needle, could be considered for screening cytology. Leptospiriosis titer / PCR may be considered if potential exposure. CBC pathology review and assessment for autoagglutination with monitoring of hematocrit and platelet levels are suggested.
REFERRING VET	
Dr. Glennon	
INVOICE	
12376	
DATE	
10/7/21	



PATIENT

Riley Marquardt

SPECIES

Canine

BREED

Tibetan Terrier

SEX

Neutered Male

AGE

11 years

WEIGHT

37 lbs.

INTERPRETED BY

R. McKenzie Daniel,
DVM, DABVP
(Canine and Feline)

IMAGING PERFORMED BY

Kelly Vazquez

HOSPITAL NAME

New Bridge VH

REFERRING VET

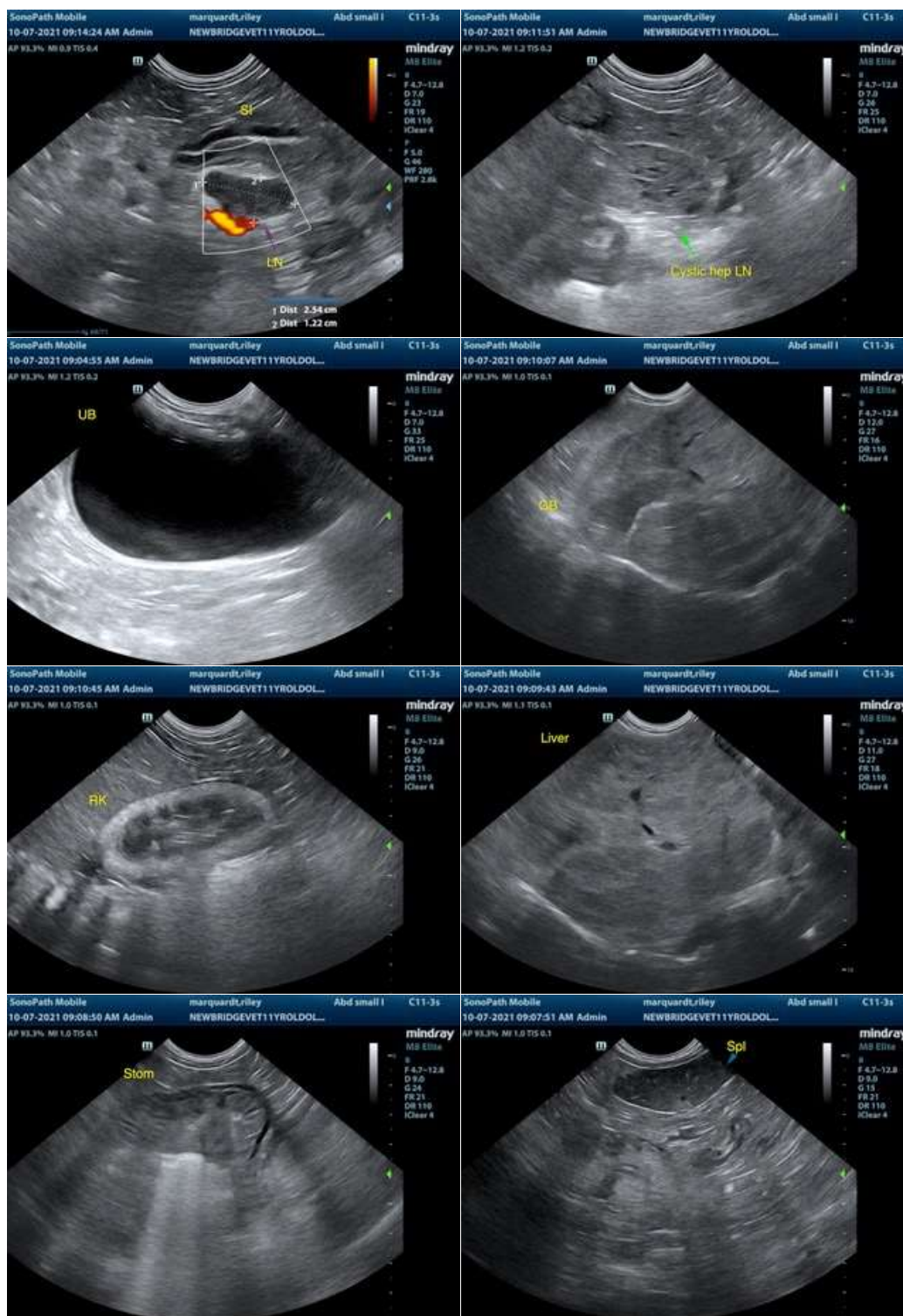
Dr. Glennon

INVOICE

12376

DATE

10/7/21





PATIENT

Riley Marquardt

SPECIES

Canine

BREED

Tibetan Terrier

SEX

Neutered Male

AGE

11 years

WEIGHT

37 lbs.

INTERPRETED BY

R. McKenzie Daniel,
DVM, DABVP
(Canine and Feline)

IMAGING PERFORMED BY

Kelly Vazquez

HOSPITAL NAME

New Bridge VH

REFERRING VET

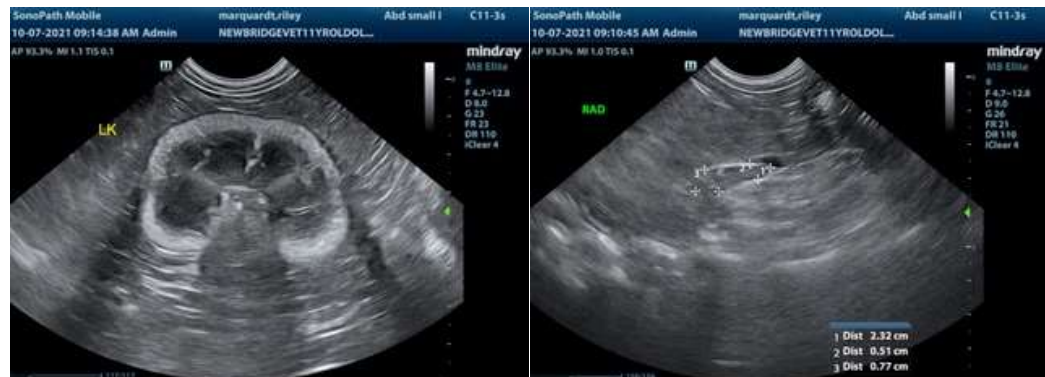Dr. Glennon

INVOICE

12376

DATE

10/7/21



The information and recommendations provided are based on the images presented by the referring veterinarian. No evaluation can be communicated regarding pathology that was not visible in the image/video clips provided.

Thank you for this referral. If the clinical or image interpretation does not parallel your findings or if I can be of any further assistance please contact me.

R. McKenzie Daniel, DVM, DABVP (Canine / Feline Practice)
info@SonoPath.com