



PATIENT

Lucy Clark

SPECIES

Canine

BREED

Terrier Mix

SEX

Spayed Female

AGE

26 weeks

WEIGHT

47.5 lbs.

INTERPRETED BY

R. McKenzie Daniel,
DVM, DABVP
(Canine and Feline)

IMAGING PERFORMED BY

Diane McFadden

HOSPITAL NAME

Wantage VH

REFERRING VET

Dr. Bullock

INVOICE

12383

DATE

10/7/21

PRESENTING CLINICAL SIGNS

spayed 6 weeks ago; spay incision was oozing, became large seroma weeks after surgery.. Suspect sponge/gauze left in abdomen - can see mass effect caudal abdomen. Is on clavamox and carprofen

ULTRASONOGRAPHIC EXAMINATION OF THE ABDOMEN

Urinary System

The urinary bladder, trigone, cystourethral junction, and visible pelvic urethra to a depth of 3.0 cm exhibited normal thickness and tone. Anechoic urine was present in the lumen with no uroliths or sediment. The ureteral papillae were normal. The ureters were not visible which is normal. No evidence of inflammatory or neoplastic changes was noted.

The area of the aortic trifurcation was free of pathology.

Normal size and margination were present in the kidneys. A normal 1:3 cortex / medulla ratio and normal corticomedullary definition were maintained. The echogenicity of the cortex was similar to or slightly less than normal liver parenchyma while the medulla echogenicity was hypoechoic to the cortex with no evidence of pelvic dilation. The left kidney measured 6.3 cm in length. The right kidney measured 6.0 cm in length.

Adrenal Glands

The left adrenal gland was uniform in size and contour with a uniformly hypoechoic parenchyma. The left adrenal gland measured 0.44 cm width at the caudal pole and 0.42 cm width at the cranial pole. The right adrenal gland was uniform in size and contour with a uniformly hypoechoic parenchyma. The right adrenal gland measured 0.44 cm width at the caudal pole and 0.61 cm width at the cranial pole.

Spleen

The spleen exhibited a finely textured and homogenous parenchyma which was hyperechoic to the liver and renal cortical parenchyma. The capsule was smooth and regular without apparent expansion. The splenic vasculature at the hilus was normal in volume with no evidence of congestion or thrombosis. Acute to chronic inflammatory, neoplastic, or benign parenchyma changes were not noted.

Liver/ Gallbladder

The liver was subjectively normal in size, structure, and contour. The liver parenchyma was uniform and hypoechoic to the spleen with a mild coarse echotexture. The hepatic and portal vasculature were normal in appearance without signs of congestion. The gallbladder was non-distended in size with thin walls and primarily anechoic luminal content. The cystic and common bile ducts were normal.

Gastrointestinal

The stomach presented intact wall layering with a normal wall layer ratio. The lumen of the stomach contained echogenic, nonshadowing ingesta most consistent with post prandial presentation without signs of ileus, obstruction or foreign material.



PATIENT

Lucy Clark

SPECIES

Canine

BREED

Terrier Mix

SEX

Spayed Female

AGE

26 weeks

WEIGHT

47.5 lbs.

The small intestine presented intact wall layering with 1:3 muscularis/mucosa ratio. The lumen of the small intestine was empty with no signs of ileus, obstruction, or foreign material.

Normal visible colon wall layers were present with apparent formed feces in lumen.

Pancreas

The parenchyma of the left limb, body, and right limb of the pancreas presented isoechoic to the adjacent omental fat. A normal curvilinear capsule contour of the pancreas was present. The visible pancreatic duct was normal. No signs of active inflammation or neoplastic disease were evident.

Free Abdomen

No evidence of intraabdominal masses, granuloma, abscess, or effusion was present.

No evidence of pathology was noted in the uterine stump.

Several, midabdominal mesenteric lymph nodes were present. The lymph nodes were essentially isoechoic to adjacent omentum without evidence of peripheral inflammation and maintaining a normal width: length ratio (<0.5).

ULTRASONOGRAPHIC FINDINGS

Primary Findings

- Sonographically unremarkable area of uterine stump
- Gastric ingesta - probable post prandial presentation
- Intermittent subjectively benign / reactive mesenteric lymph nodes - likely minor lymphoid hyperplasia or immunologic immaturity

INTERPRETATION OF THE FINDINGS & FURTHER RECOMMENDATIONS

If evidence of vomiting or inappetence, the potential for some degree of metabolic gastric stasis could be considered, yet is though unlikely.

No overt evidence of Intraabdominal pathology suggestive of retained sponge or gauze.

INTERPRETED BY

R. McKenzie Daniel,
DVM, DABVP
(Canine and Feline)

IMAGING PERFORMED BY

Diane McFadden

HOSPITAL NAME

Wantage VH

REFERRING VET

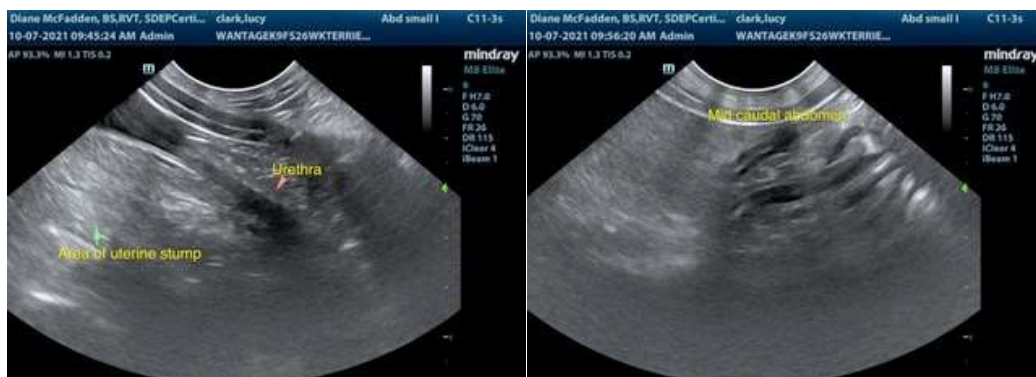Dr. Bullock

INVOICE

12383

DATE

10/7/21





PATIENT

Lucy Clark

SPECIES

Canine

BREED

Terrier Mix

SEX

Spayed Female

AGE

26 weeks

WEIGHT

47.5 lbs.

INTERPRETED BY

R. McKenzie Daniel,
DVM, DABVP
(Canine and Feline)

IMAGING PERFORMED BY

Diane McFadden

HOSPITAL NAME

Wantage VH

REFERRING VET

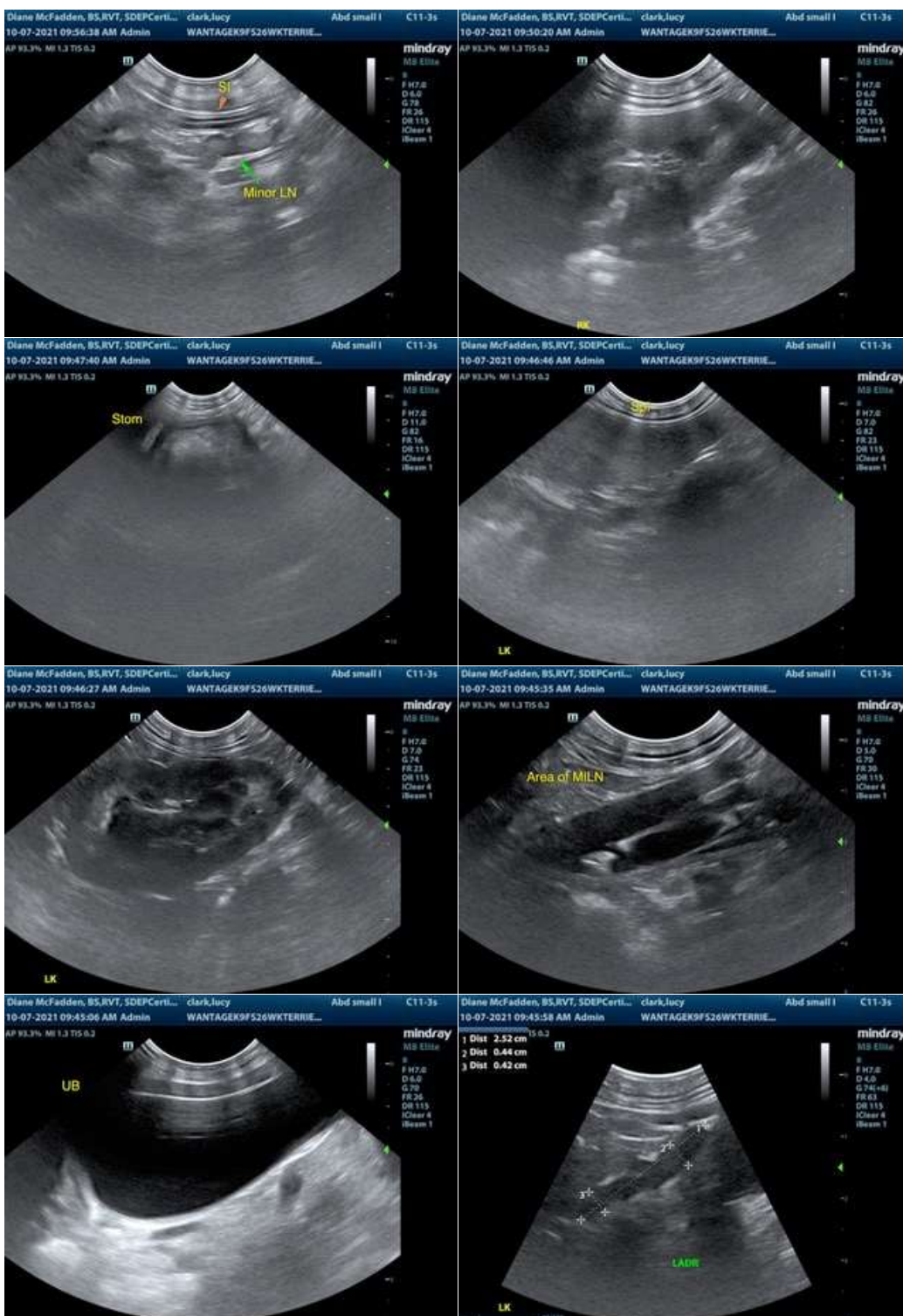
Dr. Bullock

INVOICE

12383

DATE

10/7/21



The information and recommendations provided are based on the images presented by the referring veterinarian. No evaluation can be communicated regarding pathology that was not visible in the image/video clips provided.



PATIENT

Lucy Clark

Thank you for this referral. If the clinical or image interpretation does not parallel your findings or if I can be of any further assistance please contact me.

SPECIES

Canine

R. McKenzie Daniel, DVM, DABVP (Canine / Feline Practice)
info@SonoPath.com

BREED

Terrier Mix

SEX

Spayed Female

AGE

26 weeks

WEIGHT

47.5 lbs.

INTERPRETED BY

R. McKenzie Daniel,
DVM, DABVP
(Canine and Feline)

**IMAGING
PERFORMED BY**

Diane McFadden

HOSPITAL NAME

Wantage VH

REFERRING VET

Dr. Bullock

INVOICE

12383

DATE

10/7/21