



PATIENT	PRESENTING CLINICAL SIGNS
Grayson Jenkins	-ADR x 1 month; hyporexia, elevated renal values. indoor /outdoor. wt loss last month 8.1 to 7.6#. not on any meds. slight improvement with baytril in Sept
SPECIES	Abnormal PE/Chem/CBC/UA Results: 9/2/21: HCT 27%, sl decrease ALT and ALKP, glob incr 5.6, BUN 13 (16 low)
Feline	
BREED	ULTRASONOGRAPHIC EXAMINATION OF THE ABDOMEN
DSH	Urinary System
SEX	The urinary bladder, trigone, cystourethral junction, and visible pelvic urethra to a depth of 2.0 cm exhibited normal thickness and tone. Anechoic urine was present in the lumen with no uroliths or sediment. The ureteral papillae were normal. The ureters were not visible which is normal. No evidence of inflammatory or neoplastic changes was noted.
Neutered Male	
AGE	The area of the aortic trifurcation was free of pathology.
9.5 years	
WEIGHT	The bilateral kidneys were enlarged in size with nonuniform increased corticomedullary echogenicity and indistinct hyperechoic corticomedullary striations. Asymmetrical renal margination was present in both kidneys. The increased corticomedullary echogenicity was most notable in the right kidney. The left kidney measured 5.4 cm in length. The right kidney measured 6.4 cm in length.
7.6 lbs	
INTERPRETED BY	Adrenal Glands
R. McKenzie Daniel, DVM, DABVP (Canine and Feline)	The bilateral adrenal glands were not definitively visualized owing to omental artifact and free fluid.
IMAGING PERFORMED BY	Spleen
Diane McFadden	The spleen exhibited a finely textured and homogenous parenchyma which was hyperechoic to the liver and renal cortical parenchyma. The capsule was smooth and regular without apparent expansion. The splenic vasculature at the hilus was normal in volume with no evidence of congestion or thrombosis. Acute to chronic inflammatory, neoplastic, or benign parenchyma changes were not noted.
HOSPITAL NAME	Liver/ Gallbladder
Wantage VH	The discernable mid to deep liver exhibited uniform echogenicity with mild coarse echotexture and subjective normal parenchyma echogenicity. The gallbladder was non-distended in size with mild gallbladder debris. The cystic and common bile ducts were normal.
REFERRING VET	Gastrointestinal
Dr. Bullock	The stomach presented intact wall layering with a normal wall layer ratio. The lumen of the stomach contained moderate, echogenic ingesta with progressive distal acoustic shadowing.
INVOICE	The small intestine presented intact wall layering with 1:3 muscularis/mucosa ratio. The lumen of the small intestine was empty with no signs of ileus, obstruction, or foreign material.
12381	
DATE	Normal visible colon wall layers were present with apparent formed feces in lumen.
10/7/21	



PATIENT

Pancreas

Grayson Jenkins

The discernable pancreas was not visualized owing to regional cranial abdominal omental pathology, Increased omental artifact, and peritoneal free fluid.

SPECIES

Feline

Free Abdomen

BREED

DSH

A moderately sized, asymmetrically margined, nonhomogeneous mass was present, occupying the majority of the cranial abdomen directly effacing or potentially originating from the liver, pancreas, as well as extending caudolaterally to the level and potentially surrounding the bilateral kidneys. This mass measured approximately 4.0 cm - 5.0 cm in diameter, but potentially larger.

SEX

Neutered Male

Nonuniform to nodular omentum with potential for mesenteric lymphadenopathy was present.

ULTRASONOGRAPHIC FINDINGS

AGE

9.5 years

Primary Findings

WEIGHT

7.6 lbs

- Bilateral renomegaly with hyperechoic corticomedullary echogenicity and corticomedullary striations
- Unspecified asymmetrical to nonhomogeneous cranial mass lesion
- Generalized nonuniform to nodular omentum and probable concurrent lymphadenopathy
- Moderate subjectively cellular peritoneal free fluid

INTERPRETED BY

R. McKenzie Daniel,
DVM, DABVP
(Canine and Feline)

INTERPRETATION OF THE FINDINGS & FURTHER RECOMMENDATIONS

Unfortunately, the findings in this study are consistent with multicentric neoplasia, given the presence of the unspecified cranial abdominal mass, as well as presentation of the bilateral kidneys, omentum, and likely concurrent lymphadenopathy. The effusion in this case may be secondary to carcinomatosis, lymphomatosis, or similar with potential for lymphatic obstruction.

Further assessment may include effusion analysis, cytology, +/- C/S if evidence of inflammatory cells. Technically FIP is a potential in this case yet is considered unlikely given the patient's age. Unfortunately, an unfavorable to poor prognosis is indicated.

IMAGING PERFORMED BY

Diane McFadden

HOSPITAL NAME

Wantage VH

REFERRING VET

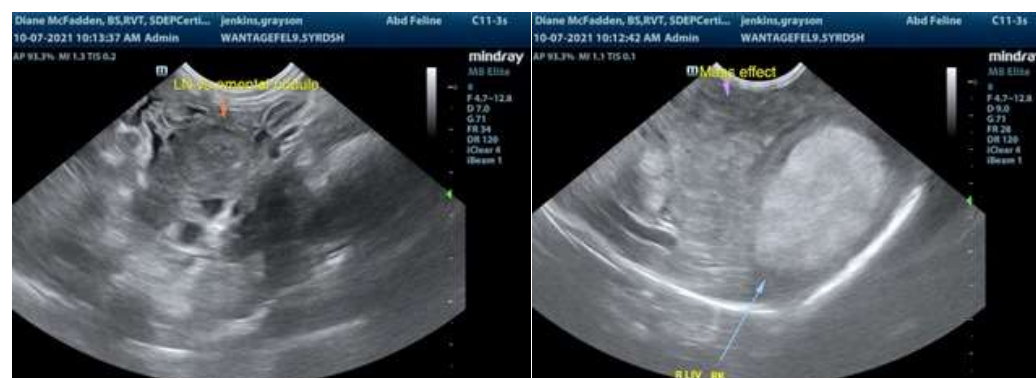
Dr. Bullock

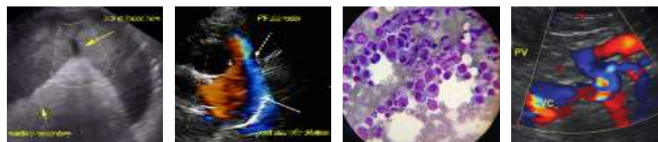
INVOICE

12381

DATE

10/7/21





PATIENT

Grayson Jenkins

SPECIES

Feline

BREED

DSH

SEX

Neutered Male

AGE

9.5 years

WEIGHT

7.6 lbs

INTERPRETED BY

R. McKenzie Daniel,
DVM, DABVP
(Canine and Feline)

IMAGING PERFORMED BY

Diane McFadden

HOSPITAL NAME

Wantage VH

REFERRING VET

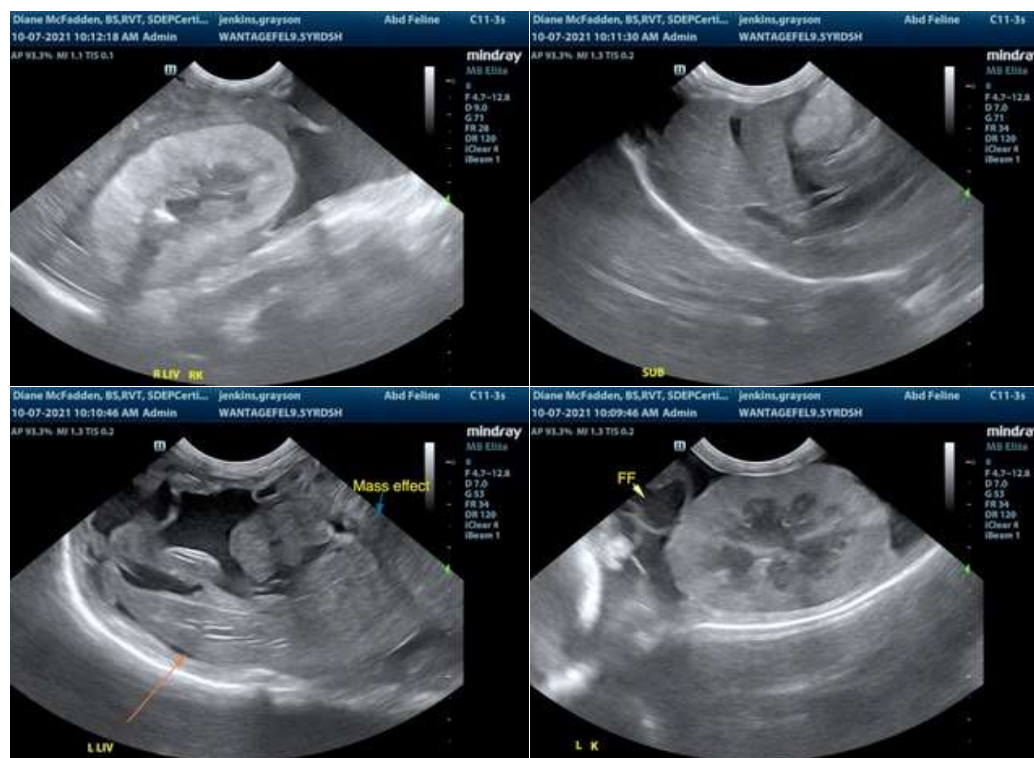
Dr. Bullock

INVOICE

12381

DATE

10/7/21



The information and recommendations provided are based on the images presented by the referring veterinarian. No evaluation can be communicated regarding pathology that was not visible in the image/video clips provided.

Thank you for this referral. If the clinical or image interpretation does not parallel your findings or if I can be of any further assistance please contact me.

R. McKenzie Daniel, DVM, DABVP (Canine / Feline Practice)
info@SonoPath.com