



PATIENT PRESENTING CLINICAL SIGNS

Bennie Toyne Repeat ultrasound from yesterday for suspected FB. Confirmed has been fasted today. Vomited twice over the last 24 hours.

SPECIES ULTRASONOGRAPHIC EXAMINATION OF THE ABDOMEN

Canine **Urinary System**

BREED The urinary bladder, trigone, cystourethral junction, and visible pelvic urethra to a depth of – cm exhibited normal thickness and tone. Anechoic urine was present in the lumen with no uroliths or sediment. The ureteral papillae were normal. The ureters were not visible which is normal. No evidence of inflammatory or neoplastic changes were noted.

Mini Doodle

SEX Normal size and margination were present in the kidneys. A normal 1:3 cortex / medulla ratio and normal corticomedullary definition were maintained. The echogenicity of the cortex was similar to or slightly less than normal liver parenchyma while the medulla echogenicity was hypoechoic to the cortex with no evidence of pelvic dilation. The left kidney measured 5.0 cm. The right kidney measured 5.0 cm.

Neutered Male

AGE **Adrenal Glands**

1 Year The adrenal glands were uniform in size and contour with a uniformly hypoechoic parenchyma. The left adrenal gland measured 0.43 cm at the cranial pole and 0.37 cm at the caudal pole. The right adrenal gland measured 0.55 cm at the cranial pole and 0.59 cm at the caudal pole.

WEIGHT **Spleen**

26 Pounds The spleen exhibited a finely textured and homogenous parenchyma which was hyperechoic to the liver and renal cortical parenchyma. The capsule was smooth and regular without apparent expansion. The splenic vasculature at the hilus was normal in volume with no evidence of congestion or thrombosis. Acute to chronic inflammatory, neoplastic, or benign parenchyma changes were not noted.

INTERPRETED BY

R. McKenzie Daniel, DVM,
DABVP (Canine and
Feline)

IMAGING PERFORMED BY

Crystal Hill

HOSPITAL NAME

Dog & Cat Clinic of
Niagara

REFERRING VET

Dr. Habib

INVOICE

26127

DATE

10/7/21

Liver

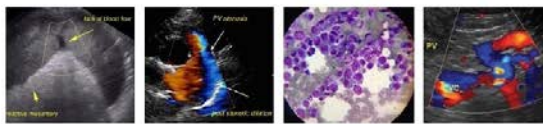
The liver was subjectively normal in size, structure, and contour. The liver parenchyma was uniform and hypoechoic to the spleen with a mild coarse echotexture. The hepatic and portal vasculature were normal in appearance without signs of congestion. The gallbladder was non-distended in size with thin walls and primarily anechoic luminal content. The cystic and common bile ducts were normal.

Gastrointestinal

The stomach exhibited decreased size owing to gastric emptying since previous ultrasound. The stomach was primarily empty with luminal gas causing areas of distal reverberation artifact. Potential for an indistinct ovoid, mildly shadowing echo measuring approximately 2.0 cm in diameter was noted focally within the gastric body. A mild amount of retained, subtly shadowing chyme was present within the gastric antrum and pylorus. No evidence of mechanical pyloric outflow obstruction. Gastric body wall measured 0.38 cm.

The small intestine presented intact wall layering with 1:3 muscularis/mucosa ratio. The lumen of the small intestine was empty with no signs of ileus, obstruction or foreign material. Duodenum wall measured 0.40 cm.

Normal visible colon wall layers were present with strongly shadowing fecal matter.



PATIENT *Pancreas*

Bennie Toyne

The parenchyma of the left limb, body and right limb of the pancreas presented isoechoic to the adjacent omental fat. A normal curvilinear capsule contour of the pancreas was present. The visible pancreatic duct was normal. No signs of active inflammation or neoplastic disease was evident.

SPECIES

Canine

ULTRASONOGRAPHIC FINDINGS

- Decreased gastric volume with persistent yet mild retained pyloric chyme and luminal gas
- Possible yet not definitive persistent, mildly shadowing gastric echo
- Sonographically unremarkable small bowel
- Strongly shadowing fecal matter in the colon

BREED

Mini Doodle

SEX

Neutered Male

INTERPRETATION OF THE FINDINGS & FURTHER RECOMMENDATIONS

Unfortunately, the gastric presentation at this time was not definitively evident as to the presence or absence of gastric foreign material. This may be somewhat owing to decreased gastric luminal visualization owing to the presence of gas reverberation artifact. Some degree of suspicion as to retained potential cloth, fabric or hair within the stomach is warranted, although not definitive. Gastric emptying appears to be normal given the decreased gastric volume compared to the previous study. However, the shadowing echoes present in the previous study were not as evident at this time. Passage of the echoes into the colon may be possible. Therefore, monitoring fecal output is suggested. Ideally, correlation with recheck abdominal radiographs to assess for soft tissue opacity persistent within the gastric lumen recommended. If strong clinical concern for retained gastric foreign material, endoscopy would be ideal. Alternatively, a barium study could be considered at this time to assess for retained barium in the stomach.

AGE

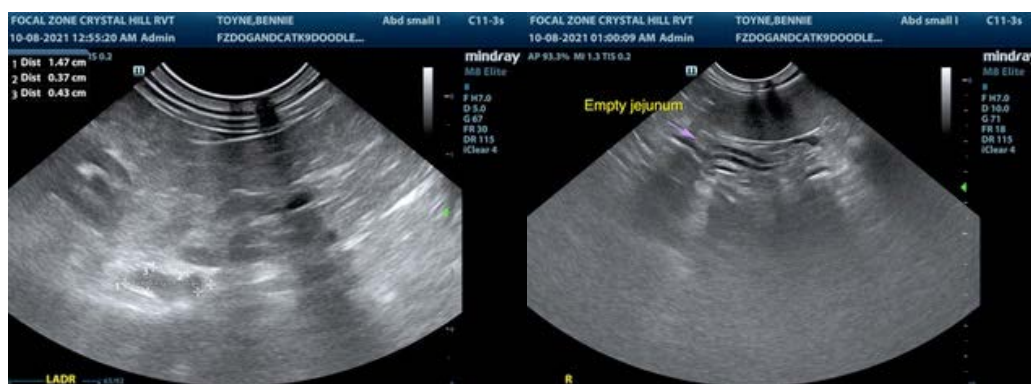
1 Year

WEIGHT

26 Pounds

INTERPRETED BY

R. McKenzie Daniel, DVM,
DABVP (Canine and
Feline)



IMAGING PERFORMED BY

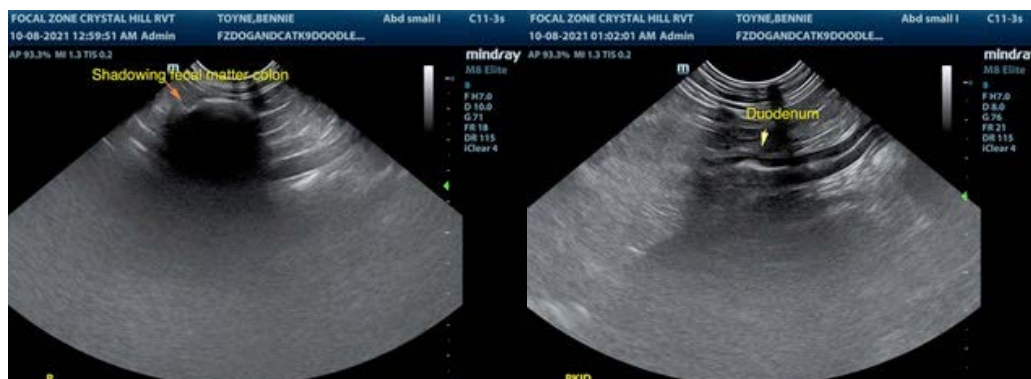Crystal Hill

HOSPITAL NAME

Dog & Cat Clinic of
Niagara

REFERRING VET

Dr. Habib

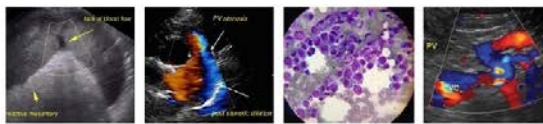


INVOICE

26127

DATE

10/7/21



PATIENT

Bennie Toyne

SPECIES

Canine

BREED

Mini Doodle

SEX

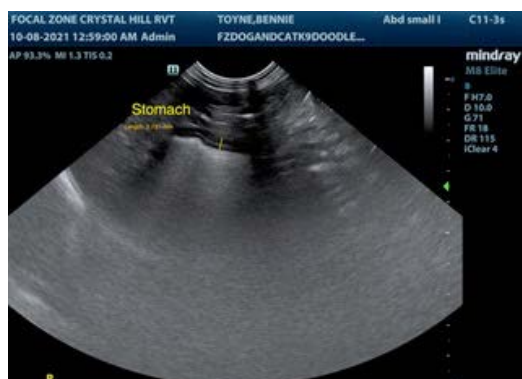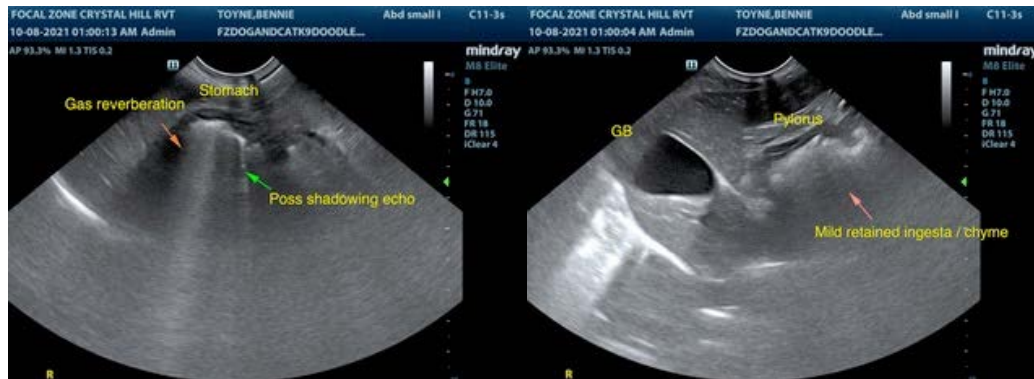
Neutered Male

AGE

1 Year

WEIGHT

26 Pounds



INTERPRETED BY

R. McKenzie Daniel, DVM,
DABVP (Canine and
Feline)

**IMAGING
PERFORMED BY**

Crystal Hill

HOSPITAL NAME

Dog & Cat Clinic of
Niagara

REFERRING VET

Dr. Habib

INVOICE

26127

DATE

10/7/21

The information and recommendations provided are based on the images presented by the referring veterinarian. No evaluation can be communicated regarding pathology that was not visible in the image/video clips provided.

Thank you for this referral. If the clinical or image interpretation does not parallel your findings or if I can be of any further assistance please contact me.

R. McKenzie Daniel, DVM, DABVP (Canine / Feline Practice)
info@SonoPath.com