



PATIENT

Poppy Makos

SPECIES

Feline

BREED

DSH

SEX

FS

AGE

15 months

WEIGHT

11 lbs.

INTERPRETED BY

R. McKenzie Daniel,
DVM, DABVP
(Canine and Feline)

IMAGING PERFORMED BY

Kelly Vazquez

HOSPITAL NAME

Marsh Hospital for
Animals

REFERRING VET

Dr. Milwicki

INVOICE

15105

DATE

10/6/22

PRESENTING CLINICAL SIGNS

Recent diagnosis of cutaneous lymphocytosis. (Ulcerated epidermal mass, left hind leg just distal to the hock laterally.) No current meds.

ULTRASONOGRAPHIC EXAMINATION OF THE HEART & ABDOMEN

FELINE CARDIAC PARAMETERS	BODY WEIGHT (kg)	HR (BPM)	IVSd (cm)	LVIDd (cm)	LVWd (cm)	FS (%)	EF (%)
NORMAL PARAMETER	-----	150-240	0.3-0.6	1.0-2.1	0.25-0.6	35-67	80-100
PATIENT		142	0.45	1.6	0.45	54.6	88
FELINE CARDIAC PARAMETERS	LA/AO (Boon)	LA/AO HEART BASE (Sisson)	LA 2D 4-chamber long axis AS to FW (Sisson) (cm)	LVOT VEL. (m/s)	RVOT VEL. (m/s)	IVRT (m)	
NORMAL PARAMETER	<1.5	0.88-1.79	0.7-1.7	<1.6	<1.3	40-60	
PATIENT		1.1	1.2	1.1	1.1	NM	
Adapted from June Boon, Veterinary Echocardiography, 1998 Sisson D et al. JVIM 1991; 5: 232, Jacobs et al. Am J Vet Res 1985; 46:1705							

Cardiac Presentation

The echocardiogram in this patient demonstrated normal **left atrial** size based on 3 separate LA measurements. The cranial and caudal **mitral** valve leaflets presented normal linear structure and kinetics. The **left ventricle** presented normal thicknesses with linear contour and was not dilated nor restricted. The **myocardium** presented normal echogenicity without subjective evidence of significant fibrotic or ischemic disease. **Contractility** of the ventricular walls was adequate and in normal range for this patient evidenced by the fractional shortening measurement and subjective evaluation of the different regions and angles of the myocardium. The **left ventricular outflow** tract demonstrated normal laminar flow and subjective structural integrity. The **right atrium** and auricle revealed normal size, structure and content. No evidence of masses was noted or chamber overload. **Tricuspid** valvular assessment demonstrated adequate linear morphology and kinetics. The **right ventricle** was of normal size (1/3 diameter of LV), chordae structure, myocardial echogenicity and thickness. **Pulmonic** tract assessment revealed normal valve structure, laminar flow, and diameter (approx. 1:1 pa/ao ratio). No visible **pericardial** or free pleura fluid was noted or extra cardiac pathology in the visible planes. The cranial **mediastinum and pericardial regions** were free of masses in the visible window.

Urinary System

The urinary bladder, trigone, and cystourethral junction exhibited normal thickness and tone. Anechoic urine was present in the lumen with no uroliths or sediment. The ureteral papillae were normal. The ureters were not visible which is normal. No evidence of inflammatory or neoplastic changes was noted.



PATIENT

The area of the aortic trifurcation was free of pathology.

Poppy Makos

SPECIES

Feline

BREED

DSH

SEX

FS

AGE

15 months

WEIGHT

11 lbs.

Normal size and margination were present in the kidneys. A normal 1:3 cortex / medulla ratio and normal corticomedullary definition were maintained. The echogenicity of the cortex was similar to or slightly less than normal liver parenchyma while the medulla echogenicity was hypoechoic to the cortex with no evidence of pelvic dilation. The left kidney measured 3.6 cm in length. The right kidney measured 3.6 cm in length.

Adrenal Glands

The left adrenal gland was uniform in size and contour with a uniformly hypoechoic parenchyma. The left adrenal gland measured 0.35 cm width. The right adrenal gland was uniform in size and contour with a uniformly hypoechoic parenchyma. The right adrenal gland measured 0.46 cm width.

Spleen

The spleen exhibited a finely textured and homogenous parenchyma which was hyperechoic to the liver and renal cortical parenchyma. The capsule was smooth and regular without apparent expansion. The splenic vasculature at the hilus was normal in volume with no evidence of congestion or thrombosis. Acute to chronic inflammatory, neoplastic, or benign parenchyma changes were not noted.

Liver/ Gallbladder

The liver was subjectively normal in size, structure, and contour. The liver parenchyma was uniform and hypoechoic to the spleen with a mild coarse echotexture. The hepatic and portal vasculature were normal in appearance without signs of congestion. The gallbladder was non-distended in size with thin walls and primarily anechoic luminal content. The cystic and common bile ducts were normal.

INTERPRETED BY

R. McKenzie Daniel,
DVM, DABVP
(Canine and Feline)

Gastrointestinal

IMAGING PERFORMED BY

Kelly Vazquez

The stomach presented intact wall layering with a normal wall layer ratio. The lumen of the stomach was empty with no signs of ileus, obstruction, or foreign material.

The small intestine presented intact wall layering with 1:3 muscularis/mucosa ratio. The lumen of the small intestine was empty with no signs of ileus, obstruction, or foreign material.

Normal visible colon wall layers were present with apparent formed feces in lumen.

HOSPITAL NAME

Marsh Hospital for
Animals

REFERRING VET

Dr. Milwicki

Pancreas

The parenchyma of the left limb, body, and right limb of the pancreas presented isoechoic to the adjacent omental fat. A normal curvilinear capsule contour of the pancreas was present. The visible pancreatic duct was normal. No signs of active inflammation or neoplastic disease were evident.

INVOICE

15105

Free Abdomen

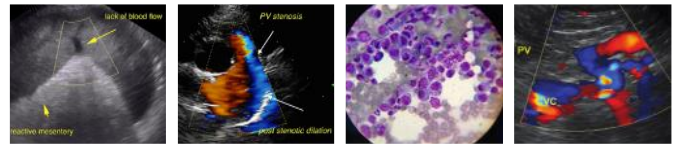
DATE

10/6/22

No overt lymphadenopathy or peritoneal effusion was present.

ULTRASONOGRAPHIC FINDINGS

- Normal echocardiogram
- Sonographically unremarkable abdomen



PATIENT

Poppy Makos

INTERPRETATION OF THE FINDINGS & FURTHER RECOMMENDATIONS

No evidence of cardiac or abdominal visceral pathology.

SPECIES

Feline

BREED

DSH

SEX

FS

AGE

15 months

WEIGHT

11 lbs.

INTERPRETED BY

R. McKenzie Daniel,
DVM, DABVP
(Canine and Feline)

IMAGING PERFORMED BY

Kelly Vazquez

HOSPITAL NAME

Marsh Hospital for
Animals

REFERRING VET

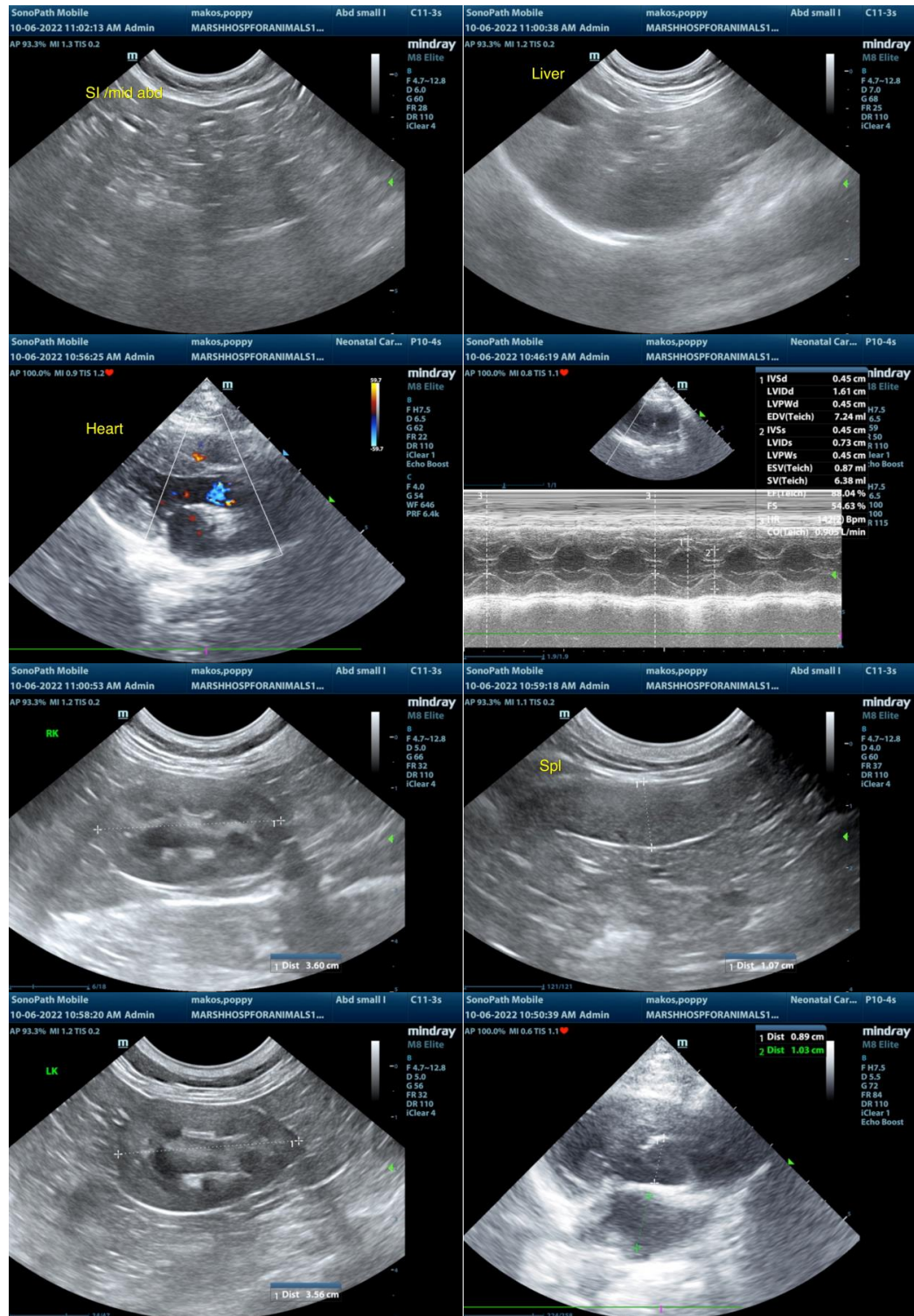
Dr. Milwicki

INVOICE

15105

DATE

10/6/22





PATIENT

Poppy Makos

The information and recommendations provided are based on the images presented by the referring veterinarian/sonographer. No evaluation can be communicated regarding pathology that was not visible in the image/video clips provided.

SPECIES

Feline

Thank you for this referral. If the clinical or image interpretation does not parallel your findings or if I can be of any further assistance please contact me.

BREED

DSH

R. McKenzie Daniel, DVM, DABVP (Canine / Feline Practice)
info@SonoPath.com

SEX

FS

AGE

15 months

WEIGHT

11 lbs.

INTERPRETED BY

R. McKenzie Daniel,
DVM, DABVP
(Canine and Feline)

**IMAGING
PERFORMED BY**

Kelly Vazquez

HOSPITAL NAME

Marsh Hospital for
Animals

REFERRING VET

Dr. Milwicki

INVOICE

15105

DATE

10/6/22