



PATIENT PRESENTING CLINICAL SIGNS

Stryker Gardiner
Employee Pet

healthy, scan requested as a baseline

SPECIES ULTRASONOGRAPHIC EXAMINATION OF THE ABDOMEN

Canine Urinary System

The urinary bladder, trigone, cystourethral junction, and visible pelvic urethra to a depth of 5.0 cm exhibited normal thickness and tone. Anechoic urine was present in the lumen with no uroliths or sediment. The ureteral papillae were normal. The ureters were not visible which is normal. No evidence of inflammatory or neoplastic changes were noted.

BREED

Bouvier

The residual prostate was sonographically unremarkable.

SEX

Neutered Male

Normal size and margination were present in the kidneys. A normal 1:3 cortex / medulla ratio and normal corticomedullary definition were maintained. The echogenicity of the cortex was similar to or slightly less than normal liver parenchyma while the medulla echogenicity was hypoechoic to the cortex with no evidence of pelvic dilation. The left kidney measured 6.1 cm. The right kidney measured 6.8 cm.

AGE

6 Years

The area of the aortic trifurcation was free of pathology.

WEIGHT

37 kg

The adrenal glands were uniform in size and contour with a uniformly hypoechoic parenchyma. The left adrenal gland measured 2.7 cm length x 0.68 cm at the cranial pole and 0.62 cm at the caudal pole. The right adrenal gland measured 2.3 cm length x 0.56 cm in width.

Adrenal Glands

Spleen

INTERPRETED BY

R. McKenzie Daniel, DVM,
DABVP (Canine and Feline)

The spleen exhibited a finely textured and homogenous parenchyma which was hyperechoic to the liver and renal cortical parenchyma. The capsule was smooth and regular without apparent expansion. The splenic vasculature at the hilus was normal in volume with no evidence of congestion or thrombosis. Acute to chronic inflammatory, neoplastic, or benign parenchyma changes were not noted.

IMAGING PERFORMED BY

Kelly Reschny

Liver

The liver was subjectively normal in size, structure, and contour. The liver parenchyma was uniform and hypoechoic to the spleen with a mild coarse echotexture. The hepatic and portal vasculature were normal in appearance without signs of congestion. The gallbladder was non-distended in size with thin walls and primarily anechoic luminal content. The cystic and common bile ducts were normal.

HOSPITAL NAME

Simcoe Animal Hospital

Gastrointestinal

The stomach presented intact wall layering with a normal wall layer ratio. The lumen of the stomach was empty with no signs of ileus, obstruction or foreign material.

REFERRING VET

Dr. Gardiner

The small intestine presented intact wall layering with 1:3 muscularis/mucosa ratio. The lumen of the small intestine was empty with no signs of ileus, obstruction or foreign material.

INVOICE

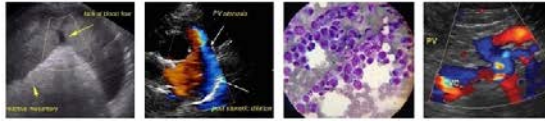
26098

Pancreas

The parenchyma of the left limb, body and right limb of the pancreas presented isoechoic to the adjacent omental fat. A normal curvilinear capsule contour of the pancreas was present. The visible pancreatic duct was normal. No signs of active inflammation or neoplastic disease was evident.

DATE

10/6/21



PATIENT

Stryker Gardiner
Employee Pet

SPECIES

Canine

BREED

Bouvier

SEX

Neutered Male

AGE

6 Years

WEIGHT

37 kg

INTERPRETED BY

R. McKenzie Daniel, DVM,
DABVP (Canine and
Feline)

**IMAGING
PERFORMED BY**

Kelly Reschny

HOSPITAL NAME

Simcoe Animal Hospital

REFERRING VET

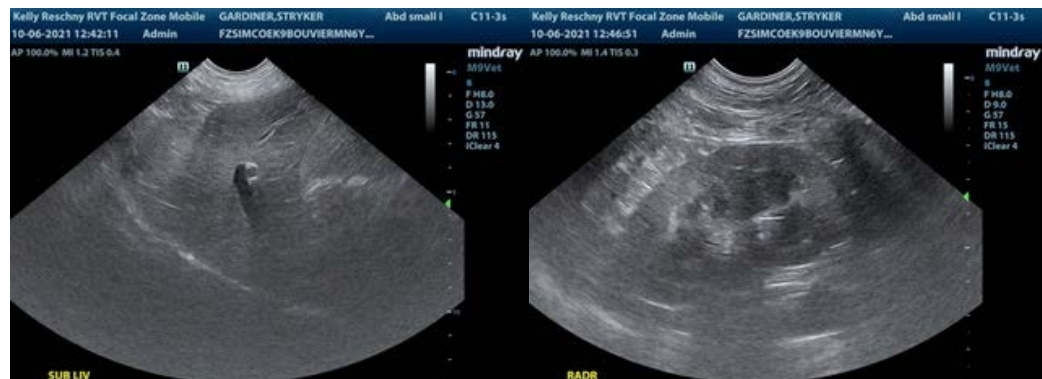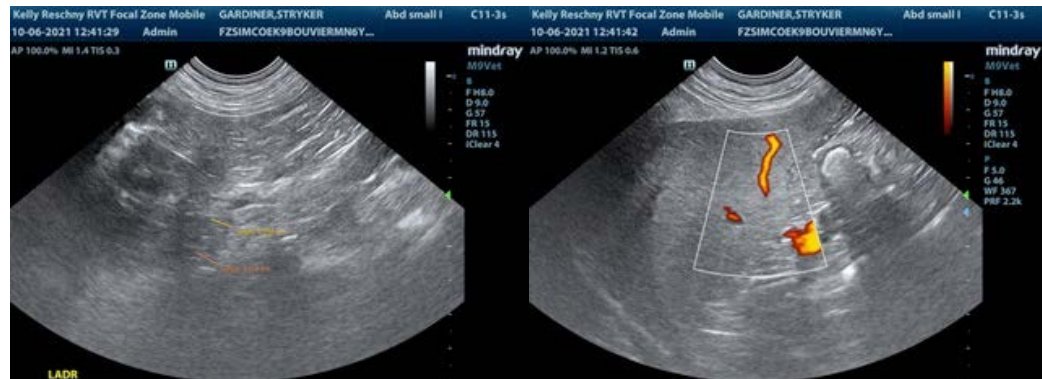
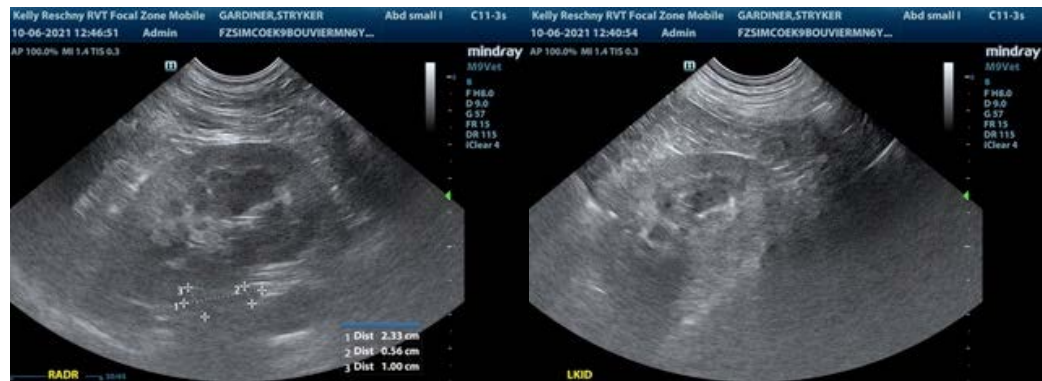
Dr. Gardiner

ULTRASONOGRAPHIC FINDINGS

- Sonographically unremarkable abdomen

INTERPRETATION OF THE FINDINGS & FURTHER RECOMMENDATIONS

No evidence of visceral pathology.

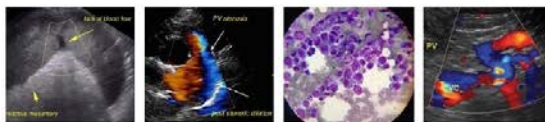


INVOICE

26098

DATE

10/6/21



PATIENT

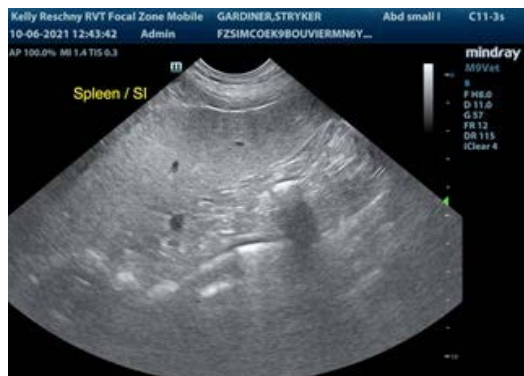Stryker Gardiner
Employee Pet

SPECIES

Canine

BREED

Bouvier



SEX

Neutered Male

The information and recommendations provided are based on the images presented by the referring veterinarian. No evaluation can be communicated regarding pathology that was not visible in the image/video clips provided.

AGE

6 Years

Thank you for this referral. If the clinical or image interpretation does not parallel your findings or if I can be of any further assistance please contact me.

WEIGHT

37 kg

R. McKenzie Daniel, DVM, DABVP (Canine / Feline Practice)
info@SonoPath.com

INTERPRETED BY

R. McKenzie Daniel, DVM,
DABVP (Canine and
Feline)

**IMAGING
PERFORMED BY**

Kelly Reschny

HOSPITAL NAME

Simcoe Animal Hospital

REFERRING VET

Dr. Gardiner

INVOICE

26098

DATE

10/6/21