



PATIENT

Alex Apariaco

SPECIES

Feline

BREED

DSH

SEX

Neutered Male

AGE

1 year

WEIGHT

9 lbs.

INTERPRETED BY

R. McKenzie Daniel,
DVM, DABVP
(Canine and Feline)

IMAGING PERFORMED BY

Dr. Gromalak

HOSPITAL NAME

SVS Imaging

REFERRING VET

Dr. Preiser

INVOICE

12380

DATE

10/6/21

PRESENTING CLINICAL SIGNS

Grade 2/3-6 heart murmur, coughing episodes

ULTRASONOGRAPHIC EXAMINATION OF THE HEART

FELINE CARDIAC PARAMETERS	BODY WEIGHT (kg)	HR (BPM)	IVSd (cm)	LVIDd (cm)	LVWd (cm)	FS (%)	EF (%)
NORMAL PARAMETER	-----	150-240	0.3-0.6	1.0-2.1	0.25-0.6	35-67	80-100
PATIENT		193	0.36	1.6	0.48	55.6	98.3
FELINE CARDIAC PARAMETERS	LA/AO (Boon)	LA/AO HEART BASE (Sisson)	LA 2D 4-chamber long axis AS to FW (Sisson) (cm)	LVOT VEL. (m/s)	RVOT VEL. (m/s)	IVRT (m/)	
NORMAL PARAMETER	<1.5	0.88-1.79	0.7-1.7	<1.6	<1.3	40-60	
PATIENT	1.25	1.22	1.3	1.1	1.0	NM	
Adapted from June Boon, Veterinary Echocardiography, 1998 Sisson D et al. JVIM 1991; 5: 232, Jacobs et al. Am J Vet Res 1985; 46:1705							

Cardiac Presentation

The echocardiogram in this patient demonstrated normal **left atrial** size based on 3 separate LA measurements. The cranial and caudal **mitral** valve leaflets presented normal linear structure and kinetics. The **left ventricle** presented normal thicknesses with linear contour and was not dilated nor restricted. The **myocardium** presented normal echogenicity without subjective evidence of significant fibrotic or ischemic disease. **Contractility** of the ventricular walls was adequate and in normal range for this patient evidenced by the fractional shortening measurement and subjective evaluation of the different regions and angles of the myocardium. The **left ventricular outflow** tract demonstrated normal laminar flow and subjective structural integrity. The **right atrium** and auricle revealed normal size, structure and content. No evidence of masses was noted or chamber overload. **Tricuspid** valvular assessment demonstrated adequate linear morphology and kinetics. The **right ventricle** was of normal size (1/3 diameter of LV), chordae structure, myocardial echogenicity and thickness. **Pulmonic** tract assessment revealed normal valve structure, laminar flow, and diameter (approx. 1:1 pa/ao ratio). No visible **pericardial** or free pleura fluid was noted or extra cardiac pathology in the visible planes. The cranial **mediastinum and pericardial regions** were free of masses in the visible window.

ULTRASONOGRAPHIC FINDINGS

Primary Findings

- Overtly normal cardiac structure and function



PATIENT

Alex Apariaco

SPECIES

Feline

BREED

DSH

SEX

Neutered Male

AGE

1 year

WEIGHT

9 lbs.

INTERPRETED BY

R. McKenzie Daniel,
DVM, DABVP
(Canine and Feline)

IMAGING PERFORMED BY

Dr. Gromalak

HOSPITAL NAME

SVS Imaging

REFERRING VET

Dr. Preiser

INVOICE

12380

DATE

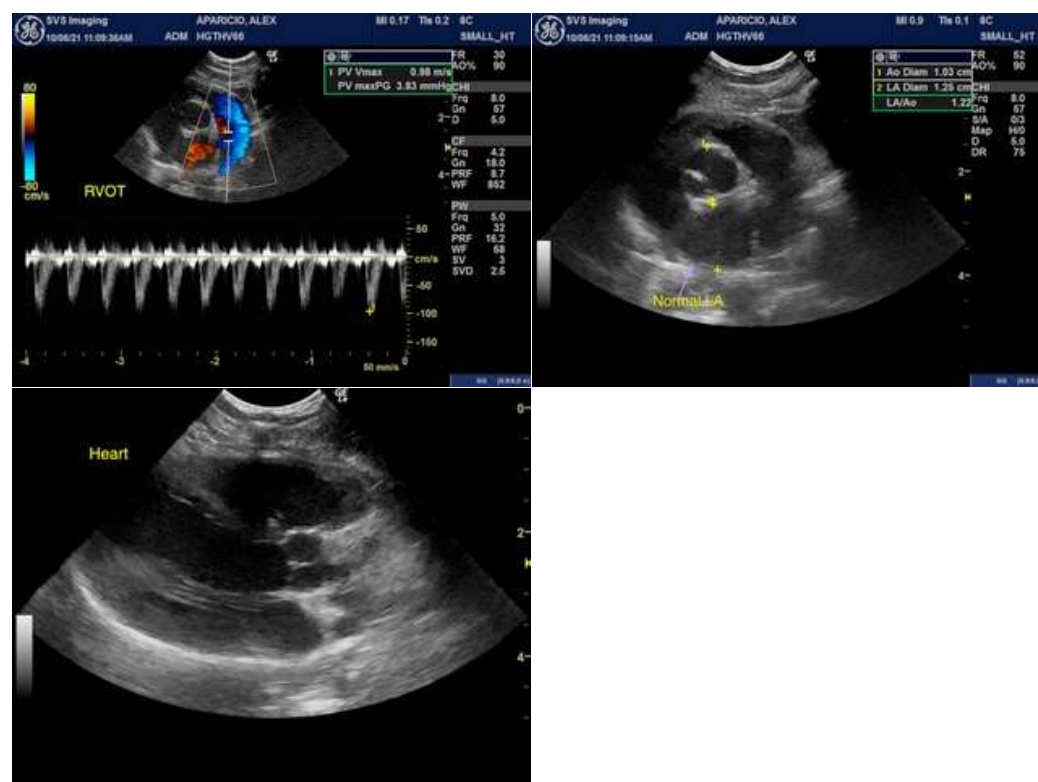
10/6/21

INTERPRETATION OF THE FINDINGS & FURTHER RECOMMENDATIONS

An obvious cause of the murmur without evidence of systolic dysfunction, valvular insufficiencies, or evidence of clinical pulmonary hypertension, was not definitively evident. Potential for a physiologic flow murmur or potential small flow abnormality not seen here cannot be definitively excluded.

Regardless, the lack of left or right heart chamber enlargement, specifically left atrium enlargement, indicate that the risk of future complication is low.

These findings also suggest that the coughing episodes in this patient are noncardiogenic in origin. Primary lower airway disease may be considered. No indication for cardiac medications. Conservative monitoring of the murmur is recommended. Recheck echocardiogram is suggested in 6 months, sooner if murmur intensity increases.



The information and recommendations provided are based on the images presented by the referring veterinarian. No evaluation can be communicated regarding pathology that was not visible in the image/video clips provided.

Thank you for this referral. If the clinical or image interpretation does not parallel your findings or if I can be of any further assistance please contact me.



PATIENT

Alex Apariacio

R. McKenzie Daniel, DVM, DABVP (Canine / Feline Practice)
info@SonoPath.com

SPECIES

Feline

BREED

DSH

SEX

Neutered Male

AGE

1 year

WEIGHT

9 lbs.

INTERPRETED BY

R. McKenzie Daniel,
DVM, DABVP
(Canine and Feline)

**IMAGING
PERFORMED BY**

Dr. Gromalak

HOSPITAL NAME

SVS Imaging

REFERRING VET

Dr. Preiser

INVOICE

12380

DATE

10/6/21