



PATIENT PRESENTING CLINICAL SIGNS

Toby Krueger

Loud on the left lateral thorax. Very muffled on the right lateral thorax Radiographic Findings R lateral thorax, VD thorax, R lateral abdomen, VD abdomen: The radiographs show a density on the right side of the cardiac shadow. What is this. I would suspect some small masses at the base of the heart. An anterior abdominal mass is possible.

SPECIES

Canine

BREED

Springer Spaniel X

SEX

Neutered Male

AGE

10 Years

WEIGHT

72.4

INTERPRETED BY

R. McKenzie Daniel,
DVM, DABVP
(Canine and Feline)

ULTRASONOGRAPHIC EXAMINATION OF THE HEART & ABDOMEN

CANINE CARDIAC PARAMETERS	MR VMAX (m/s)	TR VMAX (m/s)	LA/AO (Boon method)	LA/AO (Heart Base; Swe)	FS (%)	EF (%)	EPSS (cm)
NORMAL PARAMETER	4.5-5.5	<2.7	1.3	<1.6	28-40	40-100	<0.6
PATIENT			1.5	NM	23.9	52	0.47
CANINE CARDIAC PARAMETERS	HR (BPM)	AV VMAX (m/s)	PV MAX (m/s)	BODY WEIGHT (kg)	LA 2D short axis Base view (cm)	LVIDd Avg; 2D and m-mode short axis (cm)	LVIDs Avg; 2D and m-mode short axis (cm)
NORMAL PARAMETER	50-100	0.7-1.7	0.7-1.6				
PATIENT	NM	NM	NM		3.7	3.77	

Cardiac Presentation

The echocardiogram in this patient demonstrated normal **left atrial** size based on 3 separate methods of LA evaluation. The cranial and caudal **mitral** valve leaflets presented normal linear structure, extension in systole, and union in diastole with normal kinesis. The **left ventricle** presented thicknesses with linear contour and was not dilated nor restricted. The **myocardium** presented normal echogenicity without subjective evidence of significant fibrotic or ischemic disease. **Contractility** of the ventricular walls was mildly subnormal secondary to sedation as evidenced by the fractional shortening measurement and subjective evaluation of the different regions of the myocardium. The **left ventricular outflow** tract demonstrated normal laminar flow and subjective structural integrity. The **right atrium** and auricle revealed normal size, structure and content. No evidence of masses was noted. **Tricuspid** valvular assessment demonstrated adequate linear morphology and kinesis. The **right ventricle** was of normal size (1/3 diameter of LV), chordae structure, myocardial echogenicity and thickness. **Pulmonary outflow** tract assessment revealed normal valve structure, laminar flow, and diameter (approx.1:1 pa/ao ratio). No visible **pericardial** or free pleura fluid was noted. The cranial **mediastinum and pericardial and extra-cardiac regions** were free of masses in the visible window.

Urinary System

The urinary bladder, trigone, cystourethral junction, and visible pelvic urethra to a depth of 3.0 cm exhibited normal thickness and tone. Anechoic urine was present in the lumen with no uroliths or sediment. The ureteral papillae were normal. The ureters were not visible which is normal. No evidence of inflammatory or neoplastic changes were noted.

INVOICE

26053

DATE

10/5/21

IMAGING PERFORMED BY

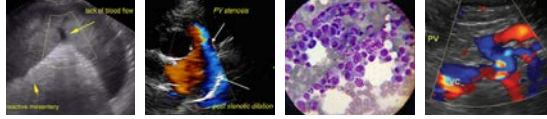
Jenna Walsh, CVT

HOSPITAL NAME

Alpine Animal Hospital

REFERRING VET

Dr. Hixson



PATIENT

Toby Krueger

The residual prostate was symmetrically normal in size with uniform parenchyma and slight coarse echotexture. The prostate measured 0.98 cm in width.

SPECIES

Canine

Normal size and margination were present in the kidneys. A normal 1:3 cortex / medulla ratio was maintained. The medulla and cortices were uniform in texture with some increased echogenicity and loss of corticomedullary symmetry and definition expected for the age of the patient. No evidence of pelvic dilation was present. The left kidney measured 6.2 cm. The right kidney measured 6.6 cm.

BREED

Springer Spaniel X

The area of the aortic trifurcation was free of pathology.

SEX

Neutered Male

Adrenal Glands

The adrenal glands were uniform in size and contour with a uniformly hypoechoic parenchyma. The right adrenal gland measured 0.40 cm at the caudal pole. The left adrenal gland measured 0.51 cm at the cranial pole and 0.54 cm at the caudal pole.

AGE

10 Years

Spleen

The spleen exhibited a finely textured and homogenous parenchyma which was hyperechoic to the liver and renal cortical parenchyma. The capsule was smooth and regular without apparent expansion. The splenic vasculature at the hilus was normal in volume with no evidence of congestion or thrombosis. Acute to chronic inflammatory, neoplastic, or benign parenchyma changes were not noted.

WEIGHT

72.4

Liver

The liver was subjectively normal in size, structure, and contour. The liver parenchyma was uniform and hypoechoic to the spleen with a mild coarse echotexture. The hepatic and portal vasculature were normal in appearance without signs of congestion. The gallbladder was non-distended in size with thin walls and primarily anechoic luminal content. The cystic and common bile ducts were normal.

INTERPRETED BY

R. McKenzie Daniel,
DVM, DABVP
(Canine and Feline)

Gastrointestinal

The stomach presented intact wall layering with a normal wall layer ratio. The lumen of the stomach contained mild echogenic, nonshadowing ingesta most consistent with post prandial presentation without signs of ileus, obstruction or foreign material.

**IMAGING
PERFORMED BY**

Jenna Walsh, CVT

The small intestine presented intact wall layering with 1:3 muscularis/mucosa ratio. The lumen of the small intestine was empty with no signs of ileus, obstruction or foreign material.

HOSPITAL NAME

Alpine Animal Hospital

Normal visible colon wall layers were present with apparent formed feces in lumen.

REFERRING VET

Dr. Hixson

Pancreas

The parenchyma of the left limb, body and right limb of the pancreas presented isoechoic to the adjacent omental fat. A normal curvilinear capsule contour of the pancreas was present. The visible pancreatic duct was normal. No signs of active inflammation or neoplastic disease was evident.

INVOICE

26053

Free Abdomen

No omental masses, lymphadenopathy, or peritoneal effusion.

DATE

10/5/21



PATIENT

Toby Krueger

SPECIES

Canine

BREED

Springer Spaniel X

SEX

Neutered Male

AGE

10 Years

WEIGHT

72.4

INTERPRETED BY

R. McKenzie Daniel,
DVM, DABVP
(Canine and Feline)

IMAGING PERFORMED BY

Jenna Walsh, CVT

HOSPITAL NAME

Alpine Animal Hospital

REFERRING VET

Dr. Hixson

INVOICE

26053

DATE

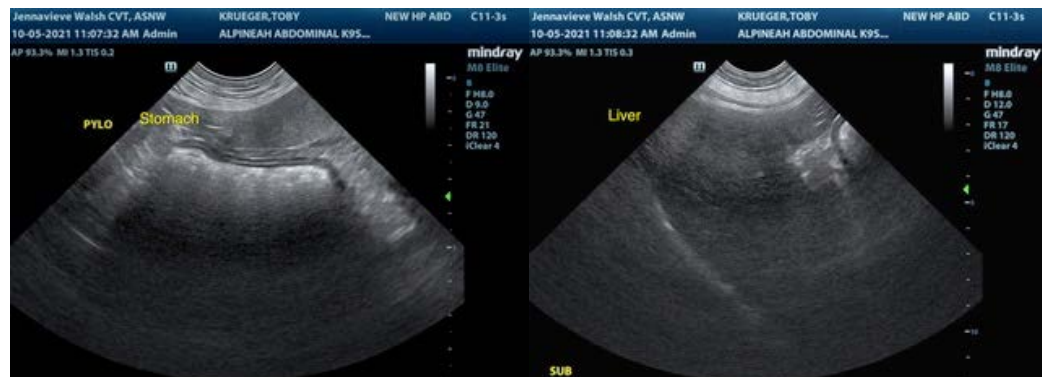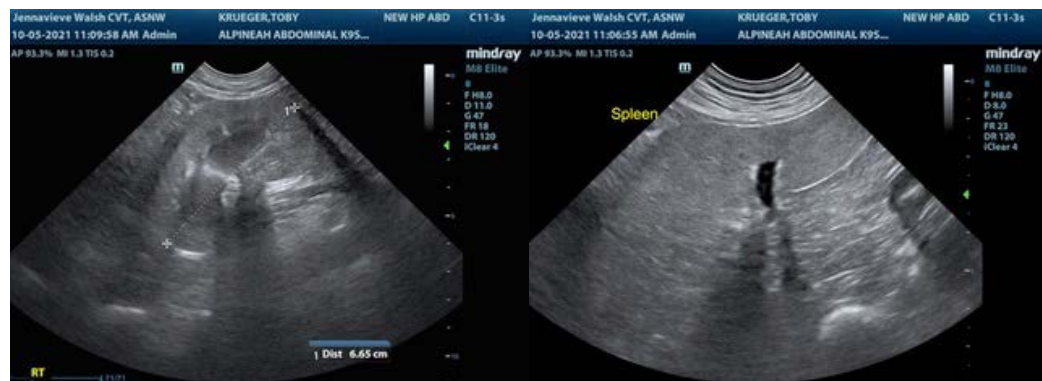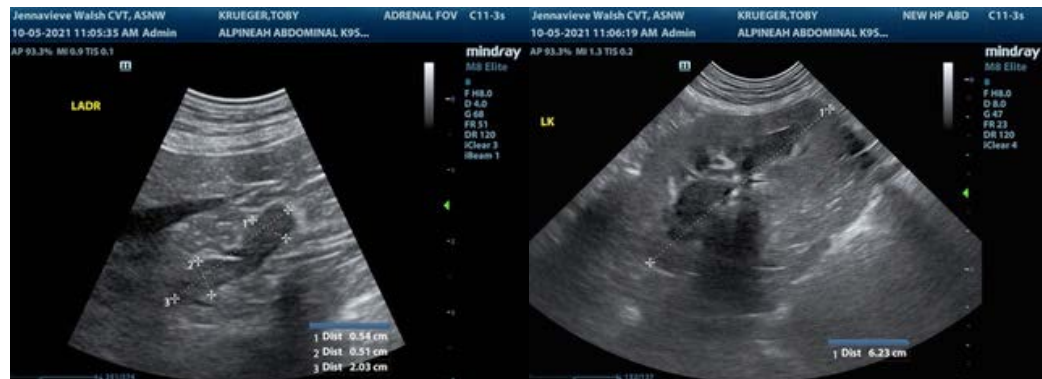10/5/21

ULTRASONOGRAPHIC FINDINGS

- Structurally normal abdomen
- Normal echocardiogram in light of sedation

INTERPRETATION OF THE FINDINGS & FURTHER RECOMMENDATIONS

Minor geriatric abdomen without evidence of significant abdominal visceral pathology including no evidence of anterior peritoneal cavity masses. Overtly normal cardiac structure and function in light of sedation. No evidence of pericardial/heart base masses as well as no overt evidence of pulmonary or thoracic pathology.





PATIENT

Toby Krueger

SPECIES

Canine

BREED

Springer Spaniel X

SEX

Neutered Male

AGE

10 Years

WEIGHT

72.4

INTERPRETED BY

R. McKenzie Daniel,
DVM, DABVP
(Canine and Feline)

IMAGING PERFORMED BY

Jenna Walsh, CVT

HOSPITAL NAME

Alpine Animal Hospital

REFERRING VET

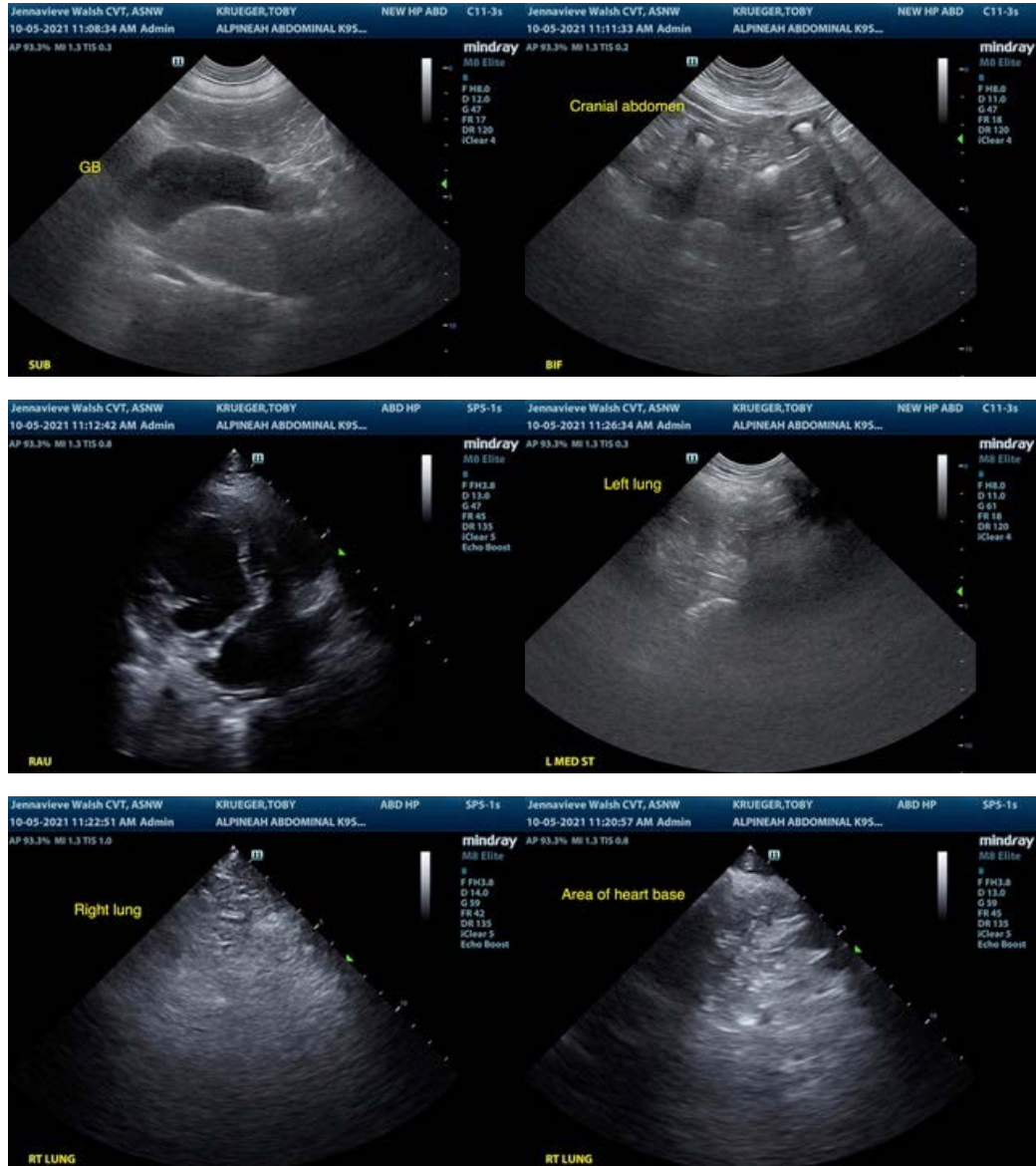
Dr. Hixson

INVOICE

26053

DATE

10/5/21



The information and recommendations provided are based on the images presented by the referring veterinarian. No evaluation can be communicated regarding pathology that was not visible in the image/video clips provided.

Thank you for this referral. If the clinical or image interpretation does not parallel your findings or if I can be of any further assistance please contact me.

R. McKenzie Daniel, DVM, DABVP (Canine / Feline Practice)
info@SonoPath.com