



PATIENT

Pascal Warren

SPECIES

Canine

BREED

Catahoula Leopard
Dog Mix

SEX

FS

AGE

8 years

WEIGHT

63 lbs.

INTERPRETED BY

R. McKenzie Daniel,
DVM, DABVP
(Canine and Feline)

IMAGING PERFORMED BY

Shari Reffi, CVT

HOSPITAL NAME

Newton Vet

REFERRING VET

Dr. Kim

INVOICE

15054

DATE

10/4/22

PRESENTING CLINICAL SIGNS

Grade I/VI on and off again heart murmur. No clinical signs. No current meds.

Abnormal PE/Chem/CBC/UA Results: 5/2022-ALP 237 (140H); Glob 4 (3.6 H); Cholesterol >450

ULTRASONOGRAPHIC EXAMINATION OF THE HEART

CANINE	MR	TR	LA/AO	LA/AO	FS	EF	EPSS
CARDIAC PARAMETERS	VMAX (m/s)	VMAX (m/s)	(Boon method)	(Heart Base; Swe)	(%)	(%)	(cm)
NORMAL PARAMETER	4.5-5.5	<2.7	1.3	<1.3	28-40	40-100	<0.6
PATIENT	4.5			1.43	20	45.7	0.54
CANINE	HR (BPM)	AV VMAX (m/s)	PV MAX (m/s)	BODY WEIGHT (kg)	LA 2D short axis Base view (cm)	LVIDd Avg; 2D and m-mode short axis (cm)	LVIDs Avg; 2D and m-mode short axis (cm)
CARDIAC PARAMETERS							
NORMAL PARAMETER	50-100	0.7-1.7	0.7-1.6				
PATIENT	156	1.0	0.7		4.4	4.7	

Cardiac Presentation

The echocardiogram in this patient demonstrated borderline to minor increased **left atrial** size based on 2 different LA measurement methods. The cranial and caudal **mitral** valve leaflets presented normal linear structure, extension in systole, and union in diastole without evidence of significant dystrophic or vegetative changes. Mild centralized MR was present on doppler. The **left ventricle** demonstrated borderline to mild increased volume (LVIDd measurement above). Ventricular function was subnormal expressed by the fractional shortening measurement. The myocardium presented normal echogenicity without evidence of fibrotic or ischemic disease. The **left ventricular outflow** tract demonstrated normal laminar flow and subjective structural integrity. The **right atrium** and auricle revealed normal size, structure and content. No evidence of masses was noted or chamber overload. **Tricuspid** valvular assessment demonstrated adequate linear morphology. The **right ventricle** was of normal size (1/3 diameter of LV), chordae structure, myocardial echogenicity and thickness. **Pulmonic** tract assessment revealed normal valve structure, laminar flow, and diameter (approx. 1:1 pa/ao ratio). No visible **pericardial** or free pleura fluid was noted. The cranial **mediastinum and pericardial regions** were free of masses in the visible window.

ULTRASONOGRAPHIC FINDINGS

- Centralized mild MR
- Borderline to mild LA/LV enlargement
- LV hypocontractility



PATIENT

Pascal Warren

SPECIES

Canine

BREED

Catahoula Leopard
Dog Mix

SEX

FS

AGE

8 years

WEIGHT

63 lbs.

INTERPRETED BY

R. McKenzie Daniel,
DVM, DABVP
(Canine and Feline)

IMAGING PERFORMED BY

Shari Reffi, CVT

HOSPITAL NAME

Newton Vet

REFERRING VET

Dr. Kim

INVOICE

15054

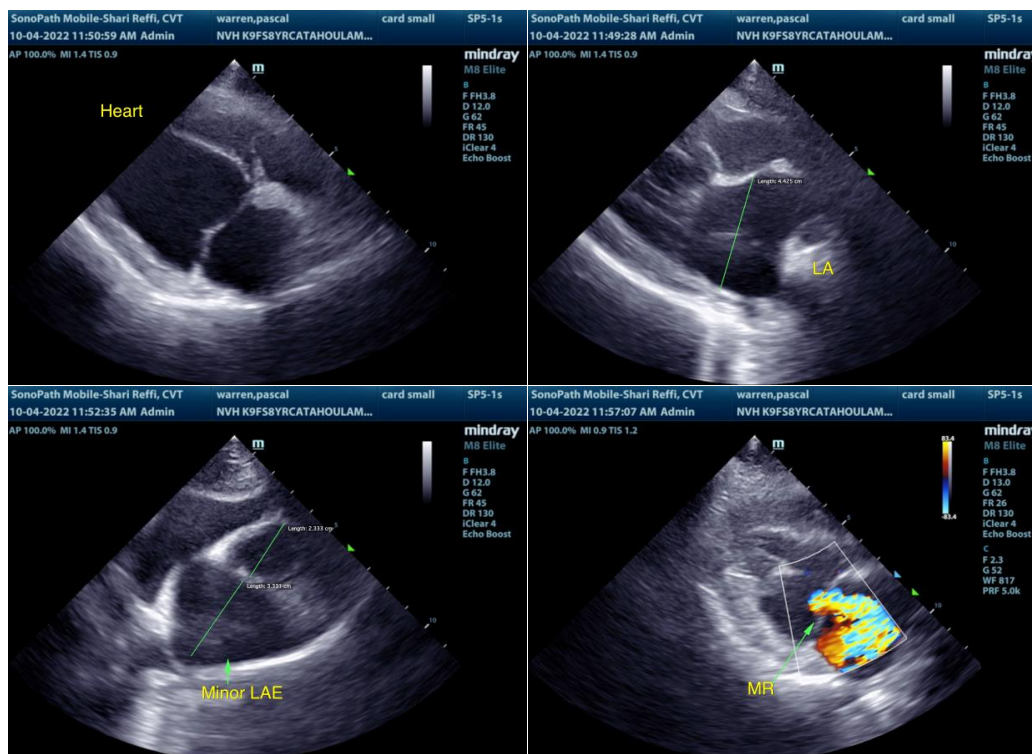
DATE

10/4/22

INTERPRETATION OF THE FINDINGS & FURTHER RECOMMENDATIONS

The LV hypocontractility in this patient is nonspecific with possible considerations including athletic state, hypothyroidism, and systemic disease as potential contributing factors. Possible emerging DCM-like criteria is possible and cannot be excluded. A dietary history is suggested to assess for potential grain-free boutique or exotic diets. Myocarditis or infectious disease may be considered less likely unless clinical history suggests higher potential.

In a nonclinical patient with only borderline to mild LA/LV enlargement, cardiac medications are not overtly indicated. However, serial sonographic monitoring is recommended for further assessment. Alternatively, Pimobendan trial at 0.3 mg/kg PO BID could be considered if clinical signs suggestive of LV hypo-functionality such as exercise intolerance, etc., are present. Recheck echocardiogram is recommended in 4-6 months, sooner if definitive clinical signs arise.



The information and recommendations provided are based on the images presented by the referring veterinarian/sonographer. No evaluation can be communicated regarding pathology that was not visible in the image/video clips provided.

Thank you for this referral. If the clinical or image interpretation does not parallel your findings or if I can be of any further assistance please contact me.

R. McKenzie Daniel, DVM, DABVP (Canine / Feline Practice)
info@SonoPath.com