



<b>PATIENT</b>	<b>PRESENTING CLINICAL SIGNS</b>
Stewie Wannan	ascites Abnormal PE/Chem/CBC/UA Results: Alb 1.6, glob 1.9, HCT 59.6
<b>SPECIES</b>	<b>ULTRASONOGRAPHIC EXAMINATION OF THE ABDOMEN</b>
Canine	<i>Urinary System</i>
<b>BREED</b>	The urinary bladder, trigone, cystourethral junction, and visible pelvic urethra exhibited normal thickness and tone. Primarily anechoic urine was present in the lumen. Mild nondependent particulate sediment was present without evidence of calculus formation. The ureteral papillae were normal. The ureters were not visible which is normal. No evidence of inflammatory or neoplastic mural changes were noted.
Mix	
<b>SEX</b>	No evidence of pathology in the area of the residual prostate.
MN	No evidence of pathology in the area of the aortic trifurcation.
<b>AGE</b>	Normal size and margination was present in the kidneys. A normal 1:3 cortex / medulla ratio and normal corticomedullary definition were maintained. The echogenicity of the cortex was similar to or slightly less than normal liver parenchyma while the medulla echogenicity was hypoechoic to the cortex with no evidence of pelvic dilation. The left kidney measured 4.0 cm in length. The right kidney measured 4.1 cm in length.
19 Months	
<b>WEIGHT</b>	<i>Adrenal Glands</i>
16.7 lbs	The left adrenal gland was uniform in size and contour with a uniformly hypoechoic parenchyma. The left adrenal gland measured 1.9 cm length x 0.42 cm width at the caudal pole.
<b>INTERPRETED BY</b>	No overt pathology in the area of the right adrenal gland. Although not definitively visualized owing to peritoneal free fluid and regional omental artifact.
R. McKenzie Daniel, DVM, DABVP (Canine and Feline)	<i>Spleen</i>
<b>IMAGING PERFORMED BY</b>	The spleen exhibited a finely textured and homogenous parenchyma which was hyperechoic to the liver and renal cortical parenchyma. The capsule was smooth and regular without apparent expansion. The splenic vasculature at the hilus was normal in volume with no evidence of congestion or thrombosis. Acute to chronic inflammatory, neoplastic, or benign parenchyma changes were not noted.
Jessica Miller	
<b>HOSPITAL NAME</b>	<i>Liver / Gallbladder</i>
Newton Veterinary Hospital	The liver was subjectively normal in size, structure, and contour. The liver parenchyma was uniform and hypoechoic to the spleen with a mild coarse echotexture. The hepatic and portal vasculature were normal in appearance without signs of congestion. The gallbladder was non-distended in size with thin walls and primarily anechoic luminal content. The cystic and common bile ducts were normal.
<b>REFERRING VET</b>	<i>Gastrointestinal</i>
Dr. Barron	The stomach presented intact wall layering with a normal wall layer ratio. Mild retained echogenic, non-shadowing ingesta was present primarily in the antrum and pylorus without signs of obstruction or foreign material. The gastric body wall measured 0.33 cm width.
<b>INVOICE</b>	Generalized increased intestinal mucosa echogenicity with diffuse mucosa speckling to echogenic mucosal striations were present. Intestinal wall layering was maintained with mild altered 1:3 muscularis / mucosa ratio. There was no evidence of an obstructive pattern or foreign material. The appearance of the small intestine is most consistent with protein losing enteropathy or
47640	
<b>DATE</b>	
10-4-21	



<b>PATIENT</b>	lymphangiectasia. There was no evidence of infiltrative or neoplastic intestinal disease which is considered unlikely but cannot be ruled out without full thickness or endoscopic biopsies.
Stewie Wannan	Normal visible colon wall layers were present with apparent formed feces in lumen.
<b>SPECIES</b>	<b><i>Pancreas</i></b>
Canine	The parenchyma of the left limb, body and right limb of the pancreas presented isoechoic to the adjacent omental fat. A normal curvilinear capsule contour of the pancreas was present. The visible pancreatic duct was normal. No signs of active inflammation or neoplastic disease was evident.
<b>BREED</b>	<b><i>Free Abdomen</i></b>
Mix	Moderate subjectively mildly cellular peritoneal free fluid was present.
<b>SEX</b>	Intermittent, mid abdominal mildly prominent to enlarged mesenteric lymph nodes were present. The lymph nodes were essentially isoechoic to adjacent omentum without evidence of peripheral inflammation and maintaining a normal width: length ratio (<0.5). An example of a mesenteric lymph node measured 3.0 cm length x 0.85 cm width.
MN	
<b>AGE</b>	Generalized echogenic mesentery was present.
19 Months	No evidence of omental masses.
<b>WEIGHT</b>	Rapid view of the heart revealed no evidence of right cardiomegaly. Suspect concurrent pleural free fluid.
16.7 lbs	
<b>INTERPRETED BY</b>	<b>ULTRASONOGRAPHIC FINDINGS</b>
R. McKenzie Daniel, DVM, DABVP (Canine and Feline)	<ul style="list-style-type: none"> <li>• Moderate subjectively mildly cellular peritoneal free fluid and generalized reactive mesentery.</li> <li>• Generalized small bowel mucosal fogging.</li> <li>• Mild mid abdominal mesenteric lymphadenopathy - lymphoid hyperplasia or mild reactive lymphadenitis probable.</li> <li>• Sonographically unremarkable liver and bilateral kidneys.</li> </ul>
<b>IMAGING PERFORMED BY</b>	<b>INTERPRETATION OF THE FINDINGS &amp; FURTHER RECOMMENDATIONS</b>
Jessica Miller	The free fluid may indicate non-septic (increased vascular permeability, decreased hydrostatic pressure) or septic effusion. Further assessment including effusion analysis, cytology +/- C/S if evidence of inflammatory cells is recommended.
<b>HOSPITAL NAME</b>	Given the panhypoproteinemia in combination with the sonographic presentation of the small bowel as well as in light of lack of hepatic congestion or right cardiomyopathy, protein losing enteropathy is considered a primary differential diagnosis in this case assuming no evidence of proteinuria. If clinically indicated, intestinal biopsies would likely be ideal yet may be contraindicated at this time given the albumin levels less than 2.0. Pending effusion analysis and urinalysis, empirical PLE therapy may be considered. Three view chest radiographs recommended if not done.
Newton Veterinary Hospital	
<b>REFERRING VET</b>	
Dr. Barron	
<b>INVOICE</b>	<b>PLE Therapy</b>
47640	Part or all of this protocol may be considered based on your clinical impression of the patient: <b>OBJECTIVE: keep albumin levels &gt; 2 g/dl, avoid thromboembolism and cavitory effusions, monitor concurrent PLN (Wheaton Terrier PLE/PLN) and liver disease:</b>
<b>DATE</b>	<b>Plasma</b> 10 mL / kilogram IV over 4 hours Or <b>Human albumin</b> 2 ml/kg/h over 10 hours. Total daily volume 20.l/kg/day <b>And Colloids/Hetastarch</b>
10-4-21	



**PATIENT**

Stewie Wannan

10 to 20 mL per kilogram per day and dogs  
10 to 15 mL per kilogram per day cats  
(Can bolus first 1/3 of dose over 15 minutes)  
& maintain on LRS maintenance otherwise.

**SPECIES**

Canine

**Metronidazole** (10-20 mg/kg po bid)

**Famotidine** 1 mg/kg Iv Im po dc Sid /bid

**Sucralfate** 0.5-1 g po tid dogs, 0.5 g bid cats in slurry **Or Misoprostol** 1-5 ug/kg po tid

**Diet:** Highly digestible high quality protein, low fiber, low fat diet (< 15% of dry matter). Hydrolyzed protein or novel protein. Purina HA or Royal Canine HP or similar.

**BREED**

Mix

**Prednisone** or prednisolone 2 mg/kg bid x 3-5 days then 2 mg/kg sid. **Chlorambucil** in refractive severe IBD/alimentary lymphoma cases (monitor cbc for rare bone marrow suppression) 4 mg/m<sup>2</sup> Q 24-48 hours.

**Cobalamine** (B12) 250-1500 ug/dog weekly x 6 weeks.

**Calcium** supplementation if necessary.

**SEX**

**Aspirin** 0.5-1 mg/kg/day or **Clopidrel** (Plavix) 1-5 mg/kg/day.

MN

**AGE**

19 Months

**WEIGHT**

16.7 lbs

**INTERPRETED BY**

R. McKenzie Daniel,  
DVM, DABVP  
(Canine and Feline)

**IMAGING PERFORMED BY**

Jessica Miller

**HOSPITAL NAME**

Newton Veterinary  
Hospital

**REFERRING VET**

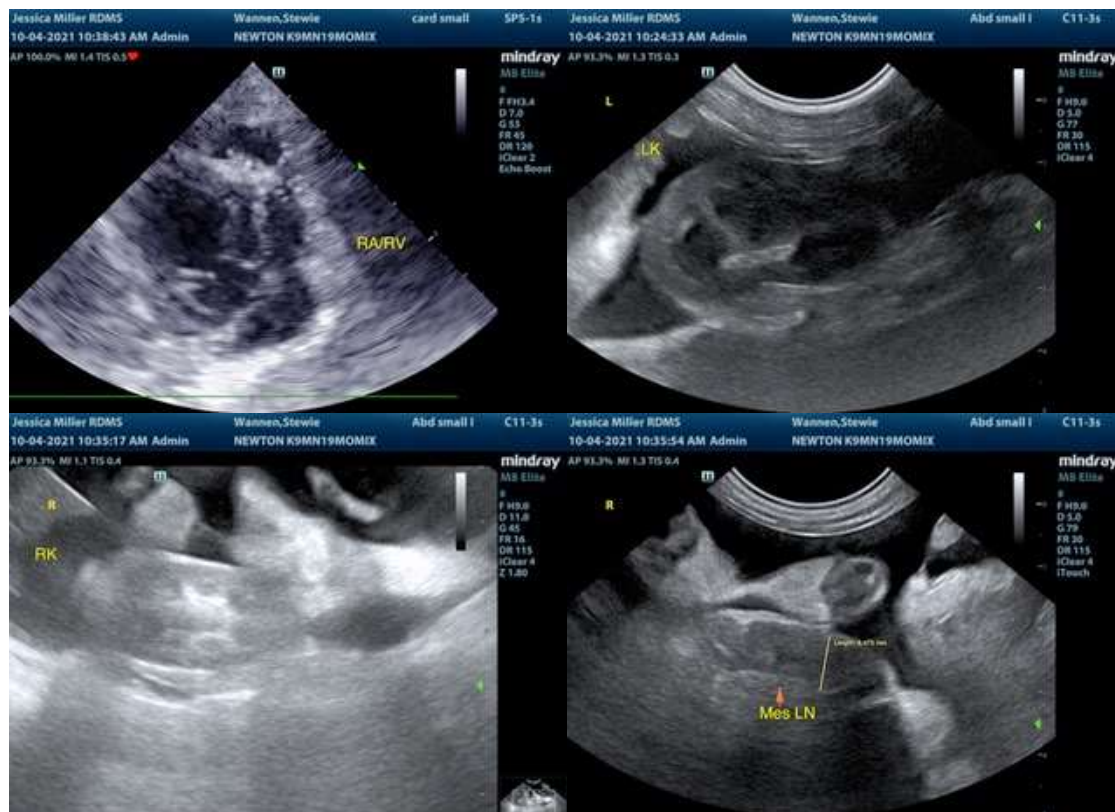
Dr. Barron

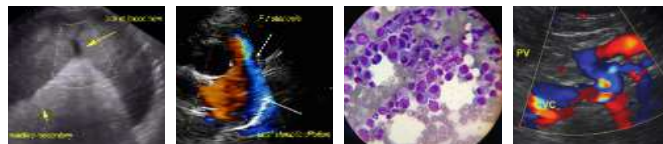
**INVOICE**

47640

**DATE**

10-4-21





**PATIENT**

Stewie Wannan

**SPECIES**

Canine

**BREED**

Mix

**SEX**

MN

**AGE**

19 Months

**WEIGHT**

16.7 lbs

**INTERPRETED BY**

R. McKenzie Daniel,  
DVM, DABVP  
(Canine and Feline)

**IMAGING PERFORMED BY**

Jessica Miller

**HOSPITAL NAME**

Newton Veterinary  
Hospital

**REFERRING VET**

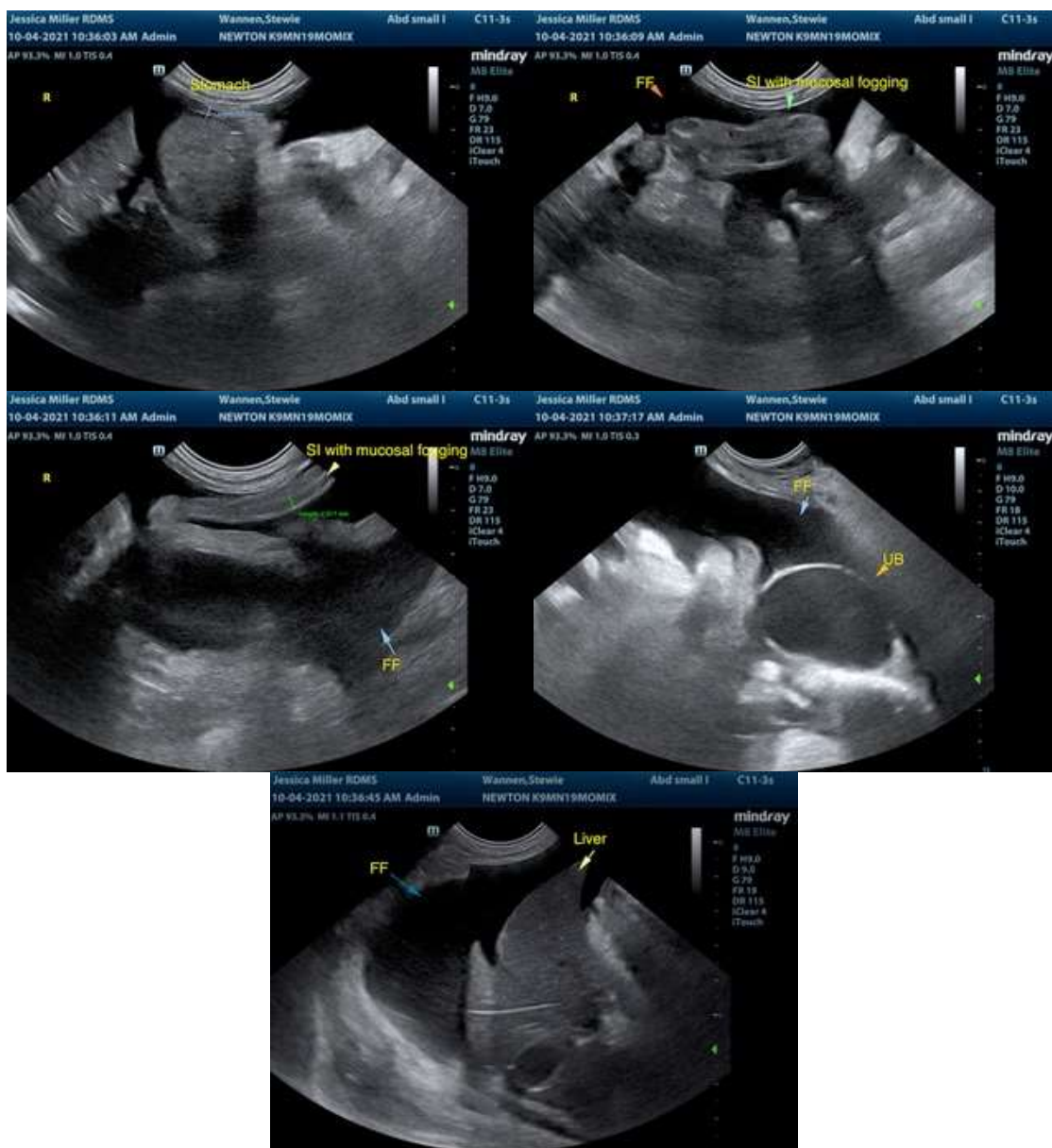
Dr. Barron

**INVOICE**

47640

**DATE**

10-4-21



The information and recommendations provided are based on the images presented by the referring veterinarian. No evaluation can be communicated regarding pathology that was not visible in the image/video clips provided.

Thank you for this referral. If the clinical or image interpretation does not parallel your findings or if I can be of any further assistance please contact me.

R. McKenzie Daniel, DVM, DABVP (Canine / Feline Practice)  
info@SonoPath.com