



PATIENT PRESENTING CLINICAL SIGNS

PATIENT Peanut Tasovac
SPECIES Canine
 Repeatable elevated Ca on fasting sample. Aug 13, 2022 Phos 3.8 Ca 11.7 - Fasted. June 16, 2022 Phos 3.6 Ca 11.6. On June 16, 2022 - Grade II-III/VI murmur heard - not previously noted. Since Ca remains elevated on fasted sample, would like abdominal US at time of echo for newly dx heart murmur. *Sedated with Butorphanol, Midazolam and Propofol.

ULTRASONOGRAPHIC EXAMINATION OF THE ABDOMEN

BREED *Urinary System*

BREED Bichon Frise
 The urinary bladder, trigone, cystourethral junction, and visible pelvic urethra to a depth of 2 cm exhibited normal thickness and tone. Anechoic urine was present in the lumen with mild non-dependent particulate sediment. The sediment may indicate cellular debris / protein, crystalline debris, lipid, or mucus. The ureteral papillae were normal. The ureters were not visible which is normal. No evidence of inflammatory or neoplastic changes were noted.

SEX

MN

AGE

8.5yr

Normal size and margination were present in the kidneys. A normal 1:3 cortex / medulla ratio and normal corticomedullary definition were maintained. The echogenicity of the cortex was similar to or slightly less than normal liver parenchyma while the medulla echogenicity was hypoechoic to the cortex with no evidence of pelvic dilation. Pinpoint areas of medullary mineral were noted. The left kidney measured 4.2 cm in length. The right kidney measured 4.4 cm in length.

WEIGHT

16.18lb

The area of the aortic trifurcation was free of pathology.

The area of the iliac trifurcation was free of pathology including no evidence of medial, iliac or sublumbar lymphadenopathy.

INTERPRETED BY

R. McKenzie Daniel, DVM, DABVP (Canine and Feline)

The area of the residual prostate appeared normal and free of pathology measuring 0.72 cm in diameter.

Adrenal Glands

The left adrenal gland exhibited mild prominent caudal pole size based on width measurement considering body weight. No overt evidence of adrenomegaly or neoplastic criteria. The left adrenal gland measured 0.68 cm width at the caudal pole and 0.51 cm width at the cranial pole.

IMAGING PERFORMED BY

Pamela Harrigan, RDCS

The right adrenal gland was uniform in size and contour with a uniformly hypoechoic parenchyma. The right adrenal gland measured 0.53 cm width at the caudal pole and 0.49 cm width at the cranial pole.

HOSPITAL NAME

VCA Hanson Animal Hospital

Spleen

The spleen exhibited normal size and normal parenchymal echogenicity with mild heterogeneity. No splenic masses or nodules noted. The capsule was smooth and regular without apparent expansion. The splenic vasculature at the hilus was normal in volume with no evidence of congestion or thrombosis.

REFERRING VET

Dr. Oscar

Liver

INVOICE

12063ag

The liver was subjectively normal in size, structure, and contour. The liver parenchyma was mildly nonuniform and hypoechoic to the spleen with a mild coarse echotexture and subjective mild to benign parenchymal remodeling. No evidence of hepatic neoplasia. The hepatic and portal vasculature were normal in appearance without signs of congestion. The gallbladder was non-distended in size with thin walls and primarily anechoic luminal content. The cystic and common bile ducts were normal.

DATE

10/31/2022

Gastrointestinal



PATIENT

Peanut Tasovac

The stomach presented intact wall layering with a normal wall layer ratio. The lumen of the stomach was empty with no signs of ileus, obstruction or foreign material.

SPECIES

Canine

The small intestine presented intact wall layering with 1:3 muscularis/mucosa ratio. The lumen of the small intestine was empty with no signs of ileus, obstruction or foreign material.

Normal visible colon wall layers were present with apparent formed feces in lumen.

Pancreas

BREED

Bichon Frise

The parenchyma of the left limb, body and right limb of the pancreas presented isoechoic to the adjacent omental fat. A normal curvilinear capsule contour of the pancreas was present. The visible pancreatic duct was normal. No signs of active inflammation or neoplastic disease was evident.

SEX

MN

Free Abdomen

No omental masses, overt lymphadenopathy or peritoneal effusion was present.

AGE

8.5yr

ULTRASONOGRAPHIC FINDINGS

- Mild gallbladder debris (non-mucocele)
- Pinpoint renal medullary mineralization
- Mild urinary bladder sediment
- Minor heterogeneous spleen

WEIGHT

16.18lb

INTERPRETATION OF THE FINDINGS & FURTHER RECOMMENDATIONS

Overall, no overt evidence of significant abdominal visceral pathology i.e. neoplastic criteria as a definitive cause of the patient's clinical signs/hypercalcemia.

INTERPRETED BY

R. McKenzie Daniel, DVM,
DABVP (Canine and Feline)

A urine C/S is suggested on a urine sample if evidence of inflammatory sediment.

IMAGING PERFORMED BY

Pamela Harrigan, RDCS

The splenic presentation is likely incidental or patient variant with potential for minor hyperplasia, hematopoiesis or similar. Assuming normal clotting status and using a 25g needle, a hepatosplenic FNA for screening cytology is warranted for further assessment.

Three view chest radiographs are recommended if not done to assess for occult thoracic pathology. Rectal palpation is recommended if not done as well as a hypercalcemia panel for further assessment.

HOSPITAL NAME

VCA Hanson Animal
Hospital

REFERRING VET

Dr. Oscar

INVOICE

12063ag

DATE

10/31/2022



PATIENT

Peanut Tasovac

SPECIES

Canine

BREED

Bichon Frise

SEX

MN

AGE

8.5yr

WEIGHT

16.18lb

INTERPRETED BY

R. McKenzie Daniel, DVM,
 DABVP (Canine and Feline)

IMAGING PERFORMED BY

Pamela Harrigan, RDCS

HOSPITAL NAME

VCA Hanson Animal
 Hospital

REFERRING VET

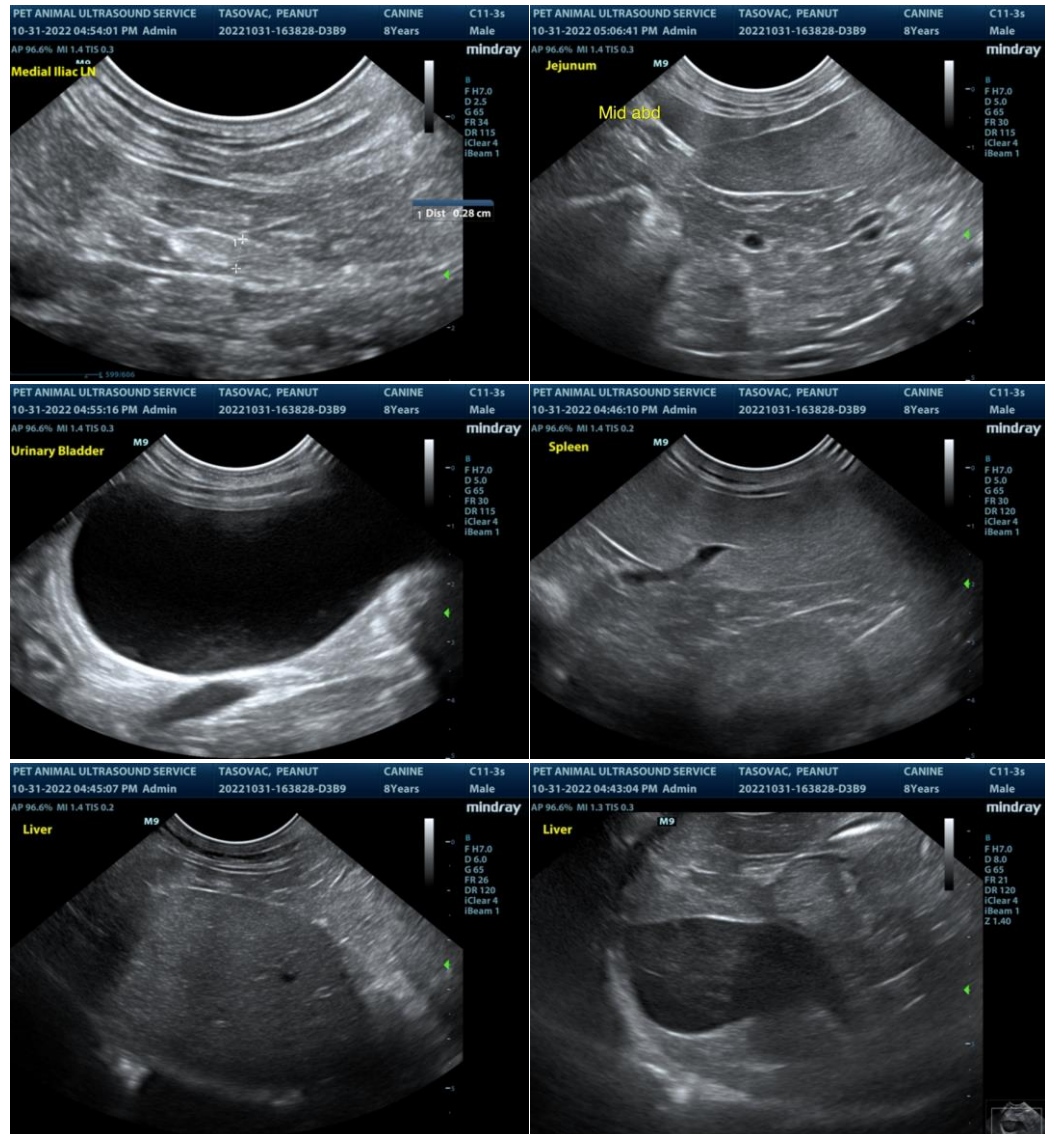
Dr. Oscar

INVOICE

12063ag

DATE

10/31/2022





PATIENT

Peanut Tasovac

SPECIES

Canine

BREED

Bichon Frise

SEX

MN

AGE

8.5yr

WEIGHT

16.18lb

INTERPRETED BY

R. McKenzie Daniel, DVM,
 DABVP (Canine and Feline)

IMAGING PERFORMED BY

Pamela Harrigan, RDCS

HOSPITAL NAME

VCA Hanson Animal
 Hospital

REFERRING VET

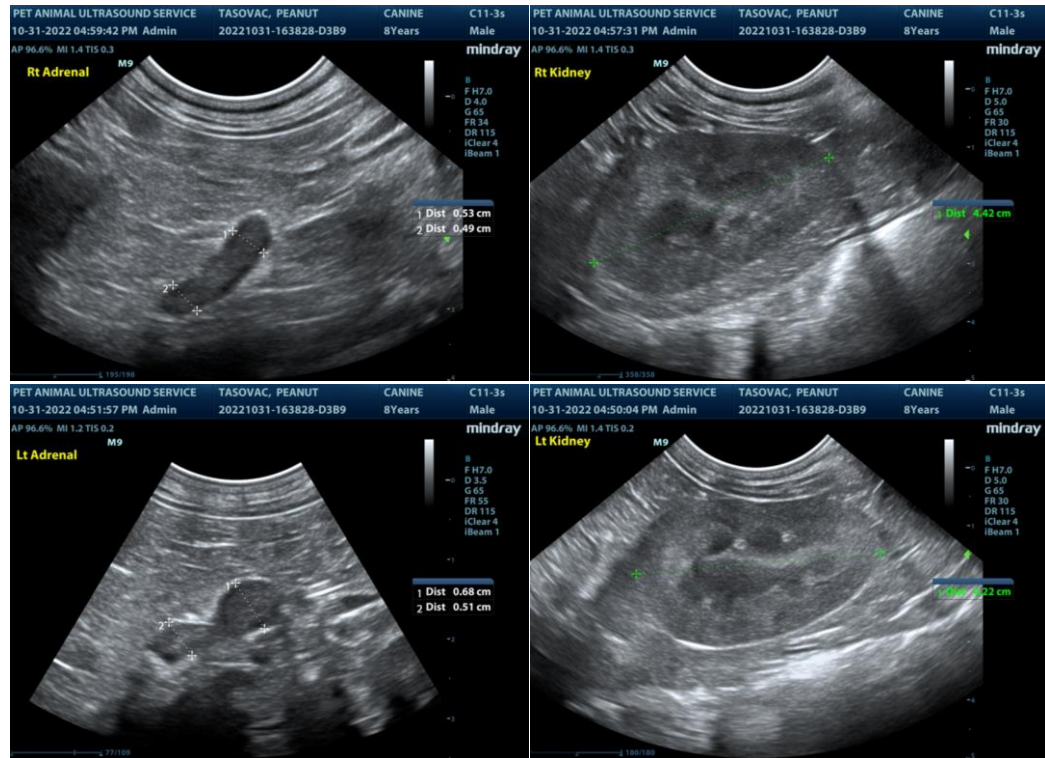
Dr. Oscar

INVOICE

12063ag

DATE

10/31/2022



The information and recommendations provided are based on the images presented by the referring veterinarian/sonographer. No evaluation can be communicated regarding pathology that was not visible in the image/video clips provided.

Thank you for this referral. If the clinical or image interpretation does not parallel your findings or if I can be of any further assistance please contact me.

R. McKenzie Daniel, DVM, DABVP (Canine / Feline Practice)

info@SonoPath.com