



PATIENT PRESENTING CLINICAL SIGNS

Maddux Wright Increased coughing fits in the last few months Grade 4/6 heart murmur noted on PE and irregular cardiac shape on rads
 Abnormal PE/Chem/CBC/UA Results: elevated BUN, PSLm SAP, ALT

SPECIES

Canine

ULTRASONOGRAPHIC EXAMINATION OF THE HEART

BREED	CANINE CARDIAC PARAMETERS	MR VMAX (m/s)	TR VMAX (m/s)	LA/AO (Boon method)	LA/AO (Heart Base; Swe)	FS (%)	EF (%)	EPSS (cm)
Shih Tzu								
SEX	NORMAL PARAMETER	4.5-5.5	<2.7	1.3	<1.6	28-40	40-100	<0.6
Neutered Male	PATIENT	5.9	1.5	NM	1.5	55	89	0.12
AGE	CANINE CARDIAC PARAMETERS	HR (BPM)	AV VMAX (m/s)	PV MAX (m/s)	BODY WEIGHT (kg)	LA 2D short axis Base view (cm)	LVIDd Avg; 2D and m-mode short axis (cm)	LVIDs Avg; 2D and m-mode short axis (cm)
14 Years								
WEIGHT	NORMAL PARAMETER	50-100	0.7-1.7	0.7-1.6				
23.8 Pounds	PATIENT	129	1.2	1.0		3.1	2.5	

INTERPRETED BY

R. McKenzie Daniel, DVM, DABVP (Canine and Feline)

IMAGING PERFORMED BY

Kim Liedberg

HOSPITAL NAME

SVS Imaging WI

REFERRING VET

Dr. Hanover

INVOICE

26719

DATE

10/28/21

Cardiac Presentation

The echocardiogram for this patient presented mildly excessive **left atrial size** expressed both in the LA/AO and LA max measurements Chamber volumes were essentially normal with normal echogenicity. The cranial and caudal **mitral** valve leaflets presented vegetative thickening consistent with endocardiosis. Doppler indicated measurable insufficiency. The **left ventricle** presented thicknesses with linear contour and was not dilated nor restricted. The **myocardium** presented normal echogenicity without subjective evidence of significant fibrotic or ischemic disease. **Contractility** of the ventricular walls was adequate and in normal range for this patient evidenced by the fractional shortening measurement and subjective evaluation of the different regions of the myocardium. The **left ventricular outflow** tract demonstrated normal laminar flow and subjective structural integrity. The **right atrium** and auricle revealed normal size, structure and content. No evidence of masses was noted or chamber overload. **Tricuspid** valvular assessment demonstrated adequate linear morphology. The **right ventricle** was of normal size (1/3 diameter of LV), chordae structure, myocardial echogenicity and thickness. **Pulmonic** tract assessment revealed normal valve structure, laminar flow, and diameter (approx. 1:1 pa/ao ratio). No visible **pericardial** or free pleura fluid was noted. No echographically detectable evidence of infiltrative disease was visible. The cranial **mediastinum and pericardial regions** were free of masses in the visible window.

ULTRASONOGRAPHIC FINDINGS

- Chronic mitral valve disease (ACVIM early B2)
- Mild tricuspid valve insufficiency – estimated pulmonary pressure gradient not consistent with clinical pulmonary hypertension.



PATIENT

Maddux Wright

SPECIES

Canine

BREED

Shih Tzu

SEX

Neutered Male

AGE

14 Years

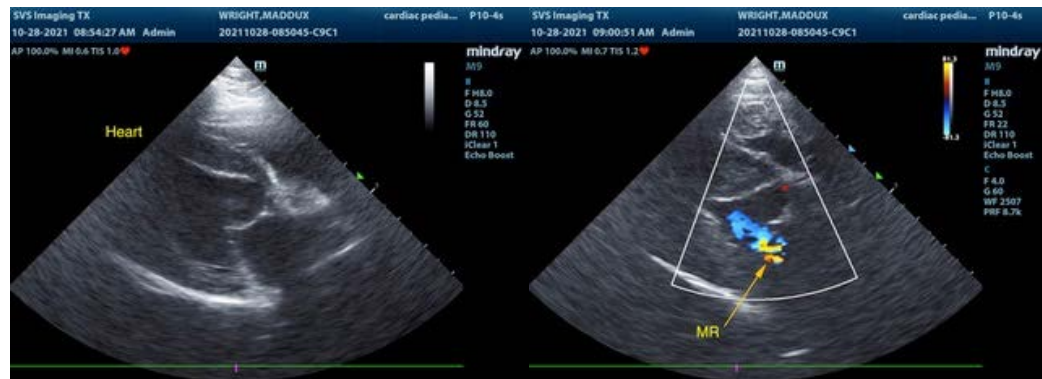
WEIGHT

23.8 Pounds

INTERPRETATION OF THE FINDINGS & FURTHER RECOMMENDATIONS

The cause of the murmur is chronic degenerative valvular changes with secondary eccentric mitral valve insufficiency. The mild left atrial enlargement indicates that the risk for future complication is mildly elevated, yet overall the heart appears to be compensated. No other clinical issues such as systolic dysfunction or evidence of clinical pulmonary hypertension were identified. Cardiogenic pulmonary edema is not anticipated, indicating that the coughing in this patient is most likely non-cardiogenic in origin. No indication for specific cardiac medications at this stage.

Assessment of systemic blood pressures suggested given the borderline elevated mitral regurgitation velocity approaching 6.0 m/sec. Recheck echocardiogram suggested in 6 months, sooner if clinical signs suggestive of heart disease (exercise intolerance, syncope, elevated resting respiration rate, etc.) are noted.



INTERPRETED BY

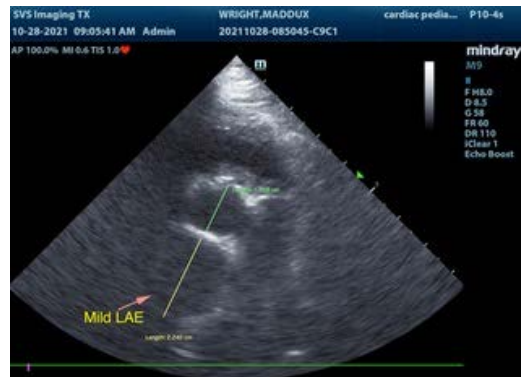
R. McKenzie Daniel,
DVM, DABVP
(Canine and Feline)

IMAGING PERFORMED BY

Kim Liedberg

HOSPITAL NAME

SVS Imaging WI



REFERRING VET

Dr. Hanover

The information and recommendations provided are based on the images presented by the referring veterinarian. No evaluation can be communicated regarding pathology that was not visible in the image/video clips provided.

INVOICE

26719

DATE

10/28/21

Thank you for this referral. If the clinical or image interpretation does not parallel your findings or if I can be of any further assistance please contact me.

R. McKenzie Daniel, DVM, DABVP (Canine / Feline Practice)
info@SonoPath.com