



PATIENT

Teddington Obispo

SPECIES

Canine

BREED

Pomeranian

SEX

Male Intact

AGE

10 years

WEIGHT

4.2 kg

INTERPRETED BY

R. McKenzie Daniel,
DVM, DABVP
(Canine and Feline)

IMAGING PERFORMED BY

Dr. Sarah Barthelemy

HOSPITAL NAME

Ranchlands Vet
Clinic

REFERRING VET

Dr. Sam

INVOICE

15301

DATE

10/27/22

PRESENTING CLINICAL SIGNS

Swelling noted in perineal region. No other clinical signs. Radiographs showed prostatomegaly. FNA externally into swelling came back only with RBC's.

The submitted study contained 6 still images and 8 videos for review.

ULTRASONOGRAPHIC EXAMINATION OF THE URINARY SYSTEM

The urinary bladder, trigone, and cystourethral junction exhibited normal thickness and tone. Anechoic urine was present in the lumen with no uroliths or sediment. The ureteral papillae were normal. The ureters were not visible which is normal. No evidence of inflammatory or neoplastic changes was noted.

The prostate was enlarged in size with intact, symmetrical capsule contour. The margins of the gland were intact and able to be differentiated from the surrounding tissue. The prostatic parenchyma was mildly echogenic to heteroechoic without parenchymal mineralization. The prostate measured 3.3 cm x 2.2 cm. Anechoic, thinly walled intraparenchymal cysts were present, with an example measuring 0.66 cm in diameter. No evidence of parenchymal mineralization was noted.

The left and right testicle were sonographically normal.

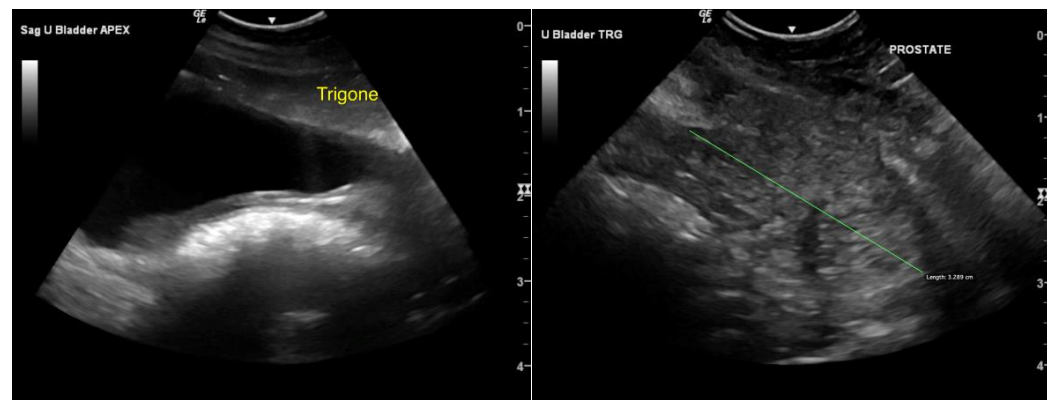
The visible colon was sonographically normal.

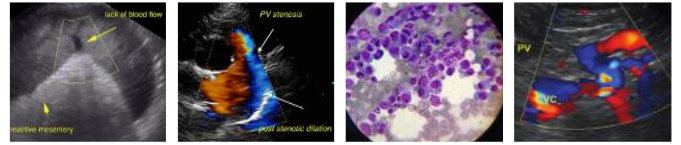
ULTRASONOGRAPHIC FINDINGS

- Sonographically normal urinary bladder
- Prostatomegaly exhibiting nonhomogeneous parenchyma including intermittent intraparenchymal cysts - suspect benign prostatic hyperplasia with parenchymal cysts, potential for prostatitis, no overt evidence of prostatic neoplastic criteria which is thought unlikely

INTERPRETATION OF THE FINDINGS & FURTHER RECOMMENDATIONS

Correlation with pending prostatic sampling +/- C/S, if evidence of inflammatory cells, is recommended. Neutering may be ideal for this patient.





PATIENT

Teddington Obispo

SPECIES

Canine

BREED

Pomeranian

SEX

Male Intact

AGE

10 years

WEIGHT

4.2 kg

INTERPRETED BY

R. McKenzie Daniel,
DVM, DABVP
(Canine and Feline)

IMAGING PERFORMED BY

Dr. Sarah Barthelemy

HOSPITAL NAME

Ranchlands Vet
Clinic

REFERRING VET

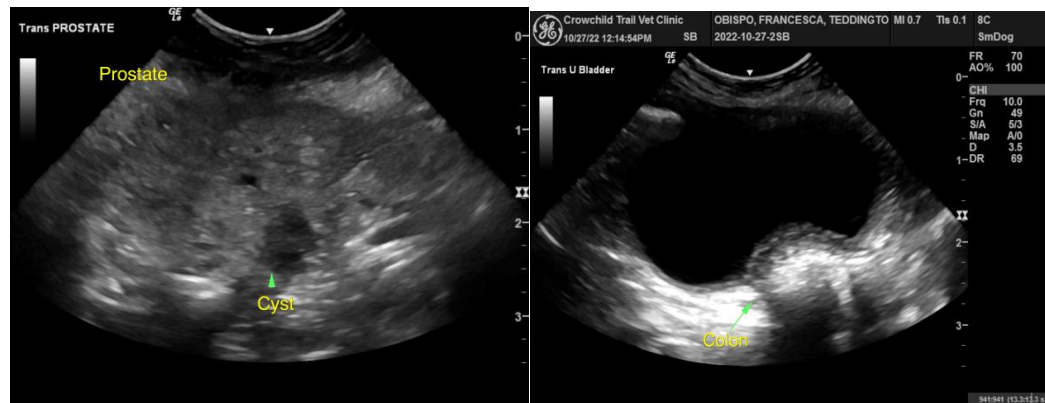
Dr. Sam

INVOICE

15301

DATE

10/27/22



The information and recommendations provided are based on the images presented by the referring veterinarian/sonographer. No evaluation can be communicated regarding pathology that was not visible in the image/video clips provided.

Thank you for this referral. If the clinical or image interpretation does not parallel your findings or if I can be of any further assistance please contact me.

R. McKenzie Daniel, DVM, DABVP (Canine / Feline Practice)
info@SonoPath.com